

A case with cerebral thrombosis receiving tamoxifen treatment

G. Akdal^a, B. Dönmez^a, H. Çakmakçı^b and G. Gülmen Yener^a

^aDepartment of Neurology and ^bRadiology, Dokuz Eylül University, School of Medicine, Izmir-Turkey

Keywords:

cerebral thrombosis,
tamoxifen

Received 16 February 2001

Accepted 11 June 2001

Cerebral sinus thrombosis (CST) is known to be related to a number of underlying aetiologies including otitis media, trauma, pregnancy, birth control pills, tumours, malnutrition, dehydration, haematologic disorders and malignancy (Fishman, 2000; Raizer and Abbott, 2000). We present the case of a patient with breast cancer receiving the antioestrogen drug tamoxifen who developed CST.

A 40-year-old female presented as an emergency with a 10-day history of headache and left sided weakness. On questioning her past medical history included a diagnosis of breast cancer 3 years ago treated by radical mastectomy and tamoxifen 20 mg daily. At the time of admission, neurologic examination revealed a mild left sided hemiparesis and a present Babinski sign. Non-contrast enhanced tomography was normal. Magnetic resonance imaging (MRI) showed thrombosis in the superior sagittal sinus, right lateral sinus and jugular vein in addition venous infarction in the right temporal lobe was present (Figs 1a and b). Routine haematology and biochemistry was normal. Anticoagulation tests, antithrombin III, protein S and C levels were also found to be normal. She was treated with anticoagulation therapy and her hemiparesis improved within 3 days. Control MRI showed the resorption of the venous infarction and resolution of the thrombosis (Fig. 1c).

Discussion

Cerebral sinus thrombosis is associated with a number of well described conditions, but in 30% of cases no underlying aetiology can be identified (Allogren and Abbott, 1975). Our patient had previously been diagnosed with breast cancer and was currently taking tamoxifen therapy. She had two known contributing factors for thrombosis; cancer and antioestrogen treatment. Systemic thrombosis is well recognised in cancer patients because of malignancy associated hypercoagulability, metastatic spread, direct tumour infiltration or as a complication of treatment, the latter two are especially seen in haematological malignancies (Raizer and DeAngelis, 2000). The aetiological factor for sinus thrombosis in our patient does not seem to be the cancer itself. Thrombosis has previously been reported of during antioestrogen therapy (Saphner *et al.*, 1991; Meier and Jick, 1998). Saphner *et al.* (1991) reported a 5.4% increased incidence of both venous and arterial thrombosis in patients who received adjuvant tamoxifen compared with patients on no tamoxifen (Saphner *et al.*, 1991). In that study, venous complications related to tamoxifen treatment included deep venous thrombosis and mesenteric vein thrombosis however, there were no causes of cerebral thrombosis. Raizer and

DeAngelis (2000) reported twenty patients with cancer who had developed CST. Three patients out of 20 were receiving antioestrogen therapy – (arimidex or tamoxifen) (Raizer and DeAngelis, 2000).

Taking into account the fact that our patient had no signs of active malignancy and previous reports of tamoxifen related thrombosis it seems highly likely that tamoxifen was the underlying cause for our patient's CST.

Physicians should be aware of this uncommon but serious side-effect of tamoxifen therapy especially with the more widespread use of tamoxifen.

References

- Allroggen H, Abbott RJ (2000). Cerebral venous sinus thrombosis. *Postgrad Med* 76:12–15.
- Fishman RA (2000). Cerebral veins and sinuses. In: Rowland LP, ed. *Merritt's Neurology*. Philadelphia Lippincott Williams Wilkins, pp. 268–274.
- Meier CR, Jick H (1998). Tamoxifen, risk of idiopathic venous thromboembolism. *Br J Clin Pharmacol* 45:608–612.
- Raizer J, DeAngelis LM (2000). Cerebral sinus thrombosis diagnosed by MRI and MR venography in cancer patients. *Neurology* 54:1222–1226.
- Saphner T, Tormey CD, Gary R (1991). Venous, arterial thrombosis in patients who received adjuvant therapy for breast cancer. *J Clin Oncol* 9:286–294.

Correspondence: Güliden Akdal MD, Department of Neurology, Dokuz Eylül University, School of Medicine, İzmir –Turkey (fax: 90 232277 77 21; e-mail: gulden.akdal@deu.edu.tr).

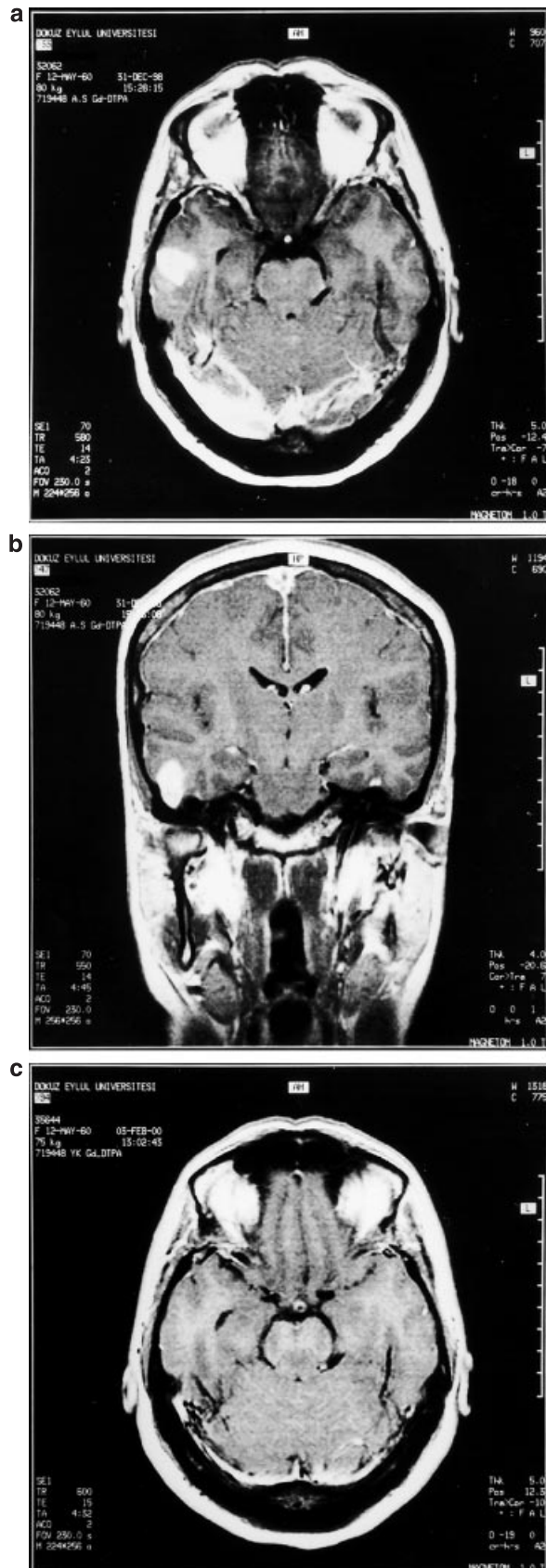


Figure 1 T1 weighted contrast enhanced axial (a) and coronal (b) images show unenhancing thrombus in superior sagittal sinus and venous hemorrhagic infarction in the right temporal lobe. Control T1 weighted contrast enhanced MRI image (c) reveals resolution of the thrombus in superior sagittal sinus.