

A Neuropsychological Outcome Study of a Child's Left Pericallosal Arteriovenous Malformation with Occult Fornix Lesion

Thomas N. Dikel^{1,2,3}, Eileen B. Fennell^{1,2}, Stephen E. Nadeau^{1,4,7}, Ronald G. Quisling^{1,5}, John P. Mickle^{1,6} and William A. Friedman^{1,6}

¹McKnight Brain Institute, University of Florida, Departments of ²Clinical and Health Psychology, ³Pediatrics, ⁴Neurology,

⁵Radiology and ⁶Neurological Surgery and ⁷Geriatric Research, Education and Clinical Center, Malcolm Randall Department of Veterans Affairs Medical Center, University of Florida, Gainesville, Florida, USA

Abstract

Pericallosal arteriovenous malformations are rarely reported, particularly in children. Moreover, few arteriovenous malformation studies report thorough neuropsychological outcome data for assessing post-surgical functioning. This case report provides a longitudinal study of a boy who initially presented for neuropsychological testing at the age of 8 years and 1 month, following polyvinyl alcohol embolization, two craniotomies and resections and stereotactic radiosurgery for a pericallosal arteriovenous malformation involving nearly all of the corpus callosum. Follow-up magnetic resonance imaging also indicated absence of the left fornix. Functioning has been assessed over 7 years. Neuropsychological measures identified a consistent pattern of verbally mediated cognitive and memory deficits, with relatively spared visual perceptual and visual motor functioning. No evidence of a split-brain syndrome was found. The findings are consistent with insult to dominant hemisphere language and memory systems, provide an interesting example of neurodevelopmental compensation for significant early brain insult, and may provide insight into functions subserved by the fornix.

Introduction

Intracranial arteriovenous malformations (AVMs) are relatively rare congenital neurodevelopmental abnormalities involving premature cessation in cerebral vascular arterial and venous differentiation that effectively replace capillary bed connections with pipe-like fistulas, decreasing vascular resistance and contributing to preferential arterial flow (Luessenhop and Gennarelli, 1977; Vinuela *et al.*, 1985; Mahalick *et al.*, 1991; Gomez-Tortosa *et al.*, 1995). Historically, population base rates for AVMs are estimated to be 1.4 per 1000 (Michelsen, 1979). Symptoms include intracranial hemorrhage, seizures, headaches, focal neurological anomalies, progressive neurological deficits, and neurobehavioral changes (Michelsen, 1979; Mahalick *et al.*, 1991, 1993; Gomez-Tortosa *et al.*, 1995).

Pericallosal AVMs are uncommon in reported series and case reports; those that include pericallosal AVMs amongst reported anatomical foci generally do not differentiate functional outcome by location of the AVM (Luessenhop and Gennarelli, 1977; Vinuela *et al.*, 1985, 1991; Levin *et al.*, 1987; Solomon and Stein, 1987; Mahalick *et al.*, 1991;

Germano *et al.*, 1992; Gomez-Tortosa *et al.*, 1995; Steinberg *et al.*, 1996; Riva *et al.*, 1997). Literature on brain AVMs cannot be wholly generalized to pericallosal AVMs, which are primarily supplied by pericallosal arteries and represent distinct anatomical and clinical entities (Yasargil *et al.*, 1976a). Insult in the region of the pericallosal arteries has the potential to be particularly grave due to anatomical features such as the lack of resistant arachnoid membranes at the level of the pericallosal cisterns (Thomas and Paterson, 1975; Sindou *et al.*, 1988). Deficits associated with pericallosal damage are heterogeneous and the types of callosal syndrome frequently observed in neoplastic lesions are rarely seen with pericallosal AVMs (Yasargil *et al.*, 1976a).

In case reports of the surgical treatment of pericallosal AVMs, disconnection symptoms or split-brain effects are either absent or considerably less apparent than might be expected (Sperry, 1968; Zaidel and Sperry, 1974; Yasargil *et al.*, 1976b; LeDoux *et al.*, 1977; Levin *et al.*, 1987; Graff-Radford *et al.*, 1987). Callosal disruption has been associated with apraxia (Watson and Heilman, 1983;

Graff-Radford *et al.*, 1987; Kohmura *et al.*, 1990). The most common neurobehavioral problem reported after pericallosal damage is memory disorder (Sperry, 1968; Zaidel and Sperry, 1974; LeDoux *et al.*, 1977; Huppert, 1981; Graff-Radford *et al.*, 1987; Solomon and Stein, 1987). The majority of studies of pericallosal damage involve adult patients. There is little information on pediatric patients and virtually no longitudinal data describing outcomes in developing, rather than adult, brains.

Reports of memory or neurocognitive deficits associated with AVMs tend to include little or no detailed neuropsychological assessment. Table 1 presents a composite of studies involving pericallosal AVMs and associated neuropsychological testing or outcomes. Mahalick *et al.* (1991, 1993) followed a group of 14 right and left hemisphere AVM patients with pre- and post-surgical neuropsychological assessments. However, there were no children or pericallosal AVMs involved. In addition, as noted by the authors, these patients were functioning at relatively high levels, and were excluded if they manifested multiple AVMs, had previous resection, embolization, or radiation. Gomez-Tortosa *et al.* (1995) reported 10 patients with left hemispheric AVMs. No children or pericallosal AVMs were involved. Riva *et al.* (1997) studied eight patients between the ages of 9 and 18 years who were treated with gamma knife radiosurgery for AVMs and evaluated an average of 6 years post-treatment. No periventricular AVMs were reported and only AVMs less than 3 cm in diameter were involved in the study. It was noted that, as in other developmental studies, (Vargha-Khadem *et al.*, 1985; Aram, 1988; Riva *et al.*, 1991; Ye *et al.*, 1998) lesion size was not clearly correlated with severity of deficits. Levin *et al.* (1987) reported on one adult male and one adolescent (16-year-old) female patient with pericallosal AVMs. However, the presented neuropsychological data were not based on a thorough evaluation, rather on typical screening procedures.

Early outcome data regarding memory disturbance associated with callosal AVMs were equivocal. In Zaidel and Sperry's (1974) important paper on memory function in 10 commissurotomy patients, marked persistent difficulty with short-term memory was reported. These patients had most difficulty on semantically complex subtests, and exhibited great difficulty in recollection of ideas or specific facts. Neuropsychological test results from a patient with left fornix resection were weaker on verbal tasks, and stronger on non-verbal tasks, than those of a patient with a resected right fornix. In contrast, LeDoux *et al.* (1977) described an extensive evaluation, including pre- as well as post-operative data, of a callosotomy patient in which the results were interpreted as failing to document cognitive disruption. They noted that the discrepancy in the results may be attributable to methodological differences.

Solomon and Stein (1987) presented a series of 22 primarily thalamocaudate AVMs surgically removed by an interhemispheric approach through the posterior corpus callosum and atrium of the lateral ventricle. It was noted that five of six

patients who developed bleeds on the left (dominant) side developed memory problems consequent to AVM rupture. Only one of 16 patients with right-sided or bilateral lesions had pre-operative memory disturbance. Five more patients developed post-operative memory dysfunction, one of whom had a bilateral AVM requiring sacrifice of both fornices and the corpus callosum. They concluded that their data suggested a critical role for the left fornix, thalamus, and/or caudate nucleus in recent memory function.

As the previous review suggests, there is a relative absence of detailed studies of pericallosal AVMs in children, none of which employ neuropsychological methods for long-term outcome assessment. This study presents detailed data on a boy who was surgically treated and has been followed neuropsychologically for 7 years at this medical center.

Case history

Initial hemorrhage

CA was a 6-year, 8-month-old right-handed boy with a normal developmental history and no indication of early academic or cognitive deficits. He was in good health and attending kindergarten until April 1992, when he began experiencing headaches, nausea, and vomiting. He presented to a local hospital where a computed tomography (CT) scan of the head revealed a hemorrhage in the region of the corpus callosum. Magnetic resonance imaging (MRI) and cerebral angiography indicated an extensive AVM of the corpus callosum fed primarily by the left pericallosal artery, with small feeders posteriorly from the anterior choroidal artery (see Fig. 1). A lumbar drain was placed.

One month later, CA presented at Shands Hospital at the University of Florida for surgical treatment of the AVM. He was on no medication and reported no drug allergies. Past medical history was remarkable for a tonsillectomy and adenoidectomy at the age of 2 years. A physical examination at the time was unremarkable. He underwent a cerebral arteriogram and extensive embolization of the AVM with polyvinyl alcohol (PVA) and was taken to the operating room for surgical intervention.

Initial surgical procedure

CA's initial surgery involved dissection down through the interhemispheric fissure. With bipolar coagulation, large feeding branches were clipped and the nidus resected anteriorly, then posteriorly to approximately three-quarters the length of the corpus callosum. Dissection of the nidus was carried into the corpus callosum itself. A post-operative examination revealed CA to be neurologically unchanged from his pre-operative evaluation. He was discharged 1 week post-surgery on prophylactic Dilantin 80 mg po tid.

Second hemorrhage

Six months later, CA was in his usual state of health when he developed sudden headaches, nausea, vomiting,

Table 1. Previous studies involving pericallosal arteriovenous malformations (AVMs)

Author	Age range (mean age)	Sex (M/F)	n	Callosal lesion	Procedure	Administered neuropsychological testing	Outcome specific to callosal insult
Lazar <i>et al.</i> (1999)	9	F	1	Ruptured CC AVM, intraventricular hemorrhage, hydrocephalus, status	Left ventriculostomy catheter placement, pentobarbital coma (9 days)	Notes neuropsychological testing, none reported	Short-term memory deficit, left hemiparesis, left upper extremity dysmetria
Riva <i>et al.</i> (1997)	9–18 (13)	3/5	8	AVMs < 3 cm in diameter, no CC	Gamma knife radiosurgery	Extensive	No CC
Steinberg <i>et al.</i> (1996)	7–64 (30)	13/20	33	Three CC AVM	Surgical resection post-radiosurgery; 25 embolization	None	None
Gomez-Tortosa <i>et al.</i> (1995)	22–53 (36)	4/6	10	Left hemisphere AVMs, no CC	Embolization and surgery	Extensive	No CC
Mahalick <i>et al.</i> (1993)	16–69 (36)	4/10	14	Left and right AVMs, no CC	Surgical resection	Extensive	No CC
Minakawa <i>et al.</i> (1992)	0–50 (21)	5/4	9	One CC	Not elaborated	None	None
Germano <i>et al.</i> (1992)	10–65 (36)	38/28	66	One CC AVM	Resection post- embolization	None	None
Mahalick <i>et al.</i> (1991)	NA (34)	8/16	24	Left and right AVMs, no CC	Surgical resection	Extensive	No CC
Vinuela <i>et al.</i> (1991)	11–67 (34)	57/44	101	12 CC	Embolization and surgical removal	None	One 'Severe memory deficit'
Levin <i>et al.</i> (1987)	16	F	One of two case studies	AVM with hematoma and gliosis in genu of CC	Surgical lesion to 2 mm of anterior CC	Serial assessment of interhemispheric transfer of information	Verbal and visual reproductive memory deficit
Vinuela <i>et al.</i> (1985)	6–59 (29)	24/29	53	12 CC	Angiographic evaluation	None	None
Yasargil <i>et al.</i> (1976a)	16–38 (28)	8/2	10	Splenium of the CC	Radical excision	None	None
Yasargil <i>et al.</i> (1976b)	7–45 (24)	5/3	8	Anterior and middle CC (one also splenium)	Radical excision	None	None

CC, corpus callosum.

It should be noted that a number of studies did not report neuropsychological testing or results due to the non-cognitive (e.g. surgical procedure) focus of the paper.

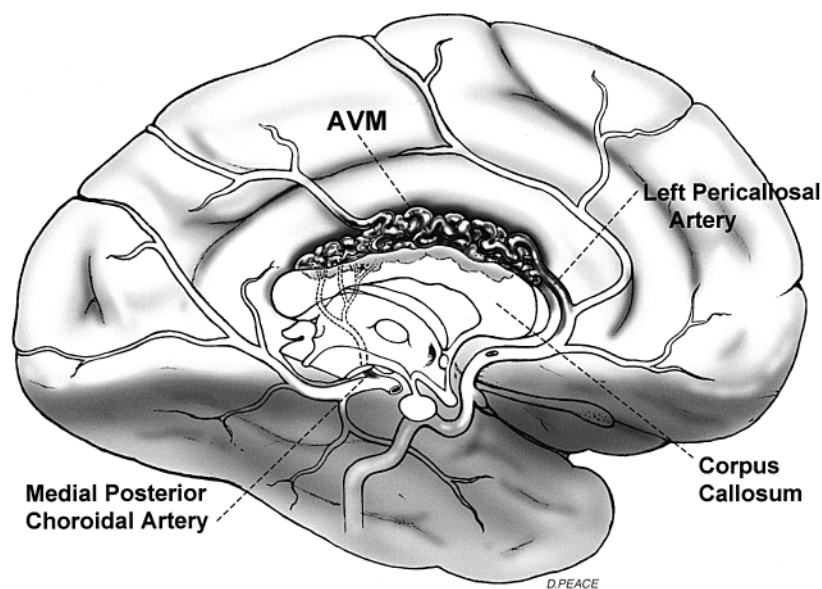


Fig. 1. Mid-sagittal illustration of the location and extent of CA's arteriovenous malformation and feeder vessels.

and photophobia. His condition rapidly deteriorated and he became unresponsive. A CT scan at a local hospital revealed a large left intraventricular hemorrhage extending into the third and fourth ventricles. CA became more somnolent and required neurosurgical placement of a right ventricular catheter in the lateral horn and third ventricle. After several hours CA gradually awoke, was extubated, and allowed to normalize. Over the next few days he regained most of his strength; after 5 days he was neurologically intact. His ventriculostomy was removed prior to transfer by helicopter to Shands Hospital. There, CA presented with extreme headaches, meningismus, and photophobia. He was responsive but in quite a bit of pain and was admitted to the Neurosurgery Service. A cerebral angiogram showed a persistent pericallosal AVM. A CT scan of the head without contrast was performed to evaluate for hydrocephalus and comparison with the scan from 4 days earlier. The comparison showed similar findings, with high-density blood products filling the body of the left lateral ventricle, left frontal horn, and third ventricle. Some mild ventriculomegaly was noted.

Second surgical procedure

Two weeks later, in late November 1992, CA was admitted for elective repeat craniotomy and resection of the residual left corpus callosum AVM. The left frontal lobe and falx were retracted and the AVM was noted diffusely involving the corpus callosum. The majority of the body of the corpus callosum was resected, with a small anterior portion and the splenium left intact. Upon resection, the left lateral ventricle was entered and an extensive amount of old clot was suctioned. Post-operatively, CA was neurologically intact and was brought to the Pediatric Intensive Care Unit for recovery in a stable condition.

CA's recovery was uneventful. No recurrence of intraven-

tricular bleeding was noted. However, an angiogram performed 5 days after surgery showed some persisting AVM. A CT scan revealed small extra-axial fluid collections along the falx anteriorly and along the frontopolar regions bilaterally, without significant mass effect. An encephalomalacic defect was noted in the region of the body and left genu of the corpus callosum. Small amounts of residual blood products were evident without evidence of focal hematoma. The lateral ventricular size was within upper limits of normal bilaterally. A focal area of low attenuation in the upper right thalamus was noted, possibly a reflection of retraction during surgery. Following a normal neurological examination 8 days later, CA was discharged and scheduled to return in 1 month to determine final disposition.

Stereotactic radiosurgery

Following a review of previous incidents and procedures, stereotactic radiosurgery was recommended. Linear accelerator (LINAC) radiosurgery is a hybrid of surgery and radiotherapy [for a complete description, see Friedman *et al.* (1998)]. It involves a one-time application of high-dose radiation to a neuroanatomical target at the precise isocenter of multiple stereotactically targeted arced fields. Target placement accuracy is accomplished through a fixed relationship between a rigidly attached stereotactic head ring and associated CT, MRI, and angiographic images of the target lesion. The greatest drawback of radiosurgery for AVM is that it does not appear to protect against hemorrhage until the AVM is completely thrombosed and obliterated. This typically takes 1–3 years, during which time the patient remains at risk of re-hemorrhage.

A pre-surgical stereotactic CT with contrast enhancement carried out in April 1993 revealed evidence of increased vascularity along the pericallosal cistern with a small compon-

ent of apparent nidus in the region of the splenium of the corpus callosum. A small lacunar infarction was seen in the right thalamus. The pre-surgical stereotactic CT was compared with angiography and transferred to the stereotactic treatment planning computer where an optimal treatment plan was developed. CA then underwent an uneventful radiosurgery treatment with seven arcs, 1750 centigray (cGy) (1 cGy is equivalent to 1 rad) to the 80% isodose line through a 20 mm collimator. As is usual with this procedure, CA went home later that day.

Neurological follow-up

A post-surgical follow-up cranial MRI was performed in October 1993. In comparison with earlier CT scans, CA had continuing mild porencephalic atrophic dilation of the left frontal horn adjacent to the region of the callosal, interhemispheric, and high convexity encephalomalacic change, possibly related to prior hemorrhage or surgery. Hypervascularity was evident in the immediate left juxta-midline corpus callosum and cingulate gyrus area, with distortion and generally complete replacement of the anterior corpus callosum by the hypervascular nidus. The rostrum of the corpus callosum and the immediate perisplenial area were relatively uninvolved. Some current diminished vascularity was evident. Due to the extended period of time necessary prior to the final estimate of radiosurgical necrotic impact on an AVM, future angiographic studies to assess for improvement over the next 1–2 years were recommended.

CA had another follow-up post-operative non-contrast head MRI with Circle of Willis area MRA in June 1994 (see Fig. 2a–c). The MRI showed a static lesion with areas of encephalomalacic defect in the region of the mid and anterior body of the corpus callosum and above an AVM in the left genu and body of the corpus callosum and region of the cingulate gyrus. Some atrophic dilation of the left lateral ventricle beneath the lesion was apparent. Minimal residual hypervascularity, primarily dilated interhemispheric draining veins approximately midline above the anterior body of the corpus callosum, may have represented residual nidus. The anterior half of the corpus callosum was essentially absent. T1 coronal images of the lateral ventricles demonstrated absence of the left fornix and presence of the right fornix.

Two years later, CA was seen by his pediatric neurosurgeon for a follow-up out-patient visit. CA was doing extremely well, had no headaches, no seizures, and was off all medication.

Materials and methods

Neuropsychological assessment

CA was initially tested on 29 October 1993, at the age of 8 years and 1 month, 6 months after his last surgical procedure. He was most recently tested on 12 July 2000, at the age of 14 years and 10 months. Over the intervening

years, he was evaluated with partial test batteries on four occasions. Data from those evaluations are relatively consistent with the results from his initial and most recent assessments. The measures employed include the following.

General intelligence. Wechsler Intelligence Scale for Children-Third Edition (WISC-III; Wechsler, 1991).

Memory. Wide Range Assessment of Memory and Learning (WRAML; Sheslow and Adams, 1990). California Verbal Learning Test-Children's Version (CVLT-C; Delis *et al.*, 1994).

Language. Test of Language Competence-Expanded Edition (TLC-E; Wiig and Secord, 1989).

Visual motor. Beery Developmental Test of Visual Motor Integration (VMI; Beery, 1989, 1997).

Results

Preliminary testing

During CA's initial evaluation, he was administered tests for callosal syndromes, including cross transfer of forms and objects and callosal hand positions. Other tasks were administered, such as intermanual point (finger) localization, repetitive and successive finger movements and heel and toe taps. Praxis and smell were also evaluated. There was no evidence of split-brain effects, apraxia, or anosmia. Due to these initial results and consistently average range motor testing across time, callosal functioning was not reassessed.

Cognitive functioning: general intelligence

CA was administered the WISC-III to provide a continuing measure of his overall intellectual abilities. The test is divided into two parts. The first is a Verbal Scale, comprising subtests that assess word knowledge, verbal problem-solving skills, general information, verbal abstraction, and auditory memory. The second is the Performance Scale, consisting of subtests used to measure non-verbal abstraction and problem-solving skills, visual perceptual skills, and sequencing ability.

As seen in Table 2, CA's overall functioning currently tests below the average range of intelligence. However, there is a significant difference between the scores on verbal and non-verbal problem-solving measures. Although his verbal comprehension falls significantly below the average range, CA's perceptual organizational skills and visual motor processing speed test solidly in the average range. This pattern has remained relatively constant since his initial assessment in 1993. CA's raw scores increased on all subtests (not shown), albeit at a slower rate than same-age peers. Consequently, scaled score declines may be noted on several subtests. None, however, dropped below the average range or represented a decline in cognitive functioning.

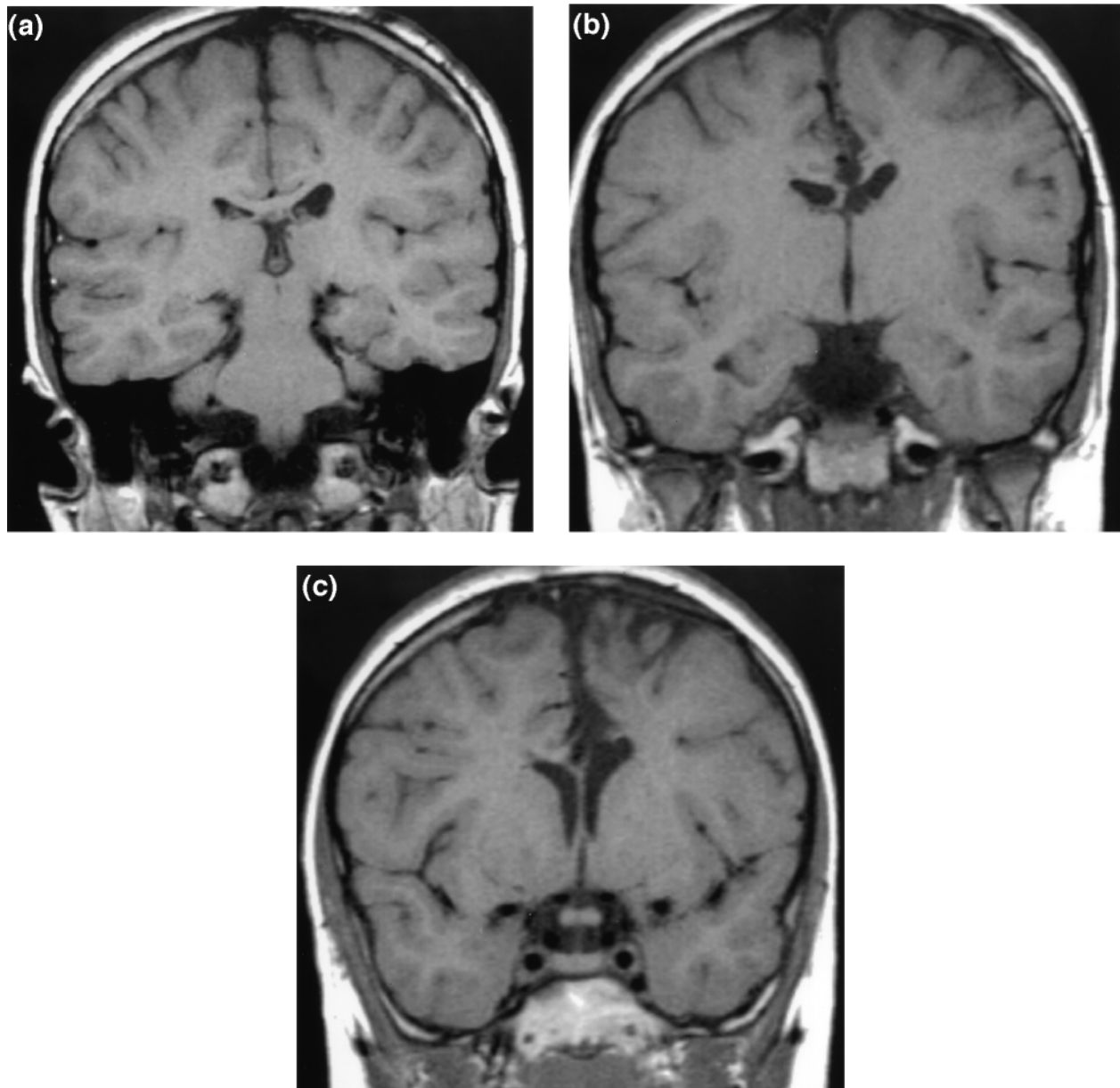


Fig. 2. Coronal brain sections from CA's post-operative non-contrast magnetic resonance image from June 1994, 13 months following the last surgery. (a) Posterior to appearance of lesion, (b) transitional zone demonstrating the pericallosal arteriovenous malformation and absence of left fornix, (c) anterior view demonstrating the extensive lesion and loss of the anterior corpus callosum.

Within the verbal scale, nearly all of CA's scores fell below the average range, with the exception of measures of short-term auditory memory for numbers and attention and facility in mental arithmetic. Both of these subtests are sensitive to distractibility, indicating that CA has the ability to focus and attend to verbal problem-solving tasks. In addition, CA's ability to repeat numbers in reverse order, which requires excellent concentration, representational thinking, spatial visualization and the ability to re-code information in working memory, tested better than his ability to remember and sequentially repeat a string of numbers. CA scored below the average range on tasks involving his ability to select and verbalize appropriate relationships between two objects or concepts, and on measures of word knowledge

and ability to verbalize understanding of social judgment and common sense. His weakest score was on a measure of his general fund of factual knowledge, which is affected by semantic memory and school-based learning abilities and experiences.

CA's scores on subtests of the Performance Scale all fell within the average range of functioning for his age group, indicating age-expected ability on measures of non-verbal intelligence. Current scores are generally consistent with earlier evaluations. Some areas show a slight decline from his initial assessment, particularly on tasks involving speeded visual perceptual scanning ability and speed and accuracy of eye-hand coordination. However, as noted, his performance did not fall below the average range. CA's best score was on

Table 2. CA's index (average range = 100 ± 15) and scaled (average range = 10 ± 3) scores from the Wechsler Intelligence Scale for Children-Third Edition (WISC-III)

	12 July 2000	29 October 1993
Verbal IQ	72	79
Performance IQ	95	108
Full-scale IQ	81	92
Verbal subtests		
Information	3	6
Similarities	6	7
Arithmetic	8	11
Vocabulary	4	4
Comprehension	4	3
Digit span	9	10
Performance subtests		
Picture completion	11	12
Coding	9	14
Picture arrangement	9	10
Block design	10	10
Object assembly	7	10
Symbol search	8	11

Table 3. CA's scaled scores (average range = 10 ± 3) on the Wide Range Assessment of Memory and Learning (WRAML)

	July 2000	October 1993
Non-verbal		
Picture memory	10	10
Design memory	11	*
Finger windows	*	2
Visual learning	8	4
Verbal		
Story memory	5	5
Sentence memory	5	3
Verbal learning	*	7

*Not administered.

a measure of his ability to visually differentiate essential from non-essential details. He also scored solidly in the average range on measures of spatial visualization and non-verbal reasoning and on a non-verbal measure of his ability to comprehend and evaluate social situations.

Overall, CA presents a continuing pattern of average range performance on non-verbal measures of intelligence and significantly below average verbally mediated cognitive abilities. It is notable that verbal measures involving the ability to attend and concentrate do not implicate attention and concentration as sources of verbally mediated deficits.

Memory

CA received selected subtests from the WRAML. As seen in Table 3, CA's performance on non-verbal memory tasks fell within the average range of functioning. His ability to remember and recall contextually relevant visual stimuli (cartoon pictures of scenes with people in commonplace situations), and to remember and reproduce abstract geometric figures, fell solidly within the average range. He had more difficulty memorizing the locations of abstract geometric

Table 4. CA's raw and standard scores (average range = 100 ± 15) from the California Verbal Learning Test-Children's Version (CVLT-C) from July 2000

Levels of recall (number correct)	Raw score	Standard score
List A total—Trials 1–5	25	55.0
List A Trial 1—free recall	7	100.00
List A Trial 5—free recall	4	40.0
List B—free recall	4	77.5
List A Short delay—free recall	6	70.0
List A Short delay—cued recall	4	55.0
List A Long delay—free recall	5	62.5
List A Long delay—cued recall	5	62.5
Recall errors		
Total perseverations (free and cued recall)	4	108.00
Total free recall intrusions	4	92.5
Total cued recall intrusions	4	70.0
Total free and cued recall intrusions	8	85.0
Recognition error		
Total false positives	11	25.0
Recognition discriminability	0.71	32.5

Scores have been transformed from the traditional clinical presentation using multivalent z-scores to standard scores for easier interpretation.

figures on a grid across multiple presentations; nonetheless, he performed in the expected range for his age group. On verbally mediated memory tasks, however, CA scored significantly below the average range. These included tasks requiring him to recall and retell short stories and to repeat sentences of increasing length. The Verbal Learning subtest was not administered during CA's most recent evaluation because he was administered a longer, more complex, version of a similar task (CVLT-C, see below). The results from the WRAML are consistent with the results from the WISC-III, and with prior evaluations, indicating that, although CA is probably not losing function, neither has there been significant change over time in the way he processes verbal and non-verbal memory.

During his most recent neuropsychological evaluation (July 2000), CA was administered the CVLT-C to assess the strategies and processes involved in learning and recall of verbal material (see Table 4). This is carried out within the context of an everyday memory task involving repeated presentations of words from primary and secondary shopping lists. CA's normal performance on List A Trial 1 indicated an intact auditory attention span. His ability to learn new material, however, was significantly impaired. Typically, when additional opportunities to learn a list of words are provided, children's recall on subsequent trials exceeds their auditory attention span. CA's normal score on List A Trial 1 and deficient scores on List A Trial 5 and List A Trials 1–5 (combined score) were indicative of a normal attention span and impaired learning. Another indication of CA's memory deficit involved the Discriminability Index, which provides a measure of the ability to discriminate target words from distracters. Accurate discriminability and impaired free and cued recall would be indicative of a deficit at retrieval. In this case, discriminability performance was weaker than recall, indicating impairment at encoding (Delis *et al.*, 1994).

Table 5. CA's scaled scores (average range = 10 ± 3) on the Test of Language Competence-Expanded Edition (TLC-E) from July 2000

	Standard score
Ambiguous sentences	4
Listening comprehension—making inferences	8
Oral expression—recreating sentences	3
Figurative language	3

This was also supported by the lack of an increase in correct responses with cueing. There was relatively little loss of information from list presentation to short and delayed recall conditions, indicating that CA was able to retain information once it was learned. His pattern of endorsements reflected a bias towards items prototypical of item categories on the multiply repeated first word list. Although his very high false-positive rate may be interpreted as an indication of confabulation, it may also be indicative of a compensatory mechanism such as a reliance on conjecture.

Complex language functioning

CA's difficulty with the verbal components of intelligence and memory testing suggested the need for a measure of complex language function. During his July 2000 evaluation he was administered the TLC-E, a test designed to evaluate the emergence of linguistic competence and use of semantic, syntactic, and pragmatic language strategies (Table 5)

CA had considerable difficulty with three of the four subtests on the TLC-E. His best score, falling in the average range, was on the Listening Comprehension subtest, which required him to make plausible inferences from the beginning and end statements of a causal event chain to identify the two most feasible intervening events from four visually (printed) and vocally presented choices. His scores on the other three subtests fell two or more standard deviations below the average range. On a measure of his ability to provide two interpretations of lexically or structurally ambiguous sentences presented out of context, CA was only able to provide both alternatives on the most concrete and experientially common items. His ability to formulate sentences using correct grammar, syntax, and semantics incorporating three key words in the context of a given illustrated situation was also considerably impaired. Finally, CA had substantial difficulty interpreting metaphoric expressions presented in spoken and printed forms, then matching structurally related metaphoric expressions by shared meaning amongst three foils. Overall, the results of language testing indicate a significant deficiency in CA's ability to process and employ the more complex elements of both receptive and expressive language, which may be related to difficulty in language development (from the age of 6 years) in the context of substantial deficits in verbally mediated memory and cognitive processing.

Visual motor functioning

CA was administered the VMI, a measure of graphomotor ability, perceptual and fine motor control, and the integration of perceptual and motor skills. The VMI requires the copying of progressively more difficult and complex geometric designs. Performance is measured in standard scores with an average range of 100 ± 15 . CA's most recent score was 108, falling towards the upper end of the average range. His initial score in 1993 was 96. It appears that his visual motor functioning is neither impaired nor deteriorating.

Behavioral functioning

According to information gathered in an interview with CA and his mother, he has done well in school and is about to begin high school. After initially being placed in special education classes, he now has been mainstreamed and is learning with the general population, with average grades. Socially, CA is doing quite well, and he is reportedly quite athletically proficient. Although he dreams of a career as a professional athlete, CA is aware of the need for a more realistic contingency plan and is considering a career as a chef. He has been, and remains, a charming, well-adjusted young man, who has apparently overcome whatever negative psychological impact he may have incurred from the traumatic events earlier in his childhood. He has generally participated fully with testing, in spite of the redundancies involved in multiple neuropsychological testing over 7 years, which, in turn, appears to be a reflection of his overall positive attitude towards working to succeed. CA has the benefit of a strong, supportive relationship with his family.

Discussion

A review of neuropathological and functional findings associated with pericallosal AVMs (see Table 1) does not offer much direction in expectation for functional outcome of this case. Given the destruction of much of CA's corpus callosum, one might have expected evidence of split-brain syndrome or callosal apraxia (Watson and Heilman, 1983; Graff-Radford *et al.*, 1987). However, testing carried out 6 months after his last surgical intervention demonstrated no verbal motor disconnection or disturbance of praxis. There has been a fair amount of discussion regarding memory loss secondary to either AVM or pericallosal insult. However, the results have been neither conclusive nor specific. This study, involving a predominantly left hemispheric lesion, demonstrated a specific functional deficit in verbally mediated memory and cognition and in the development of complex language function.

CA's overall cognitive functioning measured below the average range. However, there was a significant difference between his verbal and non-verbal cognitive abilities. Parenthetically, this case provides a good example of the dangers of interpreting global IQ scores without consideration of

potential lateralized functional differences [for a more thorough discussion of the use of summary scores, see Fennell and Dikel (2001)]. CA's non-verbal problem-solving skills tested solidly in the average range for his peer group, while his verbal comprehension was very significantly below average. He continued to have difficulty with school-based, verbally mediated learning, such as his general factual knowledge base and vocabulary, and continued to show relative strength in perceptual organization and non-verbal reasoning. Although CA's raw score totals increased over time, his standard scores declined somewhat as a function of his slower rate of progress and acquisition than the normative group. Tasks measuring memory produced results consistent with measures of CA's general cognitive functioning. On measures of non-verbal memory, he performed in the average range. On verbally mediated material, however, he had considerable difficulty forming new memories. Once he learned, he successfully retained learned information.

The type of memory disturbance seen in this case bears some resemblance to an earlier case reported by Heilman and Sybert (1977). This involved a 41-year-old female with a tumor involving the fornix, with no direct involvement of the hypothalamus or medial temporal lobe. Radiological and surgical observation indicated no lesion in the hippocampi, mammillary bodies, or medial dorsal thalamic nuclei. As with Huppert's (1981) patients, who needed longer presentation to acquire new knowledge but demonstrated normal retention once knowledge was attained, this memory defect resembled the anterograde amnesia characterizing Korsakoff syndrome. This diencephalic, rather than hippocampal, pattern of memory disturbance, has been associated with the mammillary bodies or dorsomedial nucleus of the thalamus. However, this could not be the case with Heilman and Sybert's patient.

Solomon and Stein (1987) reported memory dysfunction in several of their patients. They noted that the roof and posterior face of the atrium of the lateral ventricle is formed by the posterior body and splenium of the corpus callosum, with the body of the caudate lying inferolaterally. The floor of the atrium is formed by the posterior thalamus and the fornix lies medially in the area of the choroidal fissure. They suggested the possibility of an extension of language dominance to the limbic system and posited the potential importance of the left fornix to recent memory function. As noted above, CA's MRI indicates a missing left fornix.

The results from CA's neuropsychological testing are generally consistent with an injury to the left, language-dominant, side of the brain. A test of complex language function demonstrated significant problems with expressive and receptive higher language abilities, including verbal ambiguity, creative expression, and interpretation and expression of subtle or complex intentions. Neuroanatomical radiological findings were consistent with CA's surgical history and past hemorrhaging in the body of the left lateral ventricle, frontal horn, and third ventricle. These included high convexity encephalomalacic changes and mild ventriculomegaly and mild porencephalic atrophic dilation above the AVM of

the left genu and body of the corpus callosum and cingulate gyrus and below the lesion in the left lateral ventricle. However, this would not fully explain CA's language impairment. Vascular injury to the anterior language-dominant hemisphere is consistent with frontal damage associated with naming deficits and word-finding problems. There is also the possibility of a disconnection between anterior and posterior areas associated with reading ability. However, the contribution of verbal memory to language development, for example, in the contribution of early episodic memory to the development of later semantic memory, may more likely be associated with the loss of the left fornix.

Our understanding of the role of the hippocampus (and immediately adjacent structures with which it is functionally linked) in memory acquisition and consolidation has progressed tremendously in the past 10 years. A thorough review of this literature is beyond the scope of this case report (see Hasselmo *et al.*, 1996; Gluck and Myers, 1997, 2001; Gabrieli, 1998; Rolls and Treves, 1998; Hasselmo and McClelland, 1999; Lavenex and Amaral, 2000; Rolls, 2000). However, this new knowledge may contribute to understanding how CA's fornix lesion may also have played a critical role in the development of his verbally mediated memory and cognitive deficits. The fornix is the major pathway by which cholinergic projections from the medial septal nuclei and the nuclei of the vertical limb of the diagonal band of Broca pass to the hippocampus (Lewis and Shute, 1967; Hasselmo *et al.*, 1996; Dickinson-Anson *et al.*, 1998). Acetylcholine is essential to the function of the hippocampal memory system, functioning to modulate network dynamics and hippocampal plasticity (Hasselmo *et al.*, 1996; Everitt and Robbins, 1997; Gluck and Myers, 1997; Hasselmo and McClelland, 1999; Ratliff and Voorhies, 1999; Rolls, 2000). Disruption of the septohippocampal cholinergic projection can produce devastating memory impairment and may be implicated in the memory impairments seen in Alzheimer's disease (Gluck and Myers, 2001). It is likely that this disruption of acetylcholine to the left hippocampus, over the course of brain and language development, may have played an important role in the development and maintenance of CA's verbally mediated memory and language problems.

Conclusion

This case report holds considerable interest in terms of the paucity of literature involving neuropsychological assessment of pericallosal AVMs in children. It is also an instructive case example in our developing understanding of the role of the fornix in medial temporal lobe memory systems. Due to advances in brain imaging, we were able to identify a specific lesion involving the left fornix that might otherwise have gone unnoticed, given the scope of CA's callosal damage. The results of neuropsychological testing are consistent with the developing understanding of the role of the fornix and acetylcholine in the hippocampal memory system. This study also provides an example of the benefit of neuropsychological

testing in concert with neuroradiological examinations to provide measures of structure and function in our patients.

This case is also notable for CA's achievements, given the severity and extent of his early neurological insult. In several reports, any combination of two or more of the hemorrhages or surgical procedures incurred by this boy have led to severely disrupted functioning (Yasargil *et al.*, 1996a). CA is generally living a normal life. This in itself is remarkable, and may offer insight into the resilience and adaptability of early brain development.

Acknowledgements

This research was supported, in part, by the National Institutes of Health, National Research Service Award T32HD07524 from the National Institute of Child Health and Human Development. The authors would like to thank CA and his family for their cooperation and support, and Dr Kenneth Heilman for his comments and suggestions in the formative stages of this paper.

References

- Aram DM. Language sequelae of unilateral brain lesions in children. In: Plum F, editor. *Language, communication and the brain*. New York: Raven Press, 1988: 171–97.
- Beery KE. *Manual for the Developmental Test of Visual Motor Integration—Third Revision*. Cleveland: Modern Curriculum Press, 1989.
- Beery KE. *Manual for the Beery-Buktenica Developmental Test of Visual Motor Integration*. Parsippany, NJ: Modern Curriculum Press, 1997.
- Delis DC, Kramer JH, Kaplan E, Ober BA. *Manual for the California Verbal Learning Test—Children's Version*. San Antonio: The Psychological Corporation, 1994.
- Dickinson-Anson H, Aubert I, Gage FH, Fisher LJ. Hippocampal grafts of acetylcholine-producing cells are sufficient to improve behavioural performance following a unilateral fimbria-fornix lesion. *Neuroscience* 1998; 84: 771–81.
- Everitt BJ, Robbins TW. Central cholinergic systems and cognition. *Annual Review of Psychology* 1997; 48: 649–84.
- Fennell EB, Dikel TN. Cognitive and neuropsychological functioning in children with cerebral palsy. *Journal of Child Neurology* 2001; 16: 58–63.
- Friedman WA, Buatti JM, Bova FJ, Mendenhall WM. *Linac radiosurgery: a practical guide*. New York: Springer, 1998.
- Gabrieli JDE. Cognitive neuroscience of human memory. *Annual Review of Psychology* 1998; 49: 87–115.
- Germano IM, Davis RL, Wilson CB, Hieshima GB. Histopathological follow-up study of 66 cerebral arteriovenous malformations after therapeutic embolization with polyvinyl alcohol. *Journal of Neurosurgery* 1992; 76: 607–14.
- Gluck MA, Myers CE. Psychobiological models of hippocampal function in learning and memory. *Annual Review of Psychology* 1997; 48: 481–514.
- Gluck MA, Myers CE. *Gateway to memory: an introduction to neural network modeling of the hippocampus and learning*. Cambridge, MA: The MIT Press, 2001.
- Gomez-Tortosa E, Sychra JJ, Martin EM *et al.* Postoperative cognitive and single photon emission computed tomography assessment of patients with resection of perioperative high-risk arteriovenous malformations. *Neurosurgery* 1995; 36: 447–57.
- Graff-Radford NR, Welsh K, Godersky J. Callosal apraxia. *Neurology* 1987; 37: 100–5.
- Hasselmo ME, McClelland JL. Neural models of memory. *Current Opinion in Neurobiology* 1999; 9: 184–8.
- Hasselmo ME, Wyble BP, Wallenstein GV. Encoding and retrieval of episodic memories: role of cholinergic and GABAergic modulation in the hippocampus. *Hippocampus* 1996; 6: 693–708.
- Heilman KM, Sybert GW. Korsakoff's syndrome resulting from bilateral fornix lesions. *Neurology* 1977; 27: 490–3.
- Huppert FA. Memory in split-brain patients: a comparison with organic amnesic syndromes. *Cortex* 1981; 17: 303–12.
- Kohmura E, Taki T, Tanioka T. Multiple intracerebral arteriovenous malformations in deep structure—case report. *Neurologia Medico-Chirurgica (Tokyo)* 1990; 30: 624–7.
- Lavenex P, Amaral DG. Hippocampal–neocortical interaction: a hierarchy of associativity. *Hippocampus* 2000; 10: 420–30.
- Lazar LM, Milrod LM, Solomon GE, Labar DR. Asynchronous pentobarbital-induced burst suppression with corpus callosum hemorrhage. *Clinical Neurophysiology* 1999; 110: 1036–40.
- LeDoux JE, Risse GL, Springer SP, Wilson DH, Gazzaniga MS. Cognition and commissurotomy. *Brain* 1977; 100: 87–104.
- Levin HS, Goldstein FC, Ghostine SY, Weiner RL, Crofford MJ, Eisenberg HM. Hemispheric disconnection syndrome persisting after anterior cerebral artery aneurysm rupture. *Neurosurgery* 1987; 21: 831–8.
- Lewis PR, Shute CC. The cholinergic limbic system: projections to hippocampal formation, medial cortex, nuclei of the ascending cholinergic reticular system, and the subfornical organ and supra-optic crest. *Brain* 1967; 90: 521–40.
- Luessenhop AJ, Gennarelli TA. Anatomical grading of supratentorial arteriovenous malformations for determining operability. *Neurosurgery* 1977; 1: 30–5.
- Mahalik DM, Ruff RM, Hs U. Neuropsychological sequelae of arteriovenous malformations. *Neurosurgery* 1991; 29: 351–7.
- Mahalik DM, Ruff RM, Heary RF, Hs U. Preoperative versus postoperative neuropsychological sequelae of arteriovenous malformations. *Neurosurgery* 1993; 33: 563–70.
- Michelsen WJ. Natural history and pathophysiology of arteriovenous malformations. *Clinical Neurosurgery* 1979; 26: 307–13.
- Minakawa T, Tanaka R, Koike T, Takeuchi S, Abe H. Cerebral arteriovenous malformations associated with a straight sinus anomaly. *Neurosurgery* 1992; 31: 19–24; discussion 24–5.
- Ratliff J, Voorhies RM. Arteriovenous fistula with associated aneurysms coexisting with dural arteriovenous malformation of the anterior inferior falx. Case report and review of the literature. *Journal of Neurosurgery* 1999; 91: 303–7.
- Riva D, Milani N, Devoti M. Late sequelae of right versus left hemispheric lesion. In: Pavao Martins I, Castro-Caldas A, Van Dongen HR, editors. *Acquired aphasia in children. Acquisition and breakdown of language in the developing brain*. Dordrecht: Kluwer Academic, 1991: 213–24.
- Riva D, Pantaleoni C, Devoti M, Lindquist C, Steiner L, Giorgi C. Radiosurgery for cerebral AVMs in children and adolescents: the neurobehavioral outcome. *Journal of Neurosurgery* 1997; 86: 207–10.
- Rolls ET. Memory systems in the brain. *Annual Review of Psychology* 2000; 51: 599–630.
- Rolls ET, Treves A. *Neural networks and brain function*. New York: Oxford University Press, 1998.
- Sheslow D, Adams W. *Manual for the Wide Range Assessment of Memory and Learning*. Wilmington, DE: Wide Range, 1990.
- Sindou M, Pelissou-Guyotat I, Mertens P, Keravel Y, Athayde AA. Pericallosal aneurysms. *Surgical Neurology* 1988; 30: 434–40.
- Solomon RA, Stein BM. Interhemispheric approach for the surgical removal of thalamocaudate arteriovenous malformations. *Journal of Neurosurgery* 1987; 66: 345–51.
- Sperry RW. Hemisphere deconnection and unity in conscious awareness. *American Psychologist* 1968; 23: 723–33.
- Steinberg GK, Chang SD, Levy RP, Marks MP, Frankel K, Marcellus M. Surgical resection of large incompletely treated intracranial arteriovenous malformations following stereotactic radiosurgery. *Journal of Neurosurgery* 1996; 84: 920–8.
- Thomas DG, Paterson A. Results of surgical treatment of pericallosal aneurysms. *Journal of Neurology, Neurosurgery, and Psychiatry* 1975; 38: 827.
- Vargha-Khadem F, O'Gorman AM, Watters GV. Aphasia and handedness in relation to hemispheric side, age at injury and severity of cerebral lesion during childhood. *Brain* 1985; 108: 677–96.
- Vinuela F, Nombela L, Roach MR, Fox AJ, Pelz DM. Stenotic and occlusive disease of the venous drainage system of deep brain AVMs. *Journal of Neurosurgery* 1985; 63: 180–4.
- Vinuela F, Dion JE, Duckwiler G *et al.* Combined endovascular embolization and surgery in the management of cerebral arteriovenous malformations: experience with 101 cases. *Journal of Neurosurgery* 1991; 75: 856–64.

- Watson RT, Heilman KM. Callosal apraxia. *Brain* 1983; 106: 391–403.
- Wechsler D. Manual for the Wechsler Intelligence Scale for Children-Third Edition. San Antonio: The Psychological Corporation, 1991.
- Wiig EH, Secord W. Manual for the Test of Language Competence-Expanded Edition. San Antonio: The Psychological Corporation, 1989.
- Yasargil MG, Jain KK, Antic J, Laciga R, Kletten G. Arteriovenous malformations of the anterior and the middle portions of the corpus callosum: microsurgical treatment. *Surgical Neurology* 1976a; 5: 67–80.
- Yasargil MG, Jain KK, Antic J, Laciga R. Arteriovenous malformations of the splenium of the corpus callosum: microsurgical treatment. *Surgical Neurology* 1976b; 5: 5–14.
- Ye X, Scallet AC, Kascak RJ, Carp RI. Astrocytosis and proliferating cell nuclear antigen expression in brains of scrapie-infected hamsters. *Journal of Molecular Neuroscience* 1998; 11: 253–63.
- Zaidel D, Sperry RW. Memory impairment after commissurotomy in man. *Brain* 1974; 97: 263–72.

Received on 16 March, 2001; resubmitted on 1 August, 2001; accepted on 10 August, 2001

A neuropsychological outcome study of a child's left pericallosal arteriovenous malformation with occult fornix lesion

**T. N. Dikel, E. B. Fennell, S. E. Nadeau,
R. G. Quisling, J. P. Mickle and
W. A. Friedman**

Abstract

Pericallosal arteriovenous malformations are rarely reported, particularly in children. Moreover, few arteriovenous malformation studies report thorough neuropsychological outcome data for assessing post-surgical functioning. This case report provides a longitudinal study of a boy who initially presented for neuropsychological testing at the age of 8 years and 1 month, following polyvinyl alcohol embolization, two craniotomies and resections and stereotactic radiosurgery for a pericallosal arteriovenous malformation involving nearly all of the corpus callosum. Follow-up magnetic resonance imaging also indicated absence of the left fornix. Functioning has been assessed over 7 years. Neuropsychological measures identified a consistent pattern of verbally mediated cognitive and memory deficits, with relatively spared visual perceptual and visual motor functioning. No evidence of a split-brain syndrome was found. The findings are consistent with insult to dominant hemisphere language and memory systems, provide an interesting example of neurodevelopmental compensation for significant early brain insult, and may provide insight into functions subserved by the fornix.

Journal

Neurocase 2001; 7: 503–13

Neurocase Reference Number:

O240

Primary diagnosis of interest

Pericallosal arteriovenous malformation (pediatric)

Author's designation of case

CA

Key theoretical issue

- Impact of multiple pericallosal insults (AVM and surgical measures) and left fornix lesion on a developing brain

Key words: arteriovenous malformation; cognition; fornix; language; memory; MRI; neuropsychological measures; pediatric; pericallosal; radiosurgery

Scan, EEG and related measures

MRI

Standardized assessment

Longitudinal neuropsychological assessment — full battery

Lesion location

- Corpus callosum, left fornix

Lesion type

Arteriovenous malformation

Language

English