

# PostScript

## LETTERS

### Rhabdomyolysis during interferon- $\beta$ 1a treatment

Interferon- $\beta$  (IFN- $\beta$ ) is one of the most effective currently available treatments for multiple sclerosis. It has also been used in the therapy of viral diseases and certain malignancies, as has the other type I interferon IFN- $\alpha$ . Most frequent side effects are transient flu-like symptoms such as myalgia, chills, and headaches. We describe a patient with relapsing-remitting multiple sclerosis who developed acute rhabdomyolysis during IFN- $\beta$  1a treatment. After the medication was discontinued, the patient improved rapidly.

A 39 year old man with a history of first symptoms in April 2000 was diagnosed as having relapsing-remitting multiple sclerosis, supported by the demonstration of oligoclonal IgG bands in the CSF but not in the blood, and multiple white matter lesions in periventricular localisations on MRI. Treatment with 22  $\mu$ g IFN- $\beta$  1a (Rebif®, Serono, Unterschleissheim, Germany) by subcutaneous injection three times weekly was initiated in October 2000 after three exacerbations with predominant sensory disturbances leading to an expanded disability status score (EDSS) of 1.5. To alleviate potential flu-like symptoms due to IFN- $\beta$  therapy, the patient was recommended to take 400 mg ibuprofen at least 2 hours before and after the time point of injection. Because he did not recognise any adverse side effects, he first stopped omeprazole medication, which he had taken occasionally, and thereafter the ibuprofen medication. He reassured us that he did not use any other drugs not prescribed by his physicians. Thus, 3 months after initiation of IFN- $\beta$  treatment the patient was only on this immunomodulatory therapy. One month later, he suddenly developed acute generalised myalgia as well as weakness 1 day after IFN- $\beta$  application and was therefore referred to the hospital. He denied any antecedent signs of infection or any trauma, but reported going bowling in the evening before the symptoms started. However, there was no difference in the amount of physical exercise compared with other weekly bowling sessions.

If you have a burning desire to respond to a paper published in *JNNP* why not make use of our "rapid response" option?

Log on to our website ([www.jnnp.com](http://www.jnnp.com)), find the paper that interests you, and send your response via email by clicking on the "eletters" option in the box at the top right hand corner.

Providing it isn't libellous or obscene, it will be posted within 7 days. You can retrieve it by clicking on "read eletters" on our homepage.

The editors will decide as before whether to also publish it in a future paper issue.

At physical examination his heart, lungs, and abdomen seemed normal, whereas neurological examination disclosed a tetraparesis with emphasis on the proximal upper limbs (power 3/5). The muscles were tender to palpation with normal muscle tonus and no increased activity of tendon reflexes. A mild intention tremor at the left arm was pre-existing.

Laboratory findings showed a marked increase in the concentrations of creatine kinase at 6632 U/l (normal range: 5-70 U/l) with normal concentrations of the isoform CK-MB, lactate dehydrogenase (LDH) at 670 U/l (normal range: 80-240 U/l), and moderately increased liver enzymes, which had been reported since the beginning of IFN- $\beta$  treatment. Myoglobinuria was not determined and there were no pathological alterations in concentrations of creatinine, urea nitrogen, C reactive protein, blood cell counts, or glucose. No electrolyte abnormalities were detectable.

With the diagnosis of a rhabdomyolysis, IFN- $\beta$  application was discontinued, the patient was subsequently monitored in the intensive care unit, and treated with intravenous fluids and bicarbonate to maintain an alkaline urine output. Under the treatment myalgia and the tetraparesis disappeared within 2 days. The patient returned to his baseline EDSS. With a delayed time course the creatine kinase declined steadily to normal values after 2 weeks. We now treat this patient with glatiramer acetate (copolymer-1) for the relapsing-remitting multiple sclerosis.

To our knowledge, this is the first reported case of rhabdomyolysis associated with IFN- $\beta$  treatment. This adverse event has been previously associated with IFN- $\alpha$ , which also belongs to the type I interferons. This, however, exhibits only 30% of homology and differs in its immunological profile. Greenfield *et al* described a patient 10 weeks after initiation of IFN- $\alpha$  treatment starting with 5 MU three times a week for chronic active hepatitis C,<sup>1</sup> and Reinhold *et al* recorded acute rhabdomyolysis 4 days after high dose IFN- $\alpha$  therapy (20 MU/m<sup>2</sup> daily) in a patient with malignant melanoma.<sup>2</sup> Remarkably, the manifestation of muscle injury occurred when the dose of IFN- $\alpha$  was being increased in both patients described, suggesting that rhabdomyolysis represents at least a dose dependent side effect of this type I interferon.

In the patient presented here the dosage of IFN- $\beta$ 1a was unaltered. Yet, the absence of any other medication, exclusion of infectious and metabolic causes usually related to a non-traumatic rhabdomyolysis, the lack of indications for an underlying metabolic muscle disorder as determined by the patients' history, the clinical presentation including laboratory investigation, and the temporal relation with IFN- $\beta$  1a application indicate that rhabdomyolysis is a possible adverse event of IFN- $\beta$  therapy. Rhabdomyolysis can also be induced by unaccustomed muscular exercise in untrained people.<sup>3</sup> However, our patient often goes bowling and thus is used to this programme.

It is concluded that creatine kinase activity should be measured when a patient complains of severe myalgia differing from the often occurring myalgia under IFN- $\beta$  treatment and, in particular when weakness is reported. This procedure might be effective in the prevention

of irreversible rhabdomyolysis during IFN- $\beta$  therapy. As a dose dependent effect of IFN- $\beta$  1a on both clinical and MRI outcomes in relapsing-remitting multiple sclerosis is known,<sup>4,5</sup> future observations will show whether increase in dosage of IFN- $\beta$  predisposes to rhabdomyolysis as reported for IFN- $\alpha$ .

J D Lünemann, N Kassim,  
R Zschenderlein, F Zipp

Division of Neuroimmunology, Department of Neurology, Charité University Hospital, Schumannstrasse 20/21, 10117 Berlin, Germany

B Schwarzenberger

Department of Nephrology, Reinickendorf Hospital, Am Nordgraben 2, 13509 Berlin, Germany

Correspondence to: Dr F Zipp;  
frauke.zipp@charite.de

### References

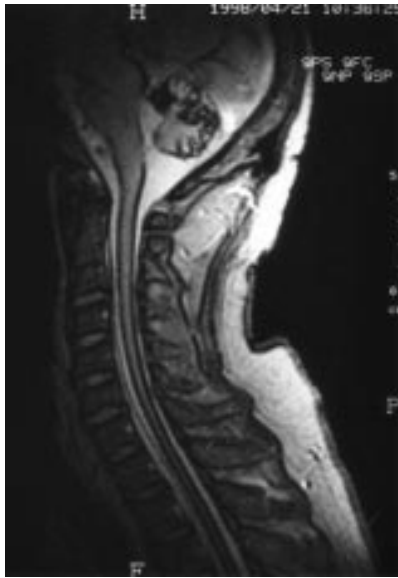
- Greenfield SM, Harvey RS, Thompson RPH. Rhabdomyolysis after treatment with interferon  $\alpha$ . *BMJ* 1994;**309**:512.
- Reinhold U, Hartl C, Hering R, *et al*. Fatal rhabdomyolysis and multiple organ failure associated with adjuvant high-dose interferon  $\alpha$  in malignant melanoma. *Lancet* 1997;**349**:540-1.
- Vanholder R, Sever MS, Ereik E, *et al*. Rhabdomyolysis. *J Am Soc Nephrol* 2000;**11**:1553-61.
- Once weekly Interferon in MS Study Group (OWIMS). Evidence of interferon  $\beta$ -1a dose response in relapsing-remitting multiple sclerosis. *Neurology* 1999;**53**:679-86.
- The PRISMS Study Group and the University of British Columbia MS/MRI Analysis Group. PRISMS-4: long-term efficacy of interferon- $\beta$  1a in relapsing MS. *Neurology* 2001;**56**:1628-36.

### Superficial siderosis associated with anterior horn cell dysfunction

Superficial siderosis of the CNS is a rare syndrome of progressive cerebellar ataxia and sensorineuronal deafness associated with haemosiderin deposition from chronic subarachnoid bleeding.<sup>1</sup> We describe a patient with typical features of superficial siderosis and an anterior horn cell syndrome, a combination that to our knowledge has never been previously reported.

A 59 year old man presented with a 4 year progressive history of unsteadiness of gait, bilaterally impaired hearing, and weakness which had begun in the left hand, spreading to involve the left arm and leg, and right hand. He had a 2 year history of cerebellar dysarthria, bladder hesitancy with postmicturition dribbling, and impotence. Examination disclosed a broad based ataxic gait with left sided limb ataxia. Apart from bilateral sensorineuronal deafness the cranial nerves were normal. There were fasciculations in the arms and legs. In the upper limbs he had asymmetric wasting and weakness of the intrinsic hand muscles, biceps, and triceps bilaterally. In the left lower limb there was wasting and weakness of the hip flexors and quadriceps. Sensory examination was normal. The deep tendon reflexes were all present and symmetric. The abdominal reflexes were present and the plantar responses were flexor.

Magnetic resonance imaging of the brain and spinal cord demonstrated haemosiderin deposition around the cerebellar folia, outlining the whole spinal cord and sacral cul



**Figure 1** T2 weighted MRI demonstrating the characteristic rim of hypointensity around the posterior fossa and spinal cord seen in superficial siderosis.

de sac (fig 1). There were no other abnormalities on the MRI and a carotid and spinal angiogram failed to disclose a source of bleeding within the CNS. The patient declined a lumbar puncture to look for evidence of active haemorrhage. There was no history of CNS trauma or surgery.

Neurophysiological examination showed normal sensory nerve conduction. Motor conduction was essentially normal. Electromyography of the first dorsal interosseus and extensor digitorum communis muscles demonstrated fibrillations and fasciculations with high amplitude units. Somatosensory evoked potentials were normal from the arms but showed delayed latencies in the legs.

A diagnosis of superficial siderosis was made and he was given a trial of subcutaneous desferrioxamine fortnightly for 8 weeks with no benefit. The patient has continued to deteriorate.

Superficial siderosis of the CNS is a clinical syndrome characterised by progressive cerebellar ataxia and sensorineuronal deafness. Pyramidal signs develop in 76% and other features that may occur include dementia (24%), a neurogenic bladder (24%), anosmia (17%), anisocoria (10%), sensory signs (13%), and less frequent features are extraocular motor palsies, backache, sciatica, and lower motor neuron signs (all 5%–10%).<sup>1</sup> Interestingly, in superficial siderosis the vestibulocerebellum is spared and so despite the central nature of the cerebellar syndrome nystagmus is commonly absent. The pathology of superficial siderosis is of haemosiderin deposits along the subpial surfaces of the CNS and is a consequence of chronic or recurrent bleeding into the subarachnoid space. Superficial siderosis has been reported as a consequence of surgery, aneurysms, vascular malformations, spinal tumours, and traumatic root avulsions. Often the source of the haemorrhage cannot be identified, even at necropsy.

Magnetic resonance scanning has enabled the diagnosis to be made in vivo. The characteristic finding is a rim of marked hypointensity on T2 weighted images surrounding the brain stem, spinal cord, sylvian and interhemispheric fissures, and a few cortical sulci.

Occasionally the second and seventh cranial nerves are also involved. In addition to the marginal hypointensity created by the paramagnetic ferric ions, high signal in the adjacent cerebellar tissue, due to secondary gliosis, may be seen on T2 weighted MRI.<sup>2</sup>

The most striking and unique feature of the patient described was the extensive limb wasting and fasciculations with asymmetric weakness but preserved reflexes and an absence of sensory signs. These clinical findings, along with the neurophysiology, suggest an anterior horn cell pathology. In the review of Fearnley *et al* of 63 patients four had lower motor neuron involvement with absent or diminished reflexes thought to be secondary to arachnoiditis or radiculopathy. One patient had muscle wasting with brisk reflexes thought to be due to concurrent lower motor neuron pathology and myelopathy.<sup>1</sup> In our patient the duration of the symptoms and the lack of bulbar and pyramidal features were against this being a classic amyotrophic lateral sclerosis. It is more likely that superficial siderosis was the cause of our patient's anterior horn cell dysfunction and it is recognised that iron pigmentation may be found deep within the spinal cord and intraneuronal deposits have been described.<sup>1</sup> The clinical picture of anterior horn cell damage in superficial siderosis is of particular interest as in the review of Fearnley *et al* they note that although heavy haemosiderin deposition is recognised in the anterior horns of the spinal cord there is little in the way of neuronal fall out.

The predominance of CNS involvement and the paucity of lower motor neuron features in superficial siderosis has been the subject of several novel studies. Koeppen and Borke have shown that an intracisternal injection of red cells produces increased synthesis of ferritin in microglia, especially Bergmann glia in the cerebellum, and this binds with iron to form haemosiderin.<sup>3</sup> It is postulated that the glia and astrocytes of the central nervous system respond to the presence of haemoglobin whereas this process does not occur in Schwann cells of the peripheral nervous system. This is supported by the pathological finding that there is a sharp demarcation of haemosiderin deposition in the cranial nerves and spinal roots at the junction of the central glial and peripheral Schwann cell segments. Koeppen and Detinger have also suggested that the formation of haemosiderin is neuroprotective and it is once this protection has been exhausted that tissue damage occurs, thus it is not the haemosiderin which is toxic but the unbound iron.<sup>4</sup> There are no other case reports of superficial siderosis causing an anterior horn cell syndrome, posing the question of why our patient developed this combination. Whether our patient's presentation was due to anomalous intracellular processing or an unusual source of haemorrhage impacting on the spinal cord remains speculative. It is also possible that in our case the motor root exit zone is a site of iron deposition with resultant lower motor neuron pathology.

We think that our case of superficial siderosis with anterior horn cell dysfunction is unique, and raises interesting questions about pathological mechanisms in this rare disorder.

#### B Turner, A J Wills

Division of Clinical Neurology, University Hospital, Queen's Medical Centre, Nottingham NG7 2UH, UK

Correspondence to: Dr B Turner; msxbt@nottingham.ac.uk

#### References

- 1 Fearnley JM, Stevens JM, Rudge P. Superficial siderosis of the central nervous system. *Brain* 1995;**118**:1051–66.
- 2 Bracchi M, Savoiardo M, Triulzi F, *et al*. Superficial siderosis of the CNS: MR diagnosis and clinical findings. *Am J Neuroradiol* 1993;**14**:227–36.
- 3 Koeppen AH, Borke RC. Experimental superficial siderosis of the central nervous system. I. Morphological observations. *J Neuropathol Exp Neurol* 1991;**50**:579–94.
- 4 Koeppen AH, Detinger MP. Brain hemosiderin and superficial siderosis of the central nervous system. *J Neuropathol Exp Neurol* 1988;**47**:249–70.

#### Use of intrathecal baclofen for treatment of spasticity in amyotrophic lateral sclerosis

Baclofen, an agonist of  $\gamma$ -amino butyric acid, is one of the most effective drugs in the treatment of spastic movement disorders. However, higher oral dosages required for sufficient spasticity control are related to intolerable central side effects. In this situation, continuous intrathecal application of baclofen in microgram dosages has proved its efficacy in numerous series of patients with spasticity of cerebral or spinal origin.<sup>1–3</sup> Nevertheless, the use of intrathecally administered baclofen in amyotrophic lateral sclerosis, representing the most common degenerative motor neuron disease in adult life,<sup>4</sup> has been mentioned in only one short communication.<sup>5</sup> In this context our experience with intrathecal baclofen therapy is worth presenting. These two patients are the only ones we have treated in this manner and both experienced a marked improvement in their quality of life.

Patient 1, a 25 year old man, was previously reported in brief<sup>5</sup>; he is still alive and benefiting from intrathecal baclofen therapy. Five years ago he noticed progressive gait disturbance, weakness of his right foot, and painful nocturnal cramps in his legs. At that time he exhibited neurologically mild pareses of his right hand and foot, generalised fasciculations, and spasticity. Amyotrophic lateral sclerosis was diagnosed and oral antispastic treatment with baclofen and memantine was started. The patient remained ambulatory but an increase in spasticity due to the underlying disease required subsequent increases in dosage of baclofen. After 1 year a daily dose of 80 mg baclofen was reached but spasticity was no longer ameliorated. The patient was still able to walk a few steps with help but had to use a wheelchair otherwise. Furthermore, he complained of central side effects, such as weakness, daytime fatigue, and sleepiness. Intrathecal baclofen therapy was started, and at a daily dose of 160  $\mu$ g the patient showed only minimal clinical signs of spasticity. He was able to walk at large without help and could even climb stairs. Spasticity increased during the next 21 months; however, by adjustment of the daily dosage up to 540  $\mu$ g the patient remained able to walk without additional devices and was capable of caring for himself. Then increasing pareses due to progression of amyotrophic lateral sclerosis came into prominence, and the patient is tetraparetic to a high degree depending on special care. Attempts to reduce baclofen dosage led to a significant increase in spasticity and painful muscle cramps, resulting in substantial discomfort. Thus a daily dose of 540  $\mu$ g baclofen was maintained.

Due to bulbar involvement the patient was supplied with a nasofacial mask for non-invasive intermittent ventilation to alleviate