

Authors:

John Chae, MD, ME
 Zi-Ping Fang, PhD
 Maria Walker, MSE
 Soheyl Pourmehdi, PhD
 Jayme Knutson, MSE

Affiliations:

From the Center for Physical Medicine and Rehabilitation and Department of Biomedical Engineering, Case Western Reserve University (JC); the Departments of Physical Medicine and Rehabilitation and Orthopedics, MetroHealth Medical Center, (JC); the Cleveland Veterans Affairs Functional Electrical Stimulation Center, Cleveland Veterans Affairs Medical Center (JC); and the NeuroControl Corporation (ZF, MW, SP, JK), Cleveland, Ohio.

Disclosures:

Supported in part by Grants 1 R43 NS36484-01A1 from the National Institute of Neurological Diseases and Stroke, 1 R29 HD35616-01 from the National Institute of Child Health and Human Development, and M01RR00080 (General Clinical Research Center) from the National Center for Research Resources.

Correspondence:

All correspondence and requests for reprints should be addressed to John Chae, MD, ME, Center for Physical Medicine and Rehabilitation, Case Western Reserve University, MetroHealth Medical Center, 2500 MetroHealth Drive, Cleveland, OH 44109.

0894-9115/01/8011-0842/0
American Journal of Physical Medicine & Rehabilitation
 Copyright © 2001 by Lippincott Williams & Wilkins

Case Series

Intramuscular Electromyographically Controlled Neuromuscular Electrical Stimulation for Ankle Dorsiflexion Recovery in Chronic Hemiplegia

ABSTRACT

Chae J, Fang Z-P, Walker M, Pourmehdi S, Knutson J: Intramuscular electromyographically controlled neuromuscular electrical stimulation for ankle dorsiflexion recovery in chronic hemiplegia. *Am J Phys Med Rehabil* 2001;80:842–847.

We report three cases of survivors of chronic stroke treated with active repetitive movement training of the paretic ankle dorsiflexors mediated by intramuscular electromyographically controlled neuromuscular electrical stimulation (NMES). These case reports demonstrate the feasibility of using intramuscular electromyographically controlled NMES for facilitating ankle dorsiflexion recovery among survivors chronic stroke with moderate hemiplegia. Relevant issues for clinical implementation and future investigations are reviewed.

Keywords: Functional Electrical Stimulation, Foot Drop, Hemiplegia, Stroke Recovery, Electromyographic Control

Cyclic neuromuscular electrical stimulation (NMES) has been shown to enhance the motor recovery of stroke survivors.^{1–3} However, studies have failed to demonstrate that improvements in motor impairment associated with cyclic NMES translate into any substantial improvements in activities of daily living. This may be caused by the fact that cyclic NMES requires no cognitive investment from patients, and improvements in motor impairment are generally modest. Several studies have evaluated the clinical efficacy of electromyographically (EMG) mediated NMES, which adds a cognitive component to NMES therapy.^{4–7} EMG-mediated NMES facilitates patterned, repetitive, voli-

tionally mediated exercises and provides cutaneous, proprioceptive, and electrical stimulation feedback time-locked to each attempted movement. In one small randomized clinical trial, significant improvement in motor impairment was associated with significant improvement in activities of daily living.⁶ However, commercially available EMG-mediated NMES systems utilize transcutaneous electrodes and provide only EMG-triggered NMES. These systems have a number of limitations. First, many stroke survivors cannot tolerate the cutaneous pain of transcutaneous stimulation.^{1,8} Second, transcutaneous recording electrodes lack sufficient selectivity to differentiate EMG signals from adjacent muscles.⁹⁻¹¹ Third, transcutaneous recording electrodes lack sufficient sensitivity to detect weak EMG signals from severely paretic muscles of stroke survivors.^{6,9-11} Fourth, skilled individuals are needed to place transcutaneous recording and stimulating electrodes on the patient each day to ensure repeatability and proper coupling of the volitionally activated EMG signal and NMES. Finally, EMG-triggered systems require minimal cognitive input; a patient's EMG input is required to initiate the stimulation, but additional input is not required to maintain or terminate the stimulation.

To address these limitations, a percutaneous, intramuscular EMG-controlled NMES device has been developed (NeuroControl Corporation, Cleveland, OH). Intramuscular NMES induces less pain than transcutaneous NMES,¹² and intramuscular electrodes are more sensitive and selective than transcutaneous electrodes in detecting EMG signals from adjacent muscles.^{9-11,13} Because the electrodes are percutaneously implanted into the motor points of the target muscles, skilled individuals are not needed to administer and remove the device, and coupling of the EMG signal and NMES is reproducible. Finally, EMG con-

trolled NMES requires that the patient initiate, maintain, and terminate his or her EMG signals to initiate, maintain, and terminate the NMES. This additional cognitive investment from the patient may further facilitate motor relearning. This report assesses the clinical feasibility of implementing intramuscular EMG-controlled NMES to facilitate recovery of ankle dorsiflexion among three survivors of chronic stroke.

CASE REPORTS

Case 1.

Case 1 is a 58-yr-old man who sustained a right hemisphere cortical infarct 1.3 yr before treatment entry. The patient exhibited a mixed pattern of extensor synergy and isolated movement patterns in the left lower limb. At initial evaluation, the mean dorsiflexion torque was 6.3 N-m or 26% of the normal side. Lower-limb Fugl-Meyer¹⁴ score was 24 out of a possible 34 and ankle Modified Ashworth¹⁵ score was 1+. The patient was a community ambulator, but required a molded ankle-foot orthosis (AFO) to help his toes clear during swing phase and to prevent genu recurvatum during midstance. He required a straight cane for balance during community ambulation.

The intramuscular EMG-controlled NMES stimulator is an experimental device. Therefore, the treatment and follow-up protocols were reviewed and approved by the Institutional Review Board and the patient signed informed consent. The patient received a total of six electrodes, four in the tibialis anterior and two in the peroneal longus. The peroneal longus electrodes and two of the tibialis anterior electrodes were used for stimulation. The remaining two tibialis anterior electrodes were used for recording EMG signals in a bipolar configuration. The percutaneous electrodes and implantation technique have been described in

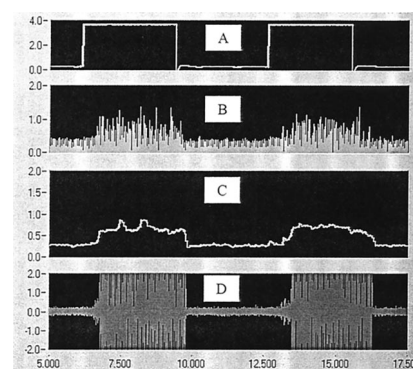


Figure 1: An audible cue (A) instructs the patient to initiate, maintain, and terminate their electromyographic signal from the paretic muscle. The electromyographic signal is rectified (B) and integrated to generate a command signal (C). If the command signal exceeds a preset threshold, neuromuscular electrical stimulation is provided (D).

prior reports.^{12,16} A full report of the design and engineering specifications of the stimulator will be presented in a separate study (Fang et al., unpublished data, 2001). Briefly, the stimulator detects a volitionally activated EMG signal that is rectified and integrated. If the processed signal exceeds a preset threshold, the stimulator emits a train of pulses. As long as the patient maintains the EMG signal, the train of pulses continues. The large stimulation artifact and evoked EMG signal are blocked by a sampling gate and thus does not adversely affect the operation of the circuit. The patient was able to initiate, maintain, and terminate the NMES volitionally (Fig. 1). The patient tolerated the NMES without discomfort.

The patient was prescribed 1 hr of ankle dorsiflexion exercises per day for a total of 4 wk. Exercises were performed in a seated position with the hip flexed to 90 degrees, knee flexed to 60 degrees, and ankle in 30 degrees of plantarflexion. Duty cycle was 10 sec on and 10 sec off with 2 sec of on ramp and off ramp each. The principal outcome measure was volitional isometric torque measurements of ankle dorsiflexion. In addi-

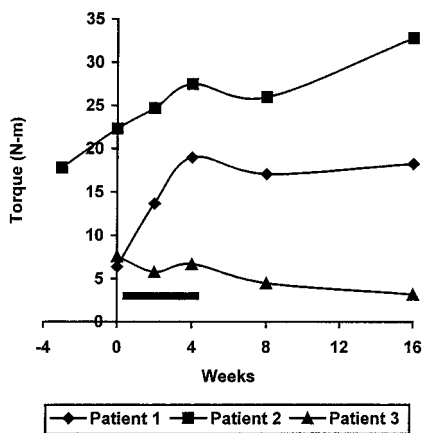


Figure 2: Isometric ankle dorsiflexion torques. Patients 1 and 2, with mild to moderate lower-limb paresis, experienced marked improvement in isometric ankle dorsiflexion torques during the treatment phase. After completion of treatment, both patients experienced mild decline. However, patient 1 improved thereafter, and patient 2 remained stable. Patient 3, with severe lower-limb paresis, exhibited no improvements. *Dark bar* indicates treatment phase.

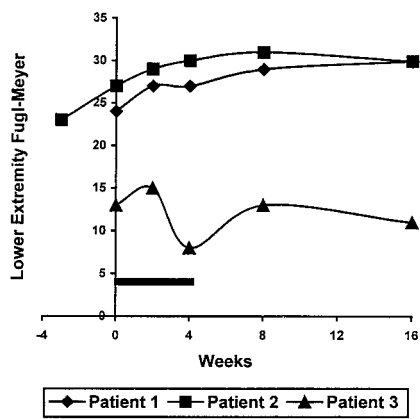


Figure 3: Lower-limb Fugl-Meyer scores. Patients 1 and 2, with mild to moderate lower-limb paresis, experienced modest recovery during the treatment phase that was maintained at follow-up. Patient 3, with severe lower-limb paresis experienced no gains. *Dark bar* indicates treatment phase.

tion, the patient was assessed with the lower-limb component of the Fugl-Meyer Motor Assessment and the Modified Ashworth Scale. The patient was assessed at baseline, at mid-point of treatment (2 wk), at the completion of treatment (4 wk), and at 4 and 12 wk after completion of treatment. In view of the exploratory nature of the intervention, formal assessment of gait kinematics was not pursued. However, the patient provided subjective reports of changes in

his ambulation function during the intervention protocol. Compliance was monitored with an electronic compliance monitor built into the stimulator.

The patient completed all 28 hr of prescribed stimulation. Electrodes were removed fully intact at the completion of treatment without incidence of infection or complications. Significant improvement in ankle dorsiflexion torque was noted during the treatment phase (Fig. 2). There was a slight worsening of the ankle dorsiflexion torque 4 wk after completion of treatment. However, by the third month ankle dorsiflexion

torque had recovered to 77% of the normal side. The patient exhibited modest improvements in the lower-limb Fugl-Meyer scores during the treatment and follow-up phases (Fig. 3). Modified Ashworth score improved steadily from 1+ at treatment entry to 0 at the final follow-up evaluation (Table 1). Functionally, the patient began to ambulate at home without his molded AFO. However, in the community he continued to require the AFO and a cane because of an inability to maintain long-term ankle dorsiflexion and persistent genu recurvatum.

Case 2.

Case 2 is a 45-yr-old man who sustained a right intracerebral hemorrhage secondary to a rupture arteriovenous malformation requiring craniotomy and evacuation 3.4 yr before treatment entry. At the time of treatment entry, persistent neurologic impairments included compensated left neglect, left hemisensory deficit, and spastic left hemiparesis. Left lower-limb movement demonstrated a mixed pattern of extensor synergy and isolated movement patterns. He was a community ambulator, but required a molded AFO to help clear his toes during swing phase. He did not require additional ambulation aids. Clinically, he demonstrated only slight volitional dorsiflexion of the left ankle. Initial lower-limb Fugl-Meyer score was 23 with

TABLE 1

Levels of spasticity as measured by the Modified Ashworth Scale

Subject	Pretreatment	2-Wk Treatment	Posttreatment (4-wk)	4-Wk Follow-Up	12-Wk Follow-Up
1	1+	1	0	0	0
2	3, 1 ^a	1+	1+	1+	1
3	1+	1+	2	2	1

^aSubject 2 had an Ashworth score of three at initial evaluation. However, because of the inability to detect a sufficient electromyographic signal, the patient received a 3-wk course of cyclic neuromuscular electrical stimulation before receiving electromyographically controlled NMES. The Ashworth score was a one prior to starting electromyographically controlled neuromuscular electrical stimulation.

an ankle Modified Ashworth score of a 3 and mean ankle dorsiflexion torque of 17.8 N-m or 41% of the normal side.

The patient signed informed consent before implantation. The patient received six percutaneous electrodes as described for case 1. During initial evaluation, volitionally activated EMG signal was not strong enough to activate the EMG-controlled stimulator. Thus, the patient received a 3-wk trial of cyclic intramuscular NMES of the tibialis anterior and peroneal longus. At the follow-up visit, lower-limb Fugl-Meyer score increased to 27, Modified Ashworth score decreased to 1, and mean ankle dorsiflexion torque increased to 22.3 N-m. A volitionally activated EMG signal was now strong enough to control the stimulator, and the patient was sent home with EMG-controlled NMES.

Exercise, follow-up, and evaluation protocols were identical to patient 1. However, the patient completed only 8 of 28 prescribed hours of EMG-controlled NMES during the 4-wk treatment period. All electrodes were removed fully intact without incidence of infection or complications after completion of treatment. The patient experienced substantial improvements in ankle dorsiflexion torques during the treatment phase (Fig. 2). There was a slight decrease in torque at the 4-wk posttreatment evaluation, but this increased to approximately 75% of his normal side by the 3-mo follow-up evaluation. He experienced modest improvements in the lower-limb Fugl-Meyer score without evidence of downward trend after completion of treatment (Fig. 3). Modified Ashworth score remained low throughout the treatment and follow-up periods (Table 1). By the end of the treatment phase, the patient experienced sufficient recovery of his ankle dorsiflexion that he began to ambulate without his AFO at all times in his home and for short distances in the community. This functional improvement was

maintained for up to 3 mo after completion of treatment.

Case 3.

Case 3 is a 50-yr-old man who sustained a left temporal/parietal and basal ganglia hemorrhage requiring craniotomy and evacuation 3.1 yr before treatment entry. Functionally, he ambulated in the community with a molded AFO and a narrow-based four-point cane. His gait exhibited minimal hip and knee flexion requiring circumduction and associated hip hike to clear the toes during swing phase. Genu recurvatum was noted during midstance. At treatment entry, right lower-limb movement was predominantly in an extensor synergy pattern with some flexor synergy. Volitional activation of the tibialis anterior was present within the context of flexor synergy. Mean ankle dorsiflexion torque was 7.6 N-m or 28% of the normal side. Lower-limb Fugl-Meyer score was 13, and Modified Ashworth score was 1+. He received botulinum toxin A injections to his gastrocnemius complex every 2–3 mo to reduce his plantar flexion tone, which was necessary for community ambulation. He received a botulinum toxin injection 2 wk before beginning the stimulation protocol.

The patient signed informed consent and six electrodes were implanted as described for cases 1 and 2. The patient completed all 28 prescribed hours of treatment and followed the same follow-up and evaluation protocols described for cases 1 and 2. At the 2-wk evaluation, there was a slight improvement in the Fugl-Meyer score (Fig. 3), but there was also a slight decrease in mean ankle dorsiflexion torque (Fig. 2). There was no change in the Modified Ashworth score. By the end of the stimulation period (4 wk), ankle dorsiflexion torque improved slightly, but the Fugl-Meyer score decreased substantially and Modified Ashworth score showed interval worsening of

spasticity. All electrodes were removed fully intact at the end of treatment without incidence of infection or complications. Four weeks after completion of treatment or 10 wk after the last botulinum toxin injection, ankle dorsiflexion torque worsened, but Fugl-Meyer score returned to baseline. Modified Ashworth score remained at 2. At this time, the patient felt that the therapeutic effect of the botulinum toxin had declined substantially and he received another 300 U of botulinum toxin A into his spastic gastrocnemius complex. The subject was reevaluated at 12 wk postimplantation or 8 wk after his most recent botulinum toxin injection. He reported interval improvement in function after the botulinum toxin injection. However, he also reported that the therapeutic effect of the botulinum toxin was again beginning to decline. At this final follow-up evaluation, modest improvement in spasticity was noted, but both Fugl-Meyer score and mean ankle dorsiflexion torque all declined slightly. The patient was not able to ambulate without his AFO at any time during the stimulation or follow-up periods. The patient reported no appreciable benefit from EMG-controlled NMES.

DISCUSSION

The rationale for using NMES for motor relearning in hemiplegia is derived from basic and clinical studies that demonstrate that the mammalian brain has significant potential for motor neuroplasticity after injury and that this plasticity is facilitated by goal oriented active repetitive movement training.^{17–21} Motor relearning may be maximized by coupling afferent feedback during contraction with patient intent. Repetitive movement training mediated by cyclic NMES requires no cognitive or efferent investment by the patient. Thus, it is not surprising that for stroke survivors with some volitional activation of the hand and wrist mus-

cles, volitional active repetitive movement training is superior to cyclic NMES in facilitating motor recovery.²² EMG-controlled NMES combines cognitive intent with motor activation and afferent feedback. This report presents our initial clinical experience with three survivors of chronic stroke treated with active repetitive movement training of the paretic ankle dorsiflexors mediated by intramuscular EMG-controlled NMES.

Two patients with moderate deficits benefited from EMG-controlled NMES whereas the one patient with severe deficits did not. This is consistent with two recent randomized clinical trials of transcutaneous cyclic NMES that demonstrated that the therapeutic effects of NMES are greatest with a milder degree of hemiplegia.^{2,3} Even with non-NMES active repetitive movement interventions, the therapeutic benefit seems to be greatest with less severe hemiplegia.²³ It is reasonable to conclude that EMG-controlled NMES may also be most appropriate for persons with mild to moderate hemiparesis. However, future investigations should determine whether severely impaired patients can benefit from EMG-controlled NMES by defining the optimal treatment dosage and duration as a function of degree of motor impairment.

This report included only survivors of chronic stroke to provide reasonable assurance of baseline neurologic stability. The shortest duration from stroke onset to treatment entry was 1.3 yr. From a statistical point of view, spontaneous stroke recovery is essentially complete by 6 mo.²⁴ Thus, it is highly unlikely that the observed improvements in motor status in this report is caused by spontaneous recovery. If the observed improvements in this chronic stroke population are confirmed in future studies, EMG-controlled NMES may be even more effective among survivors of acute stroke, in whom there is a theoretically greater potential for neuroplasticity. Nevertheless, this was not a

formal blinded study and placebo effect and evaluator bias cannot be ruled out. Future investigations with survivors of either acute or chronic stroke should include a control group to ensure sufficient scientific rigor.

The clinical decision to use percutaneous, intramuscular electrodes instead of transcutaneous NMES electrodes must weigh the benefits and limitations of each type of electrodes within the context of the clinical application. The implementation of percutaneous electrodes is by definition invasive. The procedure and hardware are more costly, and the skin must be examined frequently and properly maintained. Although the electrode failure rate is low during the first few months of postimplantation, the cumulative 1-yr failure rate can vary between 56% and 80%,^{16,25} which limits the use of percutaneous electrodes to short-term applications (< 3 mo). Other potential complications of using percutaneous intramuscular electrodes include formation of granulomas from retained electrode fragments and electrode-related infections, which are treated with oral antibiotics or minor outpatient surgical procedure. Based on 20 yr of experience in our laboratory with people with spinal cord injuries, strokes, or traumatic brain injuries, incidents of granuloma formation and electrode infection occurred at a rate of one per 5.5 yr of research-subject participation. Incidents that required outpatient surgical treatment occurred at a rate of one per 18.5 yr of subject participation.

In summary, these case reports demonstrate the feasibility of using intramuscular EMG-controlled NMES to facilitate ankle dorsiflexion motor relearning among survivors of chronic stroke with moderate hemiplegia. An intramuscular system may maximize reproducibility of stimulation, ease administration and removal, and enhance patient compliance with NMES treatment protocols. An EMG-controlled

system in which subjects initiate, maintain, and terminate their EMG signals to initiate, maintain, and terminate the NMES increases cognitive investment from patients. An intramuscular system provides selective recording of weak EMG signals and muscle specific stimulation without the painful sensation of transcutaneous stimulation. Patients in this report tolerated the implantation procedure and the NMES without difficulty or discomfort. They were able to appropriately control the initiation, maintenance, and termination of NMES. All electrodes were removed fully intact without incidence of infection or complications. Two subjects with moderate lower-limb hemiplegia benefited from intramuscular EMG-controlled NMES, whereas one patient with severe lower-limb hemiplegia did not benefit. Controlled studies are needed to confirm and expand on the findings of this report. Future studies should assess survivors of both chronic and acute stroke. Assessment measures should include the full spectrum of clinical outcomes, including impairment, activity, participation, and quality of life. Dose effect should be elucidated and prescriptive parameters for specific levels of impairment should be defined. Finally, evidence for neuroplasticity should be pursued to elucidate basic mechanisms and refine and optimize the treatment paradigm.

REFERENCES

1. Chae J, Bethoux F, Bohinc T, et al: Neuromuscular stimulation for upper extremity motor and functional recovery in acute hemiplegia. *Stroke* 1998;29:975-79
2. Sonde L, Gip C, Ferneus S, et al: Stimulation with low frequency (1/7 Hz) transcutaneous electric nerve stimulation (Low-TENS) increases motor function of post-stroke hemiparetic arm. *Scan J Rehab Med* 1998;30:95-9
3. Powell J, Pandyan D, Granat M, et al: Electrical stimulation of wrist extensors in poststroke hemiplegia. *Stroke* 1999;30:1384-9

4. Fields R: Electromyographically triggered electric muscle stimulation for chronic hemiplegia. *Arch Phys Med Rehabil* 1987;68:407-14
5. Kraft G, Fitts S, Hammond M: Techniques to improve function of the arm and hand in chronic hemiplegia. *Arch Phys Med Rehabil* 1992;73:220-7
6. Francisco G, Chae J, Chawla H, et al: Electromyogram-triggered neuromuscular stimulation for improving the arm function of acute stroke survivors: a randomized pilot study. *Arch Phys Med Rehabil* 1998;79:570-5
7. Hansen G: EMG-controlled functional electrical stimulation of the paretic hand. *Scand J Rehabil Med* 1979;11:189-93
8. Baker LL, Bowman BR, McNeal DR: Effects of waveform on comfort during neuromuscular electrical stimulation. *Clin Orthop Rel Res* 1988;233:75-85
9. Giroux B, Lamontagne M: Comparison between surface electrodes and intramuscular wire electrodes in isometric and dynamic conditions. *Electromyogr Clin Neurophysiol* 1990;30:397-405
10. Perry J, Easterday CS, Antonelli D: Surface versus intramuscular electrodes for electromyography of superficial and deep muscles. *Phys Ther* 1981;61:7-15
11. Benhamou MA, Revel M, Vallee C: Surface electrodes are not appropriate to record selective myoelectric activity of splenius capitis muscles in humans. *Exp Brain Res* 1995;105:432-8
12. Chae J, Hart R: A comparison of discomfort associated with surface and percutaneous intramuscular electrical stimulation for persons with chronic hemiplegia. *Am J Phys Med Rehabil* 1998;77:516-22
13. Chae J, Hart R, Knutson J, et al: Selectivity and sensitivity of intramuscular and transcutaneous electromyography electrodes. *Am J Phys Med Rehabil* 2001;80:374-379
14. Fugl-Meyer A, Jaasko L, et al: The post-stroke hemiplegic patient: a method for evaluation of physical performance. *Scand J Rehab Med* 1975;7:13-31
15. Bohanan RW, Smith MB: Interrater reliability of Modified Ashworth Scale of muscle spasticity. *Phys Ther* 1987;67:206-7
16. Memberg WD, Peckham PH, Thrope GB, et al: An analysis of the reliability of percutaneous intramuscular electrodes in upper extremity FNS applications. *IEEE Trans Biomed Eng* 1993;1:126-32
17. Feeney D, Gonazalez A, Law W: Amphetamine, haloperidol and experience interact to affect rate of recovery after motor cortex injury in rats. *Science* 1982;217:855-7
18. Nudo RJ, Wise BM, SiFuentes F, et al: Neural substrates for the effects of rehabilitative training on motor recovery after ischemic infarct. *Science* 1996;272:1791-4
19. Aisen ML, Drebs HI, Hogan N, et al: The effect of robot-assisted therapy and rehabilitative training on motor recovery following stroke. *Arch Neurol* 1997;54:443-6
20. Butefisch C, Hummelsheim, Denzler P, et al: Repetitive training of isolated movements improves the outcome of motor rehabilitation of the centrally paretic hand. *J Neurol Sci* 1995;130:59-68
21. van der Lee JH, Wagenaar RC, Lankhorst GJ, et al: Forced use of the upper extremity in chronic stroke patients: results from a single-blinded randomized clinical trial. *Stroke* 1999;30:2368-75
22. Hummelsheim H, Maier-Loth ML, Eickhof C: The functional value of electrical muscle stimulation for the rehabilitation of the hand in stroke patients. *Scand J Rehab Med* 1997;29:3-10
23. Sunderland A, Tinson DJ, Bradley EL, et al: Enhanced physical therapy improves recovery of arm function after stroke. A randomised controlled trial. *J Neurol Neurosurg Psychiatry* 1992;55:530-5
24. Jorgensen H, Nakayama H, Raaschou H, et al: Outcome and time course of recovery in stroke: part II. Time course of recovery. The Copenhagen Stroke Study. *Arch Phys Med Rehabil* 1995;76:406-12
25. Smith BT, Betz RR, Mulcahey MJ, et al: Reliability of percutaneous intramuscular electrodes for upper extremity functional electrical stimulation in adolescents with C5 tetraplegia. *Arch Phys Med Rehabil* 1994;75:939-45

Letters to the Editor

The *American Journal of Physical Medicine & Rehabilitation* welcomes letters to the Editor that objectively critique information appearing in the *Journal*. Letters should be limited to a maximum of 500 words (approximately two double-spaced pages). No unsigned letters will be accepted for publication. If a letter is accepted for publication, a copy will be sent to the principal author of the material being discussed, who will have an opportunity to submit a response for publication. All letters are subject to editing by the Editor.