

# Paradoxical Brain Embolism From Thrombus Associated With Vena Caval Filter in a Patient With Cancer

Catalina Ionita, MD

Pierre Giglio, MD

Eugene Isayev, MD

Ronald Alberico, MD

Patrick Pullicino, MD, PhD

## ABSTRACT

A 71-year-old man experienced sudden onset of hemiparesis and aphasia. He had a 4-month history of gallbladder cholangiocarcinoma, complicated with a postoperative deep-vein thrombosis (DVT) that necessitated a vena caval filter placement. Diffusion-weighted magnetic resonance imaging of the brain showed multiple hyperintense foci. Magnetic resonance spectroscopy was compatible with cerebral infarction. Abdominal computed tomography showed a thrombus in the inferior vena cava extending through the filters. A transcranial Doppler bubble study revealed the presence of a right-to-left shunt. Paradoxical cerebral embolism must be considered in patients with DVT who have new onset neurologic deficits even in the presence of a caval filter.

Key words: Cancer, intracaval filter, right-to-left shunt, paradoxical emboli, transcranial Doppler, bubble study.

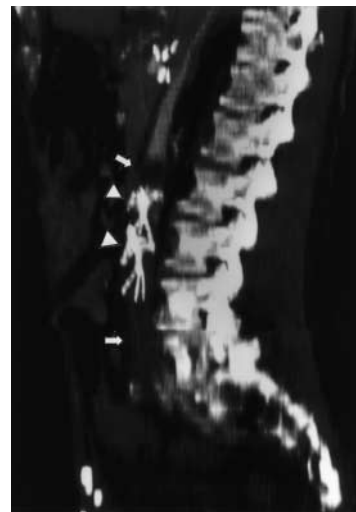
Ionita C, Giglio P, Isayev E, Alberico R, Pullicino P.  
Paradoxical brain embolism from thrombus associated  
with vena caval filter in a patient with cancer.  
J Neuroimaging 2002;12:69-71.

## Case Presentation

A 71-year-old right-handed white man was admitted to the hospital with lightheadedness and vague abdominal pain. He had a gallbladder cholangiocarcinoma with liver metastases surgically resected 3 months previously, followed by 4 cycles of chemotherapy. He subsequently developed recurrent intra-abdominal abscesses, which were drained under computed tomography (CT) guidance. During the chemotherapy, he developed a left iliofemoral vein thrombosis. Two Simon Nitinol filters were placed in the inferior vena cava, and the patient was started on a full anticoagulation dose of subcutaneous enoxaparin sodium, 1 mg/kg twice a day, as an outpatient. Enoxaparin was discontinued on admission because of the possibility of intra-abdominal hemorrhage. Twelve hours later,

the patient started to have intermittent speech difficulty and generalized tremors. The next day, he developed sudden right-sided weakness with language difficulty. Neurologic examination revealed an awake and alert patient, with decreased fluency of spontaneous speech, frequent naming errors, and difficulties in performing cross-body commands, but with comprehension and repetition preserved. He had a right homonymous hemianopsia, normal fundi, and extraocular movements. He had a severe right facial droop. He had a hypotonic right hemiparesis more prominent in the arm and distally, with a right Babinski sign. Finger-nose test showed bilateral dysmetria. Laboratory investigations showed a white cell count of  $23.5 \times 10^3/L$ , hemoglobin of 10.7 g/dL, and platelet count of  $428 \times 10^3/L$ . The chemistry was initially normal, but 2 days later the patient developed acute renal failure with a blood urea nitrogen of 80 mg/dL, creatinine of 4.3 mg/dL, potassium of 5.7 mEq/L, and proteinuria > 300 mg/L. Blood and urine cultures were negative. Coagulation tests showed a prothrombin time of 17.6 seconds, activated partial thromboplastin time of 39 seconds, fibrinogen of 229 mg/dL, antithrombin III level of 59% (normal 80-120), protein C level of 32% (normal 65-129), free protein S level of 32% (normal 57-120), and D-dimer positive. A transthoracic echocardiogram was normal.

A CT scan of the abdomen and pelvis was negative for abscesses or fluid. A sagittal reformat revealed an inferior vena cava thrombus extending caudal and cephalad to both filters, with persisting thrombus in the iliac veins bilaterally and in the femoral vein on the right (Fig 1). Diffusion-weighted and

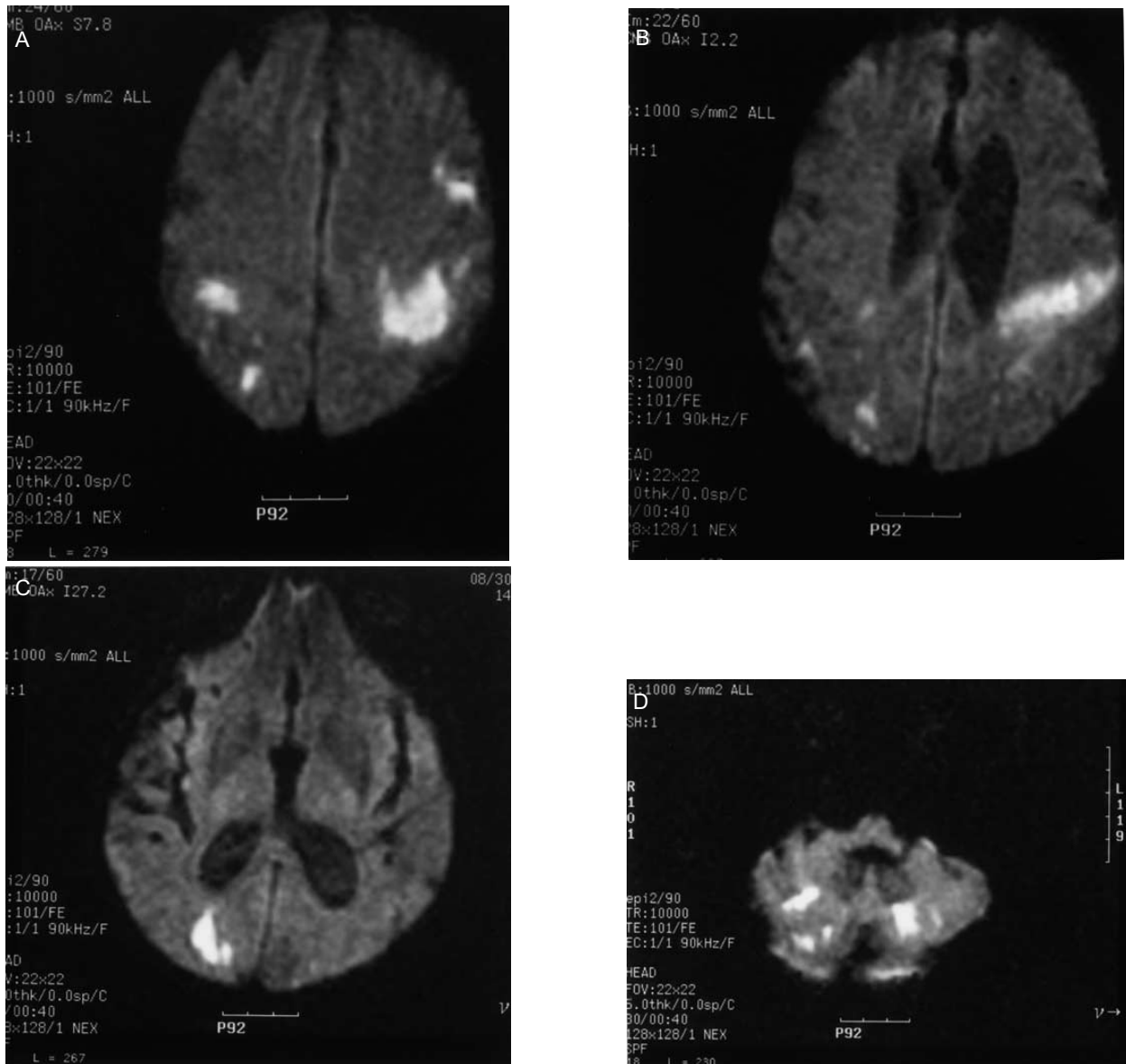


**Fig 1.** Computed tomography scan of the abdomen-sagittal reformat showing the 2 filters (triangles) and the intracaval thrombus hypodensity (arrows) extending caudal and cephalad to both filters.

Received March 19, 2001, and in revised form June 11, 2001.  
Accepted for publication July 9, 2001.

From the Department of Neurology, Buffalo General Hospital, Buffalo, New York (CI, PG, EI, PP); and the Department of Radiology, Roswell Park Cancer Institute, Buffalo, New York (RA).

Address correspondence to Dr Pullicino, Neuroscience Department, UMDNJ, 185 South Orange Avenue, Newark, NJ 07103. E-mail: pullic@umdnj.edu.

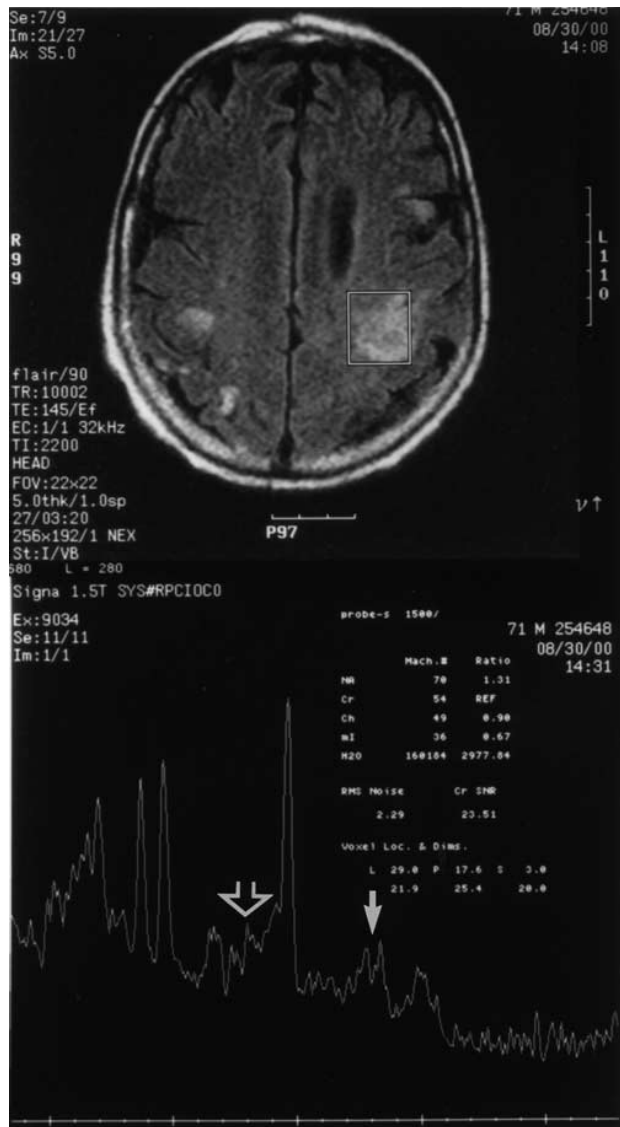


**Fig 2.** Diffusion-weighted magnetic resonance imaging of the brain showing multiple hyperintense foci, in multiple vascular territories, consistent with multiple embolic infarcts.

flair magnetic resonance imaging of the brain showed multiple foci of acute infarction, in multiple vascular territories, consistent with embolic infarctions (Fig 2). The magnetic resonance spectroscopy (STEAM, TR = 1500 ms, TE = 35 ms) showed a small doublet peak at 1.33 ppm consistent with lactate. The glutamine/glutamate peak was slightly increased. The spectrum was consistent with early ischemia and not suggestive of abscess or tumor (Fig 3). Insonation of the right middle cerebral artery following injection of microbubbles into a forearm vein revealed multiple microembolic signals about 10 seconds after injection on 2 separate occasions, which indicated the presence of a right-left shunt.

### Discussion

The most likely source of the multiple cerebral emboli in this patient was the vena caval thrombus because the patient had a right-to-left shunt and thrombus was detected cephalad to both vena caval filters. Intracaval filters do not provide full protection against further embolic events; the open architecture of both Greenfield and Simon Nitinol filters provides patency at the expense of allowing the passage of emboli up to 3 mm in diameter. In the presence of a right-to-left shunt, small emboli that could lodge asymptotically in the lungs may go to the brain and cause infarctions.<sup>1-4</sup> The Simon Nitinol filter is



**Fig 3.** Magnetic resonance spectroscopy of the brain showing a small doublet lactate peak (arrows) and the prominent glutamine/glutamate peak (triangles). N-acetyl aspartate/creatine and choline/creatine levels are near normal. This spectrum supports the diagnosis of acute stroke.

a larger filter than the Greenfield filter and is often used for patients with a vena cava diameter greater than 8 mm.

There is increasing evidence that open architecture caval filters cannot be totally relied on for protection from pulmonary embolism, and our case demonstrates this is also true for stroke. Neurologists should be aware of this. In a patient with unexplained acute neurological symptoms, the presence of a

vena caval filter should suggest the possibility of paradoxical embolism and trigger a search for a patent foramen ovale.

We recommend CT of the abdomen and either transesophageal echocardiography<sup>5,6</sup> or transcranial Doppler bubble study<sup>7</sup> in any patient with an open type of intracaval filter who develops new neurologic symptoms. Cancer patients, particularly those with gastrointestinal adenocarcinoma, may have a hypercoagulable state and may be especially prone to this complication. These patients should probably also be screened for a right-to-left shunt presence, even if they do not have neurological symptoms, and especially if they have a deep-vein thrombosis or evidence of thrombosis. In our case, the presence of an extensive vena caval thrombus suggested that this thrombus was actually progressing, in spite of anticoagulation. Although the neurological symptoms developed 12 hours after the enoxaparin was stopped, since the biological effect of 1 mg/kg dose of enoxaparin lasts 3 to 5 days, and the therapeutic anticoagulant level lasts 12 to 16 hours, stopping of enoxaparin was unlikely to have been the cause of the thrombus. The hypercoagulable state associated with cancer is frequently resistant to anticoagulation and recurrent embolism, pulmonary or cerebral, is still possible, even with a vena caval filter placement. Vena caval ligation may be indicated to prevent recurrent emboli.<sup>8,9</sup>

## References

1. Greenfield LJ, Proctor MC, Salna A. Clinical results of Greenfield filter use in patients with cancer. *Cardiovasc Surg* 1997;5:145–149.
2. Dalman R, Kohler TR. Cerebrovascular accident after Greenfield filter placement for paradoxical embolism. *J Vasc Surg* 1989;9:452–454.
3. Lemmon GW, Litscher LJ. Incomplete caval protection following a suprarenal filter placement. *Angiology* 2000;51:155–159.
4. Cohen J, Tenenbaum N, Citron M. Greenfield filter as primary therapy for deep venous thrombosis and (or) pulmonary embolism in patient with cancer. *Surgery* 1991;109:12–15.
5. Blackshear JL. Transesophageal echocardiography in source of embolism evaluation. *Mayo Clin Proc* 1999;74:941–945.
6. Autore C, Cartoni D, Piccininno M. Multiplane transesophageal echocardiography and stroke. *Am J Cardiol* 1998;81(12A):79G–81G.
7. Droste DW, Reisener M, Kemeny V, et al. Contrast TCD for right-to-left shunts. *Stroke* 1999;30:1014–1018.
8. Silverstein RL, Nachman R. Cancer and clotting—Trousseau's warning. *N Engl J Med* 1992;327:1163–1164.
9. Whitehill TA. Caval interruption methods: comparison of option. *Sem Vasc Surg* 1996;9:59–69.