

Extracranial-Intracranial Vein Graft Bypass for Giant Intracranial Aneurysm Surgery for Pediatric Patients: Two Technical Case Reports

Y. Jonathan Zhang, M.D., Daniel L. Barrow, M.D.,
Arthur L. Day, M.D.

Department of Neurosurgery (YJZ, DLB), Emory University School of Medicine, Atlanta, Georgia, and Department of Neurosurgery (ALD), University of Florida School of Medicine, Gainesville, Florida

OBJECTIVE AND IMPORTANCE: Herein we describe two cases of extracranial-intracranial vein graft bypasses for the treatment of giant intracranial aneurysms in prepubertal pediatric patients. One patient is, we think, the youngest patient reported in the literature to have been successfully treated in such a manner, with a good long-term outcome. Such grafts seem to enlarge longitudinally during the growth spurt, making such techniques reasonable long-term therapeutic options for the management of complex intracranial aneurysms in pediatric patients.

CLINICAL PRESENTATION: Patient 1, a 13-year-old boy, presented with headaches and rapidly progressive right cavernous sinus syndrome. Computed tomography and cerebral angiography revealed a giant, fusiform, right intracavernous internal carotid artery aneurysm. Patient 2, a 23-month-old girl, was discovered to harbor an asymptomatic, recurrent, giant, fusiform, left M1 middle cerebral artery aneurysm 1 year after presenting with seizures related to subarachnoid hemorrhage from the aneurysm, for which she had been treated with clipping and an M2-M2 anastomosis.

INTERVENTION: Both patients underwent craniotomies, with sacrifice of the proximal parent vessel (the distal cervical internal carotid artery and the proximal middle cerebral artery, respectively), combined with cerebral revascularization through extracranial-intracranial saphenous vein bypass grafts. Both patients experienced excellent long-term clinical outcomes, have undergone significant growth, and exhibit excellent long-term graft patency and aneurysm obliteration.

CONCLUSION: These two cases highlight the safety and efficacy of extracranial-intracranial vein graft bypasses among prepubertal pediatric patients. The indications for bypass procedures to treat giant intracranial aneurysms are discussed, and the technical aspects of maximizing vein bypass graft patency are reviewed. (*Neurosurgery* 50:663–668, 2002)

Key words: Cerebral revascularization, Extracranial-intracranial graft, Pediatric aneurysm

Extracranial-intracranial (EC-IC) bypass is an important adjunct in the treatment of selected patients who re-

quire therapeutic occlusion of large intracranial vessels, e.g., the internal carotid artery or proximal middle cerebral

artery (MCA), for the management of complex intracranial aneurysms or cranial base neoplasms (2, 9, 12, 18, 20, 24, 25, 33, 38, 41). Techniques such as in situ anastomosis, EC-IC arterial grafting, free vein or radial artery grafting, and synthetic conduit formation have been applied to both the anterior and posterior circulations (8, 10, 11, 14, 15, 19, 21, 22, 27, 32, 34, 35, 39, 40, 43). Reported overall complication rates for EC-IC bypasses have been low, with 10-year patency rates as high as 73% (25, 30, 36).

Most of these data, however, were derived from adult patient populations. Here we describe two pediatric cases of giant, complex, intracranial aneurysms that were treated with autogenous saphenous vein EC-IC bypasses. Both patients have undergone significant growth since surgery, and both have exhibited excellent neurological outcomes and long-term graft patency.

CASE REPORTS

Patient 1 was a 13-year-old boy who presented to the University of Florida with right-sided headaches and retro-orbital pain, followed quickly by progressive diplopia. An examination revealed complete right abducens palsy, partial right oculomotor nerve paresis, and right V2 distribution hypesthesia. Computed tomography and cerebral angiography demonstrated a 5-cm × 3-cm, giant, fusiform, right intracavernous internal carotid artery aneurysm (*Fig. 1*), without evidence of subarachnoid hemorrhage. The patient underwent trapping of the affected internal carotid artery segment, combined with an autogenous saphenous vein graft bypass from the cervical external carotid artery to the proximal MCA (performed by ALD). The patient tolerated the procedure well, and postoperative right common carotid artery arteriograms demonstrated excellent graft patency and good flow into the right MCA distribution (*Fig. 2*). At the time of presentation, the patient was 147 cm tall and weighed 44 kg. Two years later, he was 178 cm tall and weighed 65 kg. His neurological examination results were nor-

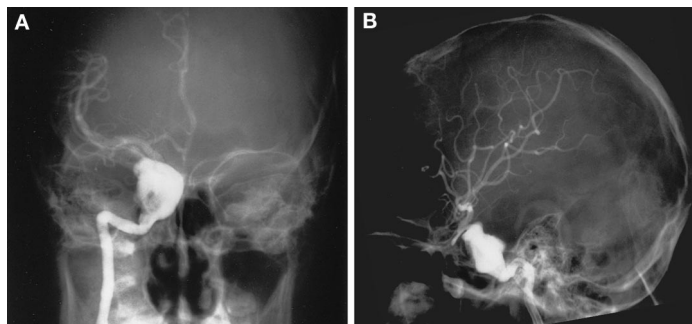


FIGURE 1. Patient 1. Anteroposterior (A) and lateral (B) right internal carotid artery angiograms demonstrated a giant cavernous aneurysm before surgery.

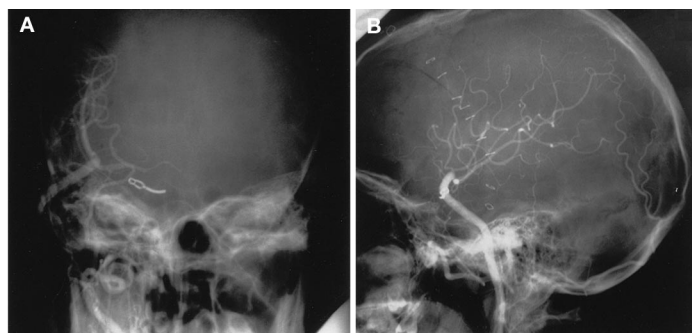

FIGURE 2. Patient 1. Anteroposterior (A) and lateral (B) right external carotid artery angiograms demonstrated a patent EC-IC saphenous vein graft, with satisfactory right MCA filling, immediately after surgery.

mal, and a bounding pulse could be palpated along the bypass graft.

Patient 2 was a 10-month-old girl who initially presented to Emory University with generalized seizures and mild right hemiparesis. Head computed tomographic scans and brain magnetic resonance imaging scans revealed subarachnoid hemorrhage and a left sylvian fissure mass (Fig. 3). Cerebral angiography demonstrated a giant fusiform aneurysm at the left MCA bifurcation, extending primarily into the superior trunk (Fig. 4). The patient was treated with an M2-M2, end-to-side, in situ anastomosis and clip ligation of the aneurysm (performed by DLB).

The inferior division of the MCA was free of aneurysm, but the superior trunk was involved with a complex, multilobulated, fusiform aneurysm with no discernible neck. The inferior trunk was temporarily trapped, with barbiturate and mild hypothermic protection. The superior trunk was trapped and divided distal to the aneurysm. An arteriotomy was made at the site of the planned

anastomosis, and the proximal end of the divided superior trunk was anastomosed in an end-to-side manner to the inferior trunk, using interrupted 10-0 monofilament sutures.

Clinically, the patient fared quite well after this operation; however, in routine 1-year follow-up studies, a recurrent left MCA giant aneurysm, slightly proximal to the original location, was identified (Fig. 5). During surgery, the proximal MCA was clip-ligated to reverse MCA flow, and a saphenous vein was anastomosed between the cervical external carotid artery and the normal left MCA distally.

After re-elevation of the left frontotemporal craniotomy, the sylvian fissure was opened and the previous M2-M2 anastomosis was identified. There was no evidence of recurrence of the aneurysm on the superior trunk of the MCA bifurcation, but the M1 segment of the MCA was aneurysmal, with extension into the inferior trunk of the MCA bifurcation, beyond the point at which the end-to-side anastomosis of the M2 branches had been

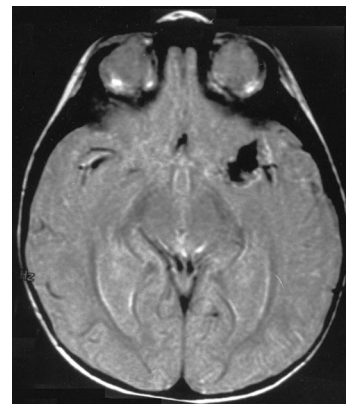


FIGURE 3. Patient 2. This axial, fluid-attenuated inversion recovery, magnetic resonance imaging scan obtained at the time of the initial presentation of the 10-month-old patient revealed a complex flow void pattern for the giant left MCA aneurysm.

previously performed. We thought that this most likely represented a dissecting aneurysm.

A distal M2 branch of adequate caliber was selected as a site for planned saphenous vein bypass grafting. A small rubber dam was placed beneath the site of proposed anastomosis. The cervical carotid artery bifurcation was exposed through an incision along the anterior border of the sternocleidomastoid. The greater saphenous vein was exposed from the groin, just medial to the femoral artery, to a point just above the knee. Side branches were tied with 4-0 silk sutures. A marker was used to place an orientation line across the anterior surface of the vein after transposition. A temporary aneurysm clip was placed across the proximal end of the vein. The distal end of the vein was divided and attached to a Shiley vein distender, and the vein was filled with cold heparinized saline solution.

A shunt tube passer was passed anterior to the ear, within the subcutaneous tissue, from the cervical incision to the cranial incision, and the vein graft was reversed and passed through the shunt tube passer. After proper orientation of the vein (using the previously placed marks), the patient was given 100 U of heparin/kg and barbiturates were administered until electroencephalo-

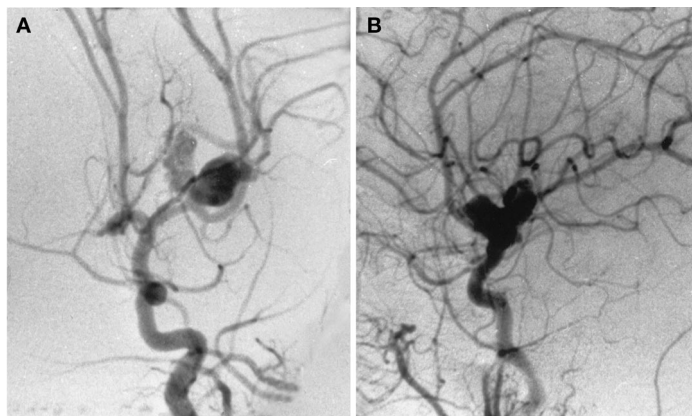


FIGURE 4. Patient 2. Anteroposterior (A) and lateral (B) left common carotid artery angiograms, obtained at the time of the initial presentation, demonstrated a giant fusiform aneurysm at the left MCA bifurcation, extending primarily in to the superior trunk.

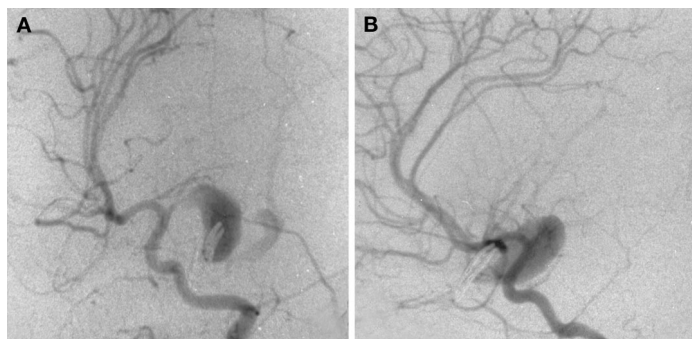

FIGURE 5. Patient 2. Oblique (A) and lateral (B) left internal carotid artery angiograms, obtained in 1-year follow-up studies after the initial treatment, demonstrated a recurrent proximal left MCA giant aneurysm, with the initial aneurysm clip in place.

graphic burst suppression was observed. The MCA recipient vessel was occluded, between two small temporary clips, at the site of the planned anastomosis, and an arteriotomy was initiated with an ophthalmic knife and microscissors. The end of the vein was spatulated, and an end-to-side anastomosis was performed with the use of 8-0 monofilament sutures, which were initially placed at both ends of the anastomosis; the anastomosis was completed with running sutures. After completion of the anastomosis, the temporary clips were removed and brisk back-bleeding in the vein, to the site of the temporary clip, was noted.

The cervical external carotid artery was occluded with a temporary clip just above the bifurcation, and the distal external carotid artery was occluded with

3-0 silk sutures. The external carotid artery was divided and spatulated, as was the proximal end of the vein graft. An end-to-end anastomosis was completed with 7-0 interrupted Prolene sutures. Before placement of the last suture, the vein graft was back-bled and the temporary clip was removed from the external carotid artery for flushing. The final suture was placed, and the temporary clips were removed. The M1 segment of the MCA was occluded proximal to the aneurysm, with an aneurysm clip. Intraoperative angiography demonstrated excellent filling of the MCA through the bypass graft and some retrograde filling of the distal portion of the aneurysm (Fig. 6).

The patient tolerated the procedure well and recovered fully except for minimal right hemiparesis resulting from

the initial subarachnoid hemorrhage. She is now 6 years of age and has grown considerably in the past 4 years. Recent follow-up cerebral angiograms demonstrated continued patency of the bypass graft and progressive aneurysm shrinkage (Fig. 7). The neurological examination results for the patient are now normal.

DISCUSSION

Morley and Barr (28) first defined giant aneurysms as being at least 25 mm in size. Although the definition is somewhat arbitrary, lesions of this size have unique clinical features, which make them some of the most technically challenging cerebrovascular disorders to treat surgically (4, 28). Giant aneurysms may present with mass effect (including ventricular obstruction, with hydrocephalus), embolic ischemic events, or hemorrhage (4, 40, 41). Contrary to earlier reports, giant aneurysms are associated with significant hemorrhage rates (41). The natural history of giant intracranial aneurysms (outside the cavernous sinus) is grim, with mortality rates of up to 80% within a few years after diagnosis without treatment (1, 4, 5, 13).

Surgical strategies to treat these difficult lesions include reconstructive and deconstructive techniques and are selected on the basis of the location, size, and configuration of the aneurysm and the medical condition of the patient. Reconstructive options include surgical clip ligation and endovascular coiling, with parent artery preservation. Unfortunately, endovascular coiling has not proven to be a particularly effective or durable treatment for most giant aneurysms. Deconstructive procedures involve surgical or endovascular Hunterian ligation of the afferent artery or trapping of the arterial segment harboring the aneurysm, with or without some form of bypass to augment cerebral blood flow (3, 16, 29, 40).

The rationale for Hunterian ligation of the parent artery to treat intracranial aneurysms is based on the concept that diminished intralésional pressure promotes thrombosis. This concept is supported by the observation that, on follow-up angiograms, 86% of giant aneurysms in the anterior circulation ex-

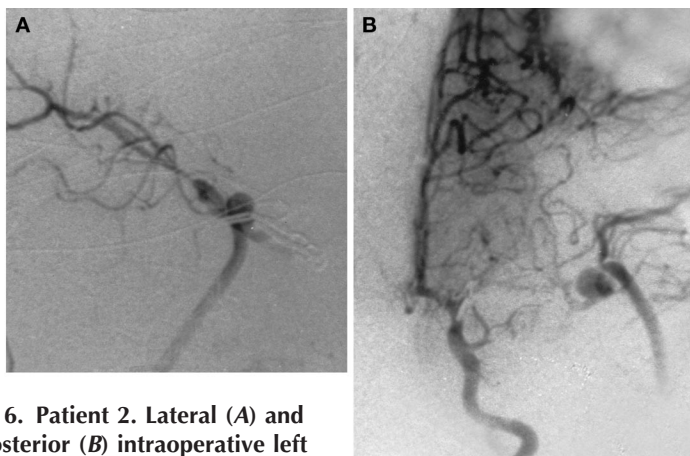


FIGURE 6. Patient 2. Lateral (A) and anteroposterior (B) intraoperative left common carotid artery angiograms, obtained during the second operation, revealed clip ligation of the proximal left MCA and satisfactory patency of the EC-IC vein bypass graft filling the distal MCA territory. Some retrograde filling of the distal portion of the aneurysm could also be observed.

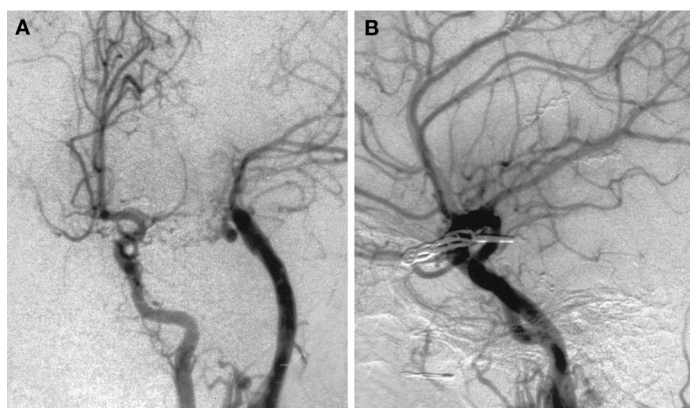


FIGURE 7. Patient 2. Anteroposterior (A) and lateral (B) left common carotid artery angiograms, obtained in 4-year follow-up studies after the EC-IC bypass, demonstrated excellent growth of the bypass graft and filling of the MCA distribution. Distal aneurysm retrograde filling was diminished.

hibited either partial or complete luminal thrombosis after parent vessel ligation (31). Most intracranial dissecting aneurysms cannot be clipped directly, and the treatment of choice (when treatment is indicated) is proximal arterial ligation (12, 26, 42, 43).

The indications for combining cerebral revascularization with proximal ligation or trapping of the offending vessel segment in the management of complex intracranial aneurysms remain controversial. Many cerebrovascular surgeons select the procedure on the basis of the patient's collateral circulation and tolerance to afferent vessel occlusion,

as determined by preoperative balloon test occlusion and subsequent cerebral blood flow studies (9, 32). Others advocate universal revascularization for all patients requiring surgical arterial occlusion (18). Both of our cases involved pediatric patients who were expected to undergo significant growth in the course of long lives, and revascularization was chosen to minimize both the immediate ischemic risks and the long-term enhancement of pressure on the collateral pathways supplying the territory distal to the sacrificed vessel.

In both cases, venous bypass grafts were chosen because of their high flow

capacities and the large perfusion territories requiring support for long periods. For Patient 2, we had no reliable clinical method to determine tolerance to parent vessel occlusion and we were reluctant to attempt complete MCA sacrifice without some type of distal flow augmentation. In both cases, no superficial temporal artery of sufficient size was available, had we preferred to use such a channel.

Vein grafts have significantly higher occlusion rates than do artery-to-artery anastomoses. Clinical and experimental experiences in peripheral vascular and cardiovascular surgery, however, have greatly enhanced our understanding and improved the outcomes of the use of autogenous vein grafts as bypass conduits within the central nervous system (6, 17, 23, 36). The two most serious complications of vein graft bypasses are intracranial hemorrhage and graft thrombosis, and proper patient selection and perioperative hemodynamic stabilization have reduced the incidences of these complications (7, 25, 29, 37).

Early graft failure is most often attributable to thrombosis prompted by graft endothelial damage, low flow rates, a hypercoagulable state, or technical errors (7, 36, 37). Intimal desquamation can be minimized by meticulous atraumatic harvesting techniques and by the design of proximal and distal anastomoses to decrease turbulence (17, 36, 37). Graft flow must be optimized, with attention to conduit diameters at both the inflow and outflow sites. Perioperative systemic anticoagulation therapy also seems to improve graft survival rates. Torsion of the graft in the skin tunnel, kinking after expansion of the graft under arterial pressure, external compression of the conduit by fascia or the craniotomy edge, and damage attributable to vascular clamps, forceps, or suture stenosis are all important technical problems that must be avoided (7).

Late graft failure (beyond the early perioperative period) is most often caused by the development of atherosclerosis in the venous channel as it thickens in response to the increased pressure and flow (36). Antiplatelet agents such as aspirin and clopidogrel may have some effects in reducing this phenomenon, as may reduction of se-

rum cholesterol and triglyceride levels. Other risk factors, such as diabetes mellitus, hypertension, and smoking, should be adequately controlled or eliminated.

Experience with the use of autogenous vein grafts as vascular conduits for prepubertal pediatric patients is lacking in cerebrovascular surgery. What is the effect of longitudinal growth on the graft? Will the graft progressively stretch with time and accommodate the growth easily, or will adherence of the graft to its subcutaneous tunnel inhibit its growth and contribute to progressive narrowing or thrombosis?

To our knowledge, our Patient 2 represents the youngest person reported to have successfully undergone an EC-IC vein graft bypass. The long-term graft patency, progressive growth of the vein grafts, and clinical success in both cases suggest that the use of autogenous long-segment vein grafts can be a safe effective option for the management of complex cerebrovascular disorders among pediatric patients, particularly if the proper principles for cerebral revascularization are applied.

ACKNOWLEDGMENT

We thank Dr. Joseph Petronio for assistance with the treatment of Patient 2.

Received, February 2, 2001.

Accepted, November 2, 2001.

Reprint requests: Daniel L. Barrow, M.D., Department of Neurosurgery, The Emory Clinic, 1365-B Clifton Road, NE, Suite 6400, Atlanta, GA 30322.

Email: daniel_barrow@emoryhealthcare.org

REFERENCES

1. Anson JA: Epidemiology and natural history, in Awad IA, Barrow DL (eds): *Giant Intracranial Aneurysms*. Park Ridge, AANS, 1995, pp 23-33.
2. Ausman JI, Pearce JE, de los Reyes RA, Schanz G: Treatment of a high extracranial carotid artery aneurysm with CCA-MCA bypass and carotid ligation. *J Neurosurg* 58:421-424, 1983.
3. Awad IA, Barrow DL: Conceptual synthesis and future outlook, in Awad IA, Barrow DL (eds): *Giant Intracranial Aneurysms*. Park Ridge, AANS, 1995, pp 277-282.
4. Barrow DL, Alleyne CH: Natural history of giant intracranial aneurysms and indications for intervention. *Clin Neurosurg* 42:214-244, 1995.

5. Barrow DL, Cawley CM: Clinical manifestations of giant intracranial aneurysms, in Awad IA, Barrow DL (eds): *Giant Intracranial Aneurysms*. Park Ridge, AANS, 1995, pp 35-39.
6. Campeau L, Enjalbert M, Lesperance J, Vaislic C, Grondin GM, Bourassa MG: Atherosclerosis and late closure of aortocoronary saphenous vein grafts: Sequential angiographic studies at 2 weeks, 1 year, 5 to 7 years, and 10 to 12 years after surgery. *Circulation* 68:III-III7, 1983.
7. Diaz FG, Pearce J, Ausman JI: Complications of cerebral revascularization with autogenous vein grafts. *Neurosurgery* 17:271-276, 1985.
8. Diaz FG, Umansky F, Mehta B, Montoya S, Dujovny M, Ausman JI, Cabezudi JL: Cerebral revascularization to a main limb of the middle cerebral artery in the sylvian fissure. *J Neurosurg* 63:21-29, 1985.
9. Drake CG, Peerless SJ, Ferguson GG: Hunterian proximal arterial occlusion for giant aneurysms of the carotid circulation. *J Neurosurg* 81:656-665, 1994.
10. Fitzpatrick BC, Spetzler RF, Ballard JL, Zimmerman RS: Cervical-to-petrous internal carotid artery bypass procedure. *J Neurosurg* 79:138-141, 1993.
11. Friedrich H, Laas J, Walterbusch G, Rickels E: Extra-intracranial bypass procedure with saphenous vein grafts. *Thorac Cardiovasc Surg* 34:57-62, 1986.
12. Harris ME, Barrow DL: Arterial dissection, in Tindall GT, Cooper PR, Barrow DL (eds): *The Practice of Neurosurgery*. Baltimore, Williams & Wilkins, 1996, pp 1899-1906.
13. Hosobuchi Y: Direct surgical treatment of giant intracranial aneurysms. *J Neurosurg* 51:743-756, 1979.
14. Houkin K, Ishikawa T, Kuroda S, Abe H: Vascular reconstruction using interposed small vessels. *Neurosurgery* 43:501-505, 1998.
15. Houkin K, Kamiyama H, Kuroda S, Ishikawa T, Takahashi A, Abe H: Long-term patency of radial artery graft bypass for reconstruction of the internal carotid artery. *J Neurosurg* 90:786-790, 1999.
16. Ishikawa T, Houkin K, Abe H, Isobe M, Kamiyama H: Cerebral hemodynamics and long term prognosis after extracranial-intracranial bypass surgery. *J Neurol Neurosurg Psychiatry* 59:625-628, 1995.
17. Izzar MB, Mehta D, Bryan AJ, Reeves B, Newby AC, Angelini GD: Influence of external stent size on early medial and neointimal thickening in a pig model of saphenous vein bypass grafting. *Circulation* 94:1741-1745, 1996.
18. Lawton MT, Hamilton MG, Morcos JJ, Spetzler RF: Revascularization and aneurysm surgery: Current techniques, indications, and outcome. *Neurosurgery* 38:83-94, 1996.
19. Lee SY, Sekhar LN: Treatment of aneurysms by excision or trapping with arterial reimplantation or interpositional grafting: Report of three cases. *J Neurosurg* 85:178-185, 1996.
20. Linskey ME, Sekhar LN, Sen CN: Cerebral revascularization in cranial base surgery, in Sekhar LN, Jenecka IP (eds): *Surgery of Cranial Base Tumors*. New York, Raven Press, 1993, pp 45-68.
21. Little JR, Furlan AJ, Bryerton B: Short vein grafts for cerebral revascularization. *J Neurosurg* 59:384-388, 1983.
22. Lougheed WM, Marshall BM, Hunter M, Michel ER, Sandwith-Smyth H: Common carotid to intracranial internal carotid bypass venous graft: Technical note. *J Neurosurg* 34:114-118, 1971.
23. Lytle BW, Loop FD, Cosgrove DM, Ratliff NB, Easley K, Taylor PC: Long-term (5-12 years) serial studies of internal mammary artery and saphenous vein coronary bypass grafts. *J Thorac Cardiovasc Surg* 89:248-258, 1985.
24. Miyazaka S, Fukushima T, Fujimaki T: Resection of high-cervical paraganglioma with cervical-to-petrous internal carotid bypass venous graft: Report of two cases. *J Neurosurg* 73:141-146, 1990.
25. Morgan MK: Cerebral revascularization, in Kaye AH, Black PMCL (eds): *Operative Neurosurgery*. New York, Harcourt Publishers, 2000, pp 1163-1178.
26. Morgan MK, Sekhon LH: Extracranial-intracranial saphenous vein bypass for carotid or vertebral artery dissections: A report of six cases. *J Neurosurg* 80:237-246, 1994.
27. Morgan MK, Brennan J, Day MJ: Interposition saphenous vein bypass graft between the common and intracranial internal carotid arteries. *J Clin Neurosci* 3:272-280, 1996.
28. Morley TP, Barr HWK: Giant intracranial aneurysms: Diagnosis, course, and management. *Clin Neurosurg* 16:73-94, 1969.
29. Nussbaum ES, Erickson DL: Extracranial-intracranial bypass for ischemic cerebrovascular disease refractory to maximal medical therapy. *Neurosurgery* 46:37-43, 2000.
30. Regali L, Piepgras DG, Hansen KK: Late patency of long saphenous vein bypass grafts to the anterior and posterior cerebral circulation. *J Neurosurg* 83:806-811, 1995.
31. Roski RA, Spetzler RF: Carotid ligation, in Wilkins RH, Rengachary SS (eds): *Neurosurgery*. New York, McGraw-Hill, 1996, pp 2333-2340.
32. Sekhar LN, Sen CN, Jho HD: Saphenous vein graft bypass of the cavernous internal carotid artery. *J Neurosurg* 72:35-41, 1990.
33. Spetzler RF, Fukushima T, Martin N, Zabramski JM: Petrous carotid-to-intradural carotid saphenous vein graft for intracavernous giant aneurysm, tumor, and occlusive cerebrovascular disease. *J Neurosurg* 73:496-501, 1990.
34. Spetzler RF, Rhodes RS, Roski RA, Likavec MJ: Subclavian to middle cerebral artery saphenous vein bypass graft. *J Neurosurg* 53:465-469, 1980.
35. Story JL, Brown WE Jr, Eidelberg E, Arom KV, Stewart JR: Cerebral revascularization: Proximal external carotid to distal middle cerebral artery bypass with a synthetic tube graft. *Neurosurgery* 3:61-65, 1978.
36. Sundt TM III, Sundt TM Jr: Maximizing patency in saphenous vein bypass grafts: Principles of preparation learned from coronary and peripheral vascular surgery, in Sundt TM Jr (ed): *Occlusive Cerebrovascular Disease: Diagnosis and Surgical Management*. Philadelphia, W.B. Saunders Co., 1987, pp 429-438.
37. Sundt TM III, Sundt TM Jr: Principles of preparation of vein grafts to maximize patency. *J Neurosurg* 66:172-180, 1987.
38. Sundt TM Jr, Fode NC, Jack CR Jr: The past, present, and future of extracranial to intracranial bypass surgery. *Clin Neurosurg* 34:134-153, 1988.

39. Sundt TM Jr, Piepgras DG, Houser OW, Campbell JK: Interposition saphenous vein grafts for advanced occlusive disease and large aneurysms in the posterior circulation. *J Neurosurg* 56:205–215, 1982.
40. Sundt TM Jr, Piepgras DG, Marsh WR, Fode NC: Saphenous vein bypass grafts for giant aneurysms and intracranial occlusive disease. *J Neurosurg* 65:439–450, 1986.
41. Thompson BG Jr, Kraus GE, Hamilton GH, Spetzler RF: Special techniques for managing giant intracranial aneurysms, in Tindall GT, Cooper PR, Barrow DL (eds): *The Practice of Neurosurgery*. Baltimore, Williams & Wilkins, 1996, pp 2105–2125.
42. Yamaura A, Watanabe Y, Saeki N: Dissecting aneurysms of the intracranial vertebral artery. *J Neurosurg* 72:183–188, 1990.
43. Yoshimoto T, Kamiyama H, Abe H, Takikawa S, Ito T: Proximal clipping and bypass between bilateral artery using a radial artery graft for treatment of a dissecting aneurysm of the vertebral artery. *Surg Neurol* 36:476–481, 1991.

COMMENTS

This is a report of two patients, one of whom was only 2 years of age, who underwent successful proximal vessel occlusion and extracranial-intracranial saphenous vein bypass grafts for giant carotid circulation aneurysms. The authors make the point that the grafts have remained patent 2 and 4 years later, despite longitudinal growth.

Certainly, performance of a successful saphenous vein graft in a 2-year-old patient is a significant technical feat. It is not surprising to me that longitudinal growth did not affect the graft, since it is autologous tissue that has become in-

corporated into the patient's own tissues. It will be interesting to follow these patients over decades, to see whether problems with atherosclerosis develop, as the authors allude to in the Discussion.

I might take issue with the authors' statement that coiling is not effective or durable in most giant aneurysms. At least in children, we have increasingly relied on endovascular techniques to treat giant aneurysms in patients as young as 3 months of age, and there have been no recurrences after successful obliteration. Children may tolerate proximal vessel occlusions better than adults, and we might have attempted a trial balloon occlusion in Patient 1 in this report.

Leslie N. Sutton

Philadelphia, Pennsylvania

This article is remarkable for its publication of the achievement of some very difficult vascular neurosurgical procedures in a 23-month-old child. Her height and weight are not given, but it can be presumed that her cerebral vessels were small and certainly well under 1 mm in diameter at the time of her surgical procedure. The authors were able to achieve two very difficult vascular procedures in this child: an M2–M2 in situ anastomosis and clip ligation of an aneurysm when the patient was 10 months of age, and then, a year later, an

external carotid-to-middle cerebral artery anastomosis with the use of a saphenous vein graft. Both of these procedures are technically challenging in the adult patient; in a patient of this size, the authors' achievement was a remarkable one. Her postoperative angiograms showed patency of the graft, and the long-term follow-up with confirmatory angiography demonstrated graft patency and elongation with growth.

The authors have also provided some details about their technique, which will help neurosurgeons to evaluate it. I would have appreciated specific information about the sizes of the vessels involved, particularly the diameter of the recipient middle cerebral vessel and how it compared with the greater saphenous vein, which was harvested from the groin to just above the knee. "Spatulation" of the vein would be anticipated to increase the functional diameter even further. How the size discrepancies were dealt with is not really clear from the article. This article is valuable because it demonstrates that the vascular surgeon's armamentarium for dealing with complicated aneurysms in the adult patient can be transferred to the pediatric patient. The authors have made an outstanding technical achievement.

R. Michael Scott

Boston, Massachusetts