

# Recurrent Torticollis Caused by Dissecting Vertebral Artery Aneurysm in a Pediatric Patient: Results of Endovascular Treatment by Use of Coil Embolization: Case Report

Salvatore Grosso, M.D., Rosa Mostardini, M.D.,  
Carlo Venturi, M.D., Sandra Bracco, M.D.,  
Alfredo Casasco, M.D., Rosario Berardi, M.D.,  
Paolo Balestri, M.D.

Departments of Pediatrics, Obstetrics, and Reproductive Medicine (SG, RM, RB, PB),  
University of Siena, Siena, and Unit of Diagnostic and Therapeutic Neuroradiology (CV, SB,  
AC), Azienda Ospedaliera Senese, Siena, Italy

**OBJECTIVE AND IMPORTANCE:** Torticollis is a symptom that can be related to different pathological mechanisms ranging from simple to life-threatening conditions. We report a child with recurrent torticollis caused by an intracranial dissecting vertebral artery aneurysm. This is a very rare condition in childhood, and it was resolved successfully with endovascular treatment.

**CLINICAL PRESENTATION:** The patient was a 10-year-old boy with a 4-year history of left recurrent torticollis, followed by hemiparesis, dysarthria, dysmetria, and tremor. Brain magnetic resonance imaging and digital angiography detected a dissecting aneurysm involving the fourth segment of the left vertebral artery.

**INTERVENTION:** The patient underwent endovascular treatment. Coil embolization, followed by histoacryl injection into the lesion, provided complete obliteration of the aneurysmal sac.

**CONCLUSION:** The patient's postoperative course was characterized by a dramatic disappearance of symptoms and signs within a few hours of the intervention. No relapses of symptoms occurred during a follow-up period of 18 months. This is the first report of a child in whom recurrent torticollis was related to a dissecting vertebral artery aneurysm. Although long-term results of vertebral artery coil embolization remain to be elucidated, the method seems reliable and effective in treatment of these vascular lesions in pediatric patients. (*Neurosurgery* 50:204–208, 2002)

**Key words:** Coil embolization, Dissecting artery aneurysm, Endovascular therapy, Torticollis

**T**orticollis, an unnatural head and neck position in tilt, rotation, and flexion, is considered a sign rather than a specific diagnosis (3). A wide spectrum of disorders, ranging from simple

to life-threatening conditions, can provoke an acquired torticollis (11, 13, 27). Torticollis generally is classified as muscular or nonmuscular (3) in origin, and more than 80 different causes of torticol-

lis have been described (13). Differential diagnosis may be difficult (4).

Dissecting vertebral artery (VA) aneurysm is increasingly recognized as a source of appreciable morbidity and mortality (7, 8, 14, 17, 28, 30). Although it accounts for 3.2% of all intracranial aneurysms in adults, dissecting VA aneurysm is rare in childhood (18, 20, 23). Most intracranial VA dissections occur spontaneously or after minor blunt trauma (30). However, several risk factors for dissecting VA aneurysm, such as connective tissue disorders (18, 20–23, 25), sickle cell disease, rheumatoid arthritis, and osteogenesis imperfecta have been recognized (10, 26). When considered globally, a familial aggregation of intracranial aneurysms also is observed (18–20, 22, 24, 25). Presentation may include a variable combination of neck pain, headache, and transient loss of consciousness (18, 26). Symptoms and signs can be subtle, intermittent, or even chronic (5). In children who present with severe posterior headache or neck pain and signs of cerebellar or brainstem dysfunction, dissecting VA aneurysm should be considered early in the differential diagnosis, along with masses in the posterior fossa, viral and postviral cerebellitis, complex migraine, and encephalitis (6). Dissecting VA aneurysm is a potentially devastating neurological condition that requires specific therapeutic intervention to avoid patient death.

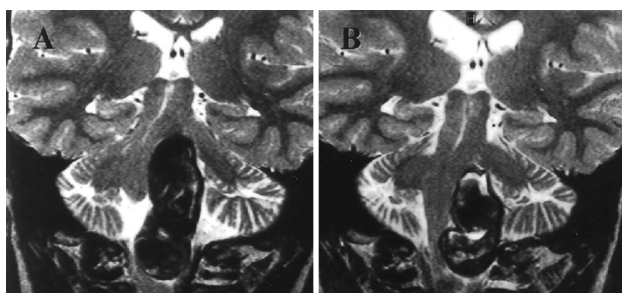
We report a child with a dissecting VA aneurysm who had no history of trauma or underlying risk factors. The patient presented with recurrent episodes of torticollis followed by progressive hemiparesis. The condition was resolved successfully by endovascular treatment. Clinical findings and technical features of the intervention are discussed.

## CASE REPORT

The patient was a 10-year-old boy with nonconsanguineous, healthy parents. There was no family history of acquired or congenital vascular anomalies. No risk factors for artery aneurysm

were present in the child. He was well until the age of 4 years, when he presented with an episode of occipital headache of acute onset, accompanied by aphasia and vomiting. The patient was admitted to a regional hospital, where physical examination revealed indications of meningitis, including mild neck rigidity and Lasègue's sign. No loss of consciousness was reported. Despite a negative cerebrospinal fluid culture and a negative Pandy's test result, meningoencephalitis was suspected. The patient recovered completely after 3 days without treatment. No magnetic resonance imaging evaluation was performed. Subsequently, the patient experienced several episodes of mild occipital headache, accompanied by episodes of tilting of the neck to the left side. Elevation of the shoulder, caused by contraction of the right trapezius and sternocleidomastoideus muscles, was associated with the condition. The symptoms were exacerbated with the head at rest, and they disappeared during sleep. Torticollis did not worsen under conditions of stress, and the patient never reported muscular pain. During a 4-year period, the characteristic posture of torticollis was intermittent. The episodes were more frequent and prolonged initially, lasting up to a week, and subsequently they occurred approximately every 3 months. The patient never developed constant deviation of the neck. Several orthopedic evaluations were performed, but the torticollis remained unexplained. Several nonsteroidal anti-inflammatory drugs, with associated physiotherapy, did nothing to improve the condition, and no further investigations were performed.

When the boy was 8½ years of age, his clinical features worsened with progressive hemiparesis, and he was referred to our care. Physical examination revealed a left-sided head tilt, without contraction of the sternocleidomastoid muscle. A double, medium bulbar alternating hemiplegia, more evident on the right side, was observed, as were increased deep tendon reflexes. Hypertonia with reduced muscular strength, mainly on the right side, was noted. Babinski's sign and ankle clonus were detected, as were dysmetria, intentional



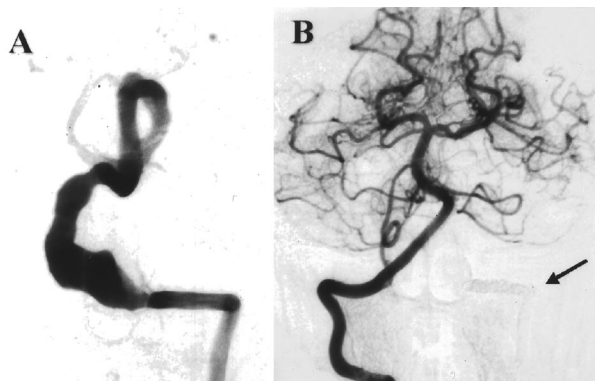
**FIGURE 1.** Coronal T2-weighted magnetic resonance imaging scans. *A*, expansive and dyshomogeneous hypointense brainstem lesion exerting mass effect with displacement of the pons and medulla oblongata before treatment. *B*, 2 months later, the embolization treatment resulted in the evident reduction in the size of the mass.

tremor, and horizontal nystagmus. The child was dysarthric. Brain magnetic resonance imaging with and without contrast enhancement revealed an expansive brainstem lesion, which had caused displacement of the pons and medulla oblongata. The fourth ventricle seemed to be displaced posteriorly and almost occluded. However, no signs of hydrocephalus were observed (*Fig. 1A*). Cerebral angiography revealed a fusiform dilation with proximal and distal narrowing in the fourth segment of the left VA, up to the presumed origin of the posteroinferior cerebellar artery (*Fig. 2A*). Retention of contrast medium into the late arterial phase of the cardiac cycle, and a double lumen sign, also were observed.

In view of the clinical deterioration, it was decided to perform prompt endovascular embolization. The procedure was accomplished with the patient under general anesthesia. A preliminary test occlusion of the left VA by use of a Magic B1 balloon (Balt, Montmorency, France) was performed. After systemic

heparinization, the balloon was placed proximal to the aneurysm at the origin of the C6 radicular medullary artery. The balloon was inflated for 10 minutes and revealed anterior spinal artery perfusion from the deep cervical artery. During the test occlusion, right VA injection continued to produce complete cerebellar perfusion and prompt symmetrical venous drainage. After successful test occlusion, the parent vessel was occluded proximal to the aneurysm with Guglielmi detachable coils (Target Therapeutics, Inc., Fremont, CA), which were introduced by a Tracker Excel 14 microcatheter (Boston Scientific, Natick, MA). Vessel occlusion was achieved by injection of histoacryl, which completely arrested the flow in the left VA. After complete occlusion of the intradural left VA, however, the aneurysm was still feebly opacified in its upper portion from the right VA injection.

In subsequent days, the patient exhibited a dramatic clinical improvement. Hemiparesis and torticollis disappeared and deep tendon reflexes became nor-



**FIGURE 2.** Digital subtraction angiograms, anteroposterior view. *A*, injection of contrast medium into the left vertebral artery, showing fusiform aneurysmatic dilation of the left vertebral artery up to the origin of the posteroinferior cerebellar artery. *B*, postembolization stage showing injection of contrast medium into the right vertebral artery, with lack of reflux down the left vertebral artery (arrow).

mal. No ankle clonus or Babinski's sign was observed. Cerebellar signs also were absent and dysarthria disappeared. Muscular strength and fine motor skills recovered completely. One week after therapeutic intervention, the child was able to walk and play soccer. Headache also was absent. Digital angiography, performed 2 months later, demonstrated no evidence of perfusion through the lesion from the right VA injection (Fig. 2B). Clinical follow-up during an 18-month period demonstrated a normal child. At the neuroradiological evaluation, which included three magnetic resonance imaging scans performed 2 days, 2 months, and 1 year after the intervention, the mass effect of the aneurysm was still apparent on the pons and medulla oblongata, without perilesional edema (Fig. 1B). No signs of infarction or hemorrhage were present.

## DISCUSSION

In this pediatric patient, clinical findings at the onset of symptoms were compatible with a prodromal clinical picture of a subarachnoid hemorrhage, possibly caused by minor leakage of blood into the wall of the aneurysm or into the subarachnoid space (18, 20). Thereafter, the patient demonstrated a peculiar clinical course, characterized by recurrent episodes of tilting of the neck to the left side. During a 4-year period, several anti-inflammatory drugs and physiotherapy treatments were administered without success. The initial manifestations of VA dissection are not distinct and often are misinterpreted as musculoskeletal (18, 26). The patient was referred to us when further neurological disturbances appeared, including hemiparesis, tremor, dysmetria, and dysarthria. Imaging and angiographic studies detected a dissecting fusiform aneurysm involving the fourth segment of the left VA. This case clearly confirms the need to consider central nervous system abnormalities in any child with recurrent and unexplained torticollis, because it may represent a life-threatening condition that demands expeditious evaluation and treatment (4).

Unlike the condition in adults, in which neurovascular compression of the spinal nerve accessory has been de-

scribed in patients with torticollis (1), vascular anomalies are considered a rare cause of torticollis in children (4). To our knowledge, only three pediatric cases have been reported previously. One patient had VA dilation secondary to hypoplasia of the internal carotid artery (12). The second report described a child with an elongated VA loop (15). The third patient, as reported by Bayrakci et al. (4), had an arteriovenous fistula at the craniovertebral junction, fed by the anterior spinal artery. In the first two patients, torticollis was related to neurovascular compression of the spinal accessory nerve. In view of the clinical findings, more than one cause may be considered in our patient and in the case described by Bayrakci et al. (4), such as compression of the right spinal accessory nerve, meningeal irritation by a bulging vascular structure, mass effects, and changes in blood supply of the vestibular nuclear complex in the pons and medulla, and the cerebellum.

From a therapeutic standpoint, in the present case the principal aim was proximal occlusion of the VA adjacent to the dissection without manipulation of the aneurysm (5). Dissecting aneurysms are extremely fragile, and endovascular occlusion of the parent vessel is the safest method of treatment (5). In this context, balloon occlusion is the conventional method used to treat a dissecting intradural VA aneurysm (8, 9, 28). However, coil embolization is increasingly recognized as a reliable alternative technique in adults (2, 5, 16, 29). Overall, aneurysms with narrow necks are more amenable to endovascular treatment than those with wide necks, because in the latter condition, the coils tend to compact into the body and dome of the aneurysm, resulting in an aneurysm remnant and incomplete treatment (18). Coils are easier to manipulate than balloons, and by use of a detachable coil system, it is possible to occlude the vessel over a short segment (5). A theoretical disadvantage of coils could be the lack of an instantaneous occlusion, as obtained with balloons, and the subsequent risk of having an embolic source in the transient period of slow flow in the recently occluded vessel. To avoid this risk, we treated the aneurysm with histoacryl resin. The long-term results of

vertebral-artery stenting and coils remain to be elucidated (18, 20).

In our patient, abnormal clinical findings disappeared a few days after the occlusion of the endovascular aneurysm. Several authors claim that the rapid clinical improvement is related to the removal of the mass effect exerted by the aneurysm. However, in this case, we feel that the clinical amelioration could be caused by cessation of the stress caused by the pulsatile flow of the aneurysm on the brainstem structures. This is supported by the persistence of the changes in mass effects, as evaluated by magnetic resonance imaging/magnetic resonance angiography performed in the subsequent months.

In conclusion, this is the first description of a patient with a peculiar recurrent torticollis, and subsequent progressive hemiparesis, related to a dissecting VA aneurysm. The clinical history of this patient should alert pediatricians to consider a possible neurological disorder in any child with unexplained torticollis. In addition, occlusion of the parent vessel by coil embolization led to a dramatic clinical improvement, indicating that such a method is reliable and effective even in children.

Received, May 22, 2001.

Accepted, July 9, 2001.

Reprint requests: Paolo Balestri, M.D., Department of Pediatrics, Obstetrics, and Reproductive Medicine, University of Siena, Viale M. Bracci-Le scotte, 53100 Siena, Italy. Email: balestri@unisi.it

## REFERENCES

- Alafaci C, Salpietro FM, Montemagno G, Grasso G, Tomasello F: Spasmodic torticollis due to neurovascular compression of the spinal accessory nerve by the anteroinferior cerebellar artery: Case report. *Neurosurgery* 47:768-772, 2000.
- Amagasaki K, Yagishita T, Yagi S, Kuroda K, Nishigaya K, Nukui H: Amagasaki K: Serial angiography and endovascular treatment of dissecting aneurysms of the anterior cerebellar and vertebral arteries: Case report. *J Neurosurg* 91:682-686, 1999.
- Ballock RT, Song KM: The prevalence of non-muscular causes of torticollis in children. *J Pediatr Orthop* 16:500-504, 1996.
- Bayrakci B, Aysun S, Firat M: Arteriovenous fistula: A cause of torticollis. *Pediatr Neurol* 20:146-147, 1999.
- Coley SC, Clifton A: Dissecting vertebral artery aneurysm: Diagnosis and coil embolization. *Br J Radiol* 72:408-411, 1999.

6. Feudale F, Liebelt E: Recognizing vertebral artery dissection in children: A case report. *Pediatr Emerg Care* 16:184-188, 2000.
7. Friedman AH, Drake CG: Subarachnoid hemorrhage from intracranial dissecting aneurysm. *J Neurosurg* 60:325-334, 1984.
8. Halbach VV, Higashida RT, Dowd CF, Fraser KW, Smith TP, Teitelbaum GP, Wilson CB, Hieshima GB: Endovascular treatment of vertebral artery dissections and pseudoaneurysms. *J Neurosurg* 79:183-191, 1993.
9. Hodes JE, Aymard A, Gobin YP, Rufenacht D, Bien S, Reizine D, Gaston A, Merland JJ: Endovascular occlusion of intracranial vessels for curative treatment of unclippable aneurysms: Report of 16 cases. *J Neurosurg* 75:694-701, 1991.
10. Horowitz IN, Niparko NA: Vertebral artery dissection with bilateral hemiparesis. *Pediatr Neurol* 11:252-254, 1994.
11. Khan ML, Davidson R, Drummond S: Acquired torticollis in children. *Orthop Rev* 20:667-674, 1991.
12. Kikuchi K, Kowada M, Kojima H: Hypoplasia of the internal carotid artery associated with spasmodic torticollis: The possible role of altered vertebrobasilar hemodynamics. *Neuroradiology* 37:362-364, 1995.
13. Kiwak KJ: Establishing an etiology for torticollis. *Postgrad Med* 75:126-134, 1984.
14. Lotze TE, Paolicchi J: Vertebral artery dissection and migraine headaches in children. *J Child Neurol* 15:694-696, 2000.
15. Lunardi P, Mastronardi L, Farah JO, De Biase C, Trasimeni G, Gualdi GF: Spinal accessory nerve palsy due to neurovascular compression: Report of a case diagnosed by magnetic resonance imaging and magnetic resonance angiography. *Neurosurg Rev* 19:175-178, 1996.
16. Lylyk P, Ceratto R, Hurvitz D, Basso A: Treatment of a vertebral dissecting aneurysm with stents and coils: Technical case report. *Neurosurgery* 43:385-388, 1998.
17. Mizutani T, Aruga T, Kirino T, Miki Y, Saito I, Tsuchida T: Recurrent subarachnoid hemorrhage from untreated ruptured vertebrobasilar dissecting aneurysms. *Neurosurgery* 36:905-911, 1995.
18. Schievink WI: Intracranial aneurysms. *N Engl J Med* 336:28-40, 1997.
19. Schievink WI: Genetics and aneurysm formation. *Neurosurg Clin N Am* 9:485-495, 1998.
20. Schievink WI: Spontaneous dissection of the carotid and vertebral arteries. *N Engl J Med* 344:898-906, 2001.
21. Schievink WI, Meyer FB, Parisi JE, Wijidicks EF: Fibromuscular dysplasia of the internal carotid artery associated with alpha1-antitrypsin deficiency. *Neurosurgery* 43:229-233, 1998.
22. Schievink WI, Mokri B, O'Fallon WM: Recurrent spontaneous cervical-artery dissection. *N Engl J Med* 330:393-397, 1994.
23. Schievink WI, Mokri B, Piepgras DG: Spontaneous dissections of cervicocephalic arteries in childhood and adolescence. *Neurology* 44:1607-1612, 1994.
24. Schievink WI, Parisi JE, Piepgras DG: Familial intracranial aneurysms: An autopsy study. *Neurosurgery* 43:1258-1259, 1998.
25. Schievink WI, Parisi JE, Piepgras DG, Michels VV: Intracranial aneurysms in Marfan's syndrome: An autopsy study. *Neurosurgery* 41:866-870, 1997.
26. Silbert PL, Mokri B, Schievink WI: Headache and neck pain in spontaneous internal carotid and vertebral artery dissections. *Neurology* 45:1517-1522, 1995.
27. Suchowersky O, Calne DB: Non-dystonic causes of torticollis. *Adv Neurol* 50:501-508, 1988.
28. Tsukahara T, Wada H, Satake K, Yaoita H, Takahashi A: Proximal balloon occlusion for dissecting vertebral aneurysms accompanied by subarachnoid hemorrhage. *Neurosurgery* 36:914-919, 1995.
29. Yamaura I, Tani E, Yokota M, Nakano A, Fukami M, Kaba K, Matsumoto T: Endovascular treatment of ruptured dissecting aneurysms aimed at occlusion of the dissected site by using Guglielmi detachable coils. *J Neurosurg* 90:853-856, 1999.
30. Yamaura A, Watanabe Y, Saeki N: Dissecting aneurysms of the intracranial vertebral artery. *J Neurosurg* 72:183-188, 1990.

## COMMENTS

If a pediatric neurosurgeon is asked for the most common nonskeletal cause of torticollis in a child, the posterior fossa tumor would rank near the top of the list. Certainly a vascular lesion, such as an aneurysm or arteriovenous fistula, would not. The tumor may cause torticollis by meningeal irritation, cerebellar tonsillar herniation, and perhaps also by XIth nerve irritation. This article is of value because it reports the first instance of a dissecting vertebral artery aneurysm as the reason for a 10-year-old boy's chronic torticollis, which eventually was followed by objective neurological signs. In addition, the endovascular obliteration of the pediatric patient's aneurysm with coils is noteworthy, and the reader is informed of similar vascular conditions in adults presenting with torticollis. In some situations, the torticollis is caused by compression of the spinal accessory nerve. Finally, one cannot argue with the immediate and lasting success achieved in this patient.

**Robin P. Humphreys**  
Toronto, Ontario, Canada

This case report describes a very unusual case of a huge dissecting aneurysm of the vertebral artery lateral to the brainstem presenting as torticollis. I have not observed a similar case in a pediatric patient. The treatment paradigm chosen by the authors resulted in successful obliteration of the aneurysm but left considerable mass along side the brainstem; I was surprised that the patient demonstrated such dramatic clinical

improvement with disappearance of hemiparesis, dysarthria, and cerebellar signs.

**R. Michael Scott**  
Boston, Massachusetts

The safety and technical feasibility of endovascular treatment of dissecting vertebral artery aneurysms by use of both deconstructive (i.e., parent artery occlusion) (4) or reconstructive (i.e., stenting) (3) procedures has been documented recently. Grosso et al. describe a pediatric case of recurrent torticollis caused by a dissecting vertebral artery aneurysm, in whom proximal parent artery occlusion resulted in cure of symptoms of torticollis. This finding is remarkable, because endovascular treatment apparently did not result in a significant removal of aneurysmal mass effect, but rather in a reduced aneurysmal pulsation against adjacent nervous structures. Similarly, Drake (1) previously reported the "paradox of great improvement, even recovery, from severe brainstem compression" subsequent to intra-aneurysmal thrombosis after deliberate occlusion of the basilar artery and concluded that "removal of the pulse pressure and thrombosis must somehow reduce the size of the mass slightly but significantly, even in the first few weeks and even though there may not be much change in size in the computed tomographic scan." We also have recognized this effect in our series of very large and giant intracranial aneurysms, in which endosaccular embolization alone could result in neurological improvement in the signs of aneurysmal mass effect (2). The authors demonstrate again that clinical improvement from aneurysmal compressive mass effect may be attained without surgical debulking of the mass of the aneurysm in selected cases, and they extend this experience to the pediatric population.

**Andreas Gruber**  
Vienna, Austria  
**Bernd Richling**  
Salzburg, Austria

1. Drake CG: Giant intracranial aneurysms: Experience with surgical treatment in 174 patients. *Clin Neurosurg* 26:12-96, 1979.

2. Gruber A, Killer M, Bavinzski G, Richling B: Clinical and angiographic results of endovascular coiling treatment of giant and very large intracranial aneurysms: A 7-year, single-center experience. *Neurosurgery* 45:793-804, 1999.
3. Lylyk P, Cohen J, Ceratto R, Ferrario A, Miranda C: Combined endovascular treatment of dissecting vertebral artery aneurysms by using stents and coils. *J Neurosurg* 94:427-432, 2001.
4. Tsukahara T, Wada H, Satake K, Yaoita H, Takahashi A: Proximal balloon occlusion for dissecting vertebral aneurysms accompanied by subarachnoid hemorrhage. *Neurosurgery* 36:914-920, 1995.

Grosso et al. describe a condition rarely observed in the pediatric population. In addition to the effectiveness of the endovascular treatment, this case report presents several points of interest: the absence of any predisposing causative factor, which could have oriented the di-

agnosis, the peculiar and rather aspecific clinical presentation, and the reversibility of the clinical symptomatology even after a clinical history of 4 years. The result of the endovascular obliteration demonstrates the advantages of this therapeutic option to the surgical treatment in this special type of aneurysm. The nonspecific clinical presentation emphasizes the need of particularly careful diagnostic investigations in patients with recurrent torticollis. The reversibility of the clinical manifestations encourages active management even in patients who are apparently at high risk.

A further point of interest concerns the physiopathogenetic interpretation of the clinical picture. The signs and symptoms of brainstem and lower cranial nerve dysfunction that the patient ex-

hibited disappeared almost immediately after endovascular occlusion of the lesion, thus ruling out any organic damage to the neural structures. This result, which was observed despite the persistence of the mass effect of the aneurysm, suggests elaborate alternative pathogenetic mechanisms for the neurological manifestations that are different from the easy-to-accept mechanisms of compression and distortion of the neural structures by the vascular lesion. In this regard, the hypothesis proposed by the authors on the possible role of pulsatile forces exerted by the aneurysm and eliminated by its endovascular occlusion is interesting.

**Concezio Di Rocco**  
*Rome, Italy*

**Nurses observing an operation as part of their training at St. Luke's Hospital. 1899.**  
Courtesy, Museum of the City of New York.

