

Internal Carotid-Inferior Petrosal Sinus Fistula Complicating Foramen Ovale Telemetry: Successful Treatment with Detachable Coils: Case Report and Review

Laurence A.G. Marshman, F.R.C.S., Steven Connor, F.R.C.R., Charles E. Polkey, M.D.

Departments of Neurosurgery (LAGM, CEP) and Neuroradiology (SC), King's College Hospital, Denmark Hill, London, England

OBJECTIVE AND IMPORTANCE: Iatrogenic internal carotid artery-cavernous sinus fistula complicating percutaneous foramen ovale (FO) instrumentation (e.g., retrogasserian rhizotomy for trigeminal neuralgia) has been reported in only four patients to date. To our knowledge, no case of fistula has previously been reported either to complicate FO telemetry or to involve the inferior petrosal sinus (IPS); moreover, most patients have presented within 48 hours. We present a case of internal carotid artery-IPS fistula that complicated FO telemetry in which the clinical syndrome was delayed by 4 weeks.

CLINICAL PRESENTATION: Four weeks after undergoing bilateral FO telemetry during Phase 2 investigations for surgery for epilepsy, a 37-year-old man suddenly developed a painful bilateral pupil-sparing oculomotor palsy, poor visual acuity, proptosis, conjunctival suffusion, and an audible bruit over the right frontotemporal region.

INTERVENTION: Cerebral angiography demonstrated a high-flow arteriovenous fistula between the junction of the petrous and laceral portions of the right internal carotid artery and right IPS, with rapid filling of both cavernous sinuses. Successful obliteration was obtained with Guglielmi detachable coils, followed by complete resolution of the bilateral ocular abnormality.

CONCLUSION: This is the first reported case of iatrogenic fistula formation to either involve the IPS or to complicate FO telemetry. In addition, symptomatology was anomalously delayed. This case highlights the importance of noting FO anatomic asymmetries before FO instrumentation and of routinely inquiring for "swooshing" noises after electrode withdrawal. (*Neurosurgery* 50:209–212, 2002)

Key words: Arteriovenous fistula, Foramen ovale telemetry

Wieser et al. (17) first introduced foramen ovale (FO) telemetry in 1985 to aid in the localization and lateralization of seizure onset where nonin-

vative tests had previously incriminated one or both mesial temporal lobes. Smooth multicontact electrodes are inserted via an 18-gauge needle into

the ambient cistern, such that they lie between the mesial temporal lobe laterally and the brainstem medially (15–17). Used in this way, FO telemetry represents a compromise between more informative—but more invasive—subdural or intracerebral depth electrode monitoring and noninvasive—but less informative—scalp telemetry or neuroimaging studies. In principle, FO telemetry permits definitive surgery to be undertaken against a background of minimal preoperative investigative risk.

The senior author (CEP) has performed FO telemetry in more than 200 patients during the past 7 years. Complications were rare and concord in frequency with those reported by others (10, 15, 16). Nevertheless, a unique complication not previously documented was encountered that we herein report in detail.

CASE REPORT

First admission

A 37-year-old man was admitted in August 1998 for neurosurgical assessment of drug-resistant epilepsy. His first seizure was a tonicoclonic convulsion at the age of 17 years; since then, the majority of seizures were simple or complex partial in pattern, with only occasional secondary generalization. Attacks occurred at an average of eight per month and typically commenced with an epigastric aura, then lip smacking or other automatisms, before culminating in a backward fall and urinary incontinence. Normal consciousness was restored after variable lengths of postictal confusion. No episodes of status epilepticus had been recorded, and his longest seizure-free interval had been 2 years; however, a steady increase in seizure frequency had occurred in recent years. Therapy with a variety of anticonvulsants proved ineffective; at the time of his investigation, he was taking lamotrigine and topiramate.

Magnetic resonance imaging scans demonstrated decreased volume and high T2 signal in the right hippocampus consistent with mesial temporal sclero-

sis. Positron emission tomography with [^{18}F]fluorodeoxyglucose demonstrated a hypometabolic zone in the right anterior temporal lobe, a finding also consistent with right mesial temporal sclerosis. Scalp telemetry, however, revealed bilateral sharp waves in both anterior temporal regions, a finding inconsistent with a unilateral focus. Moreover, the results of neuropsychological tests suggested that language dominance lateralized to the right hemisphere. Bilateral FO telemetry was therefore undertaken to aid lateralization of the primary focus.

Bilateral six-contact Teflon-insulated FO electrodes (0.11 mm in diameter) were implanted under fluoroscopic control while the patient was under general anesthesia. The electrodes were placed into each ambient cistern through an 18-gauge needle as previously described (3, 15–17). No complication was encountered during this procedure; in particular, no excessive hemorrhage was apparent. The patient awoke from the anesthetic without obvious neurological change, and his anticonvulsant medication was thereafter tapered. Postoperative cranial x-rays confirmed adequate electrode positioning. Subsequent continuous 32-channel video electroencephalogram telemetry, performed between August 11 and August 20, 1998, recorded five complex partial seizures, each consistent with a right temporal lobe focus.

Both electrodes were subsequently removed without event while the patient was under general anesthesia, and he was discharged home 2 days later. In retrospect, however, a “swooshing” noise had been subjectively audible immediately after electrode removal. No dramatic cardiovascular fluctuation was found retrospectively from further study of his observation charts at either FO needling or at the time of electrode withdrawal.

Second admission

Four weeks after discharge, the patient suddenly reported ptosis and diplopia in the right eye, although visual acuity remained preserved. Apart from mild retro-orbital pain and tinnitus, no other abnormality was noted. Examina-

tion disclosed a partial, pupil-sparing, right oculomotor palsy that rapidly progressed within days to complete, bilateral, pupil-sparing oculomotor paralysis with bilaterally complete ptosis. Both eyes were red and proptosed, and a soft systolic bruit was audible over the right frontotemporal region. No other neurological abnormality was noted. A clinical diagnosis of carotidocavernous sinus fistula was made, and the patient was admitted for further investigation.

Cerebral angiography demonstrated a high-flow arteriovenous fistula between the junction of the petrous and lateral portions of the right internal carotid artery (ICA) and the right inferior petrosal sinus (IPS) (Fig. 1). There was rapid filling of both the cavernous sinus (CVS) and inferior ophthalmic veins; however, no cortical venous reflux was demonstrated. Guglielmi detachable coiling (GDC; Target Therapeutics, Fremont, CA) for embolization of the arteriovenous fistula was thereafter immediately instituted via the femoral artery. After a 6-French guide catheter was positioned within the proximal right ICA, a microcatheter was advanced through the fistulous communication into the right CVS. Through this microcatheter, both the CVS and IPS were packed with six GDC coils in retrograde fashion. The subsequent embolization dramatically reduced fistulous flow, with only minimal residual IPS filling (Fig. 2). After the procedure, a rapid and complete resolution of the bilateral ophthalmoplegia was obtained.

Third admission

The excellent clinical result remained unchanged at 16 months' review, whereupon, at a third admission, a right

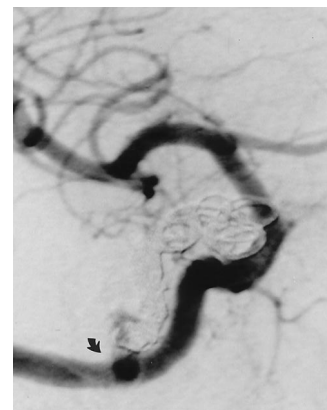

FIGURE 2. Posttreatment (GDC) right ICA angiogram, frontal projection. Only minor residual flow from the fistula into the right IPS (arrowhead) is now apparent. The GDC ball extends from the right CVS and into the right IPS.

temporal lobectomy was successfully performed, resulting in complete cessation of seizure activity. The patient experienced no further complications. The resected specimen revealed features typical of mesial temporal sclerosis.

DISCUSSION

FO telemetry is typically free of complications. Minor symptoms commonly reported relate to transient ipsilateral trigeminal nerve damage. These include hypoesthesia or dysesthesia at one corner of the mouth, brief contractions of the ipsilateral masseter (16), or lancinating ipsilateral dental pain after electrode withdrawal (10, 16). Occasionally, more serious and permanent trigeminal damage has been reported (including, anecdotally, trigeminal avulsion) (10, 15–17). Such complications probably relate to multiple insertion attempts (the practice of CEP is to limit such attempts to two).

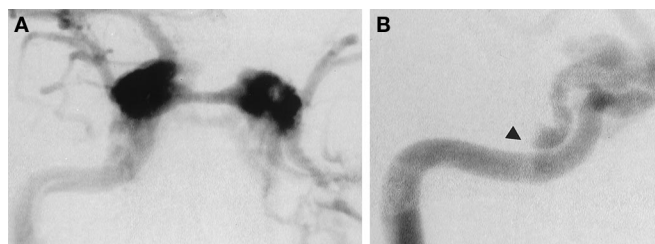


FIGURE 1. Pretreatment right common carotid angiograms. A, frontal projection. B, right anterior oblique projection (early arterial phase). A high-

flow fistula is present between the junction of the petrous and lateral portions of the right ICA and the cranial portion of the right IPS (arrowhead). Rapid shunting is apparent into both CVSs and ophthalmic veins.

More rarely, oculomotor, trochlear, or even abducens nerve damage has been reported, as has meningitis (4, 7, 10, 15, 16).

Significant intracranial hemorrhage (or ischemia) has also been reported with FO instrumentation, including FO telemetry (1, 9, 10, 12, 13, 15, 16). Furthermore, four cases of iatrogenic ICA-CVS fistula have also complicated percutaneous FO instrumentation (5, 6, 11) (the case of Revuelta et al. [8] strictly involved the external carotid artery). Frank operative hemorrhage, then a postoperative swooshing noise, typified these fistulae. No fistulae, however, have directly involved the IPS (Bartlow and Penn's [2] traumatic case indirectly involved the superior petrosal sinus via the CVS), and none has complicated FO telemetry. Our case therefore seems to be the first iatrogenic fistula either to directly involve the IPS or to complicate FO telemetry.

The FO and carotid canal are intimately related at the cranial base in the middle cranial fossa. Anatomic variants—such as a foramen of Vesalius or Arnold (14) or a primitive foramen lacerum medius (11) (a defect in the foramen lacerum allowing communication with the FO)—predispose the patient to ICA needle puncture during FO instrumentation. Although none of these variants was present in the patient we studied, a definite asymmetry in FO contour was apparent, with the right FO possessing a considerably thinner posterior wall than that of the left (Fig. 3). This could have permitted ICA (and subsequently rostral IPS) penetration. FO asymmetry should therefore always be borne in mind before contemplating percutaneous instrumentation.

An unusual feature of the clinical presentation of this patient was the 4-week delay in ocular symptomatology after electrode removal. Most ICA-CVS fistulae complicating FO instrumentation have presented within 2 days of the causative procedure (6, 11). Gokalp et al. (5), however, reported a case that presented 12 days after percutaneous trigeminal rhizotomy, whereas Bartlow and Penn (2) reported a traumatic fistula that developed 12 years after an automobile accident (although a swooshing noise had been subjectively audible transiently closer to the

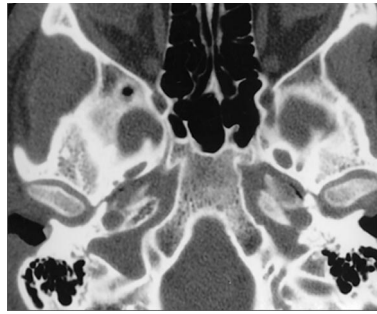


FIGURE 3. Fine section cranial base computed tomographic scan (bone windows). The right FO is more slender than the left and possesses a much thinner posterior wall. Such asymmetrical anatomy could predispose to ICA penetration during FO instrumentation.

time of injury). The anomalous delay in such cases could be explained by initial pseudoaneurysm formation before fistula formation. Alternatively, in the case of the fistula we studied, the apparent delay could have related to gradual IPS thrombosis that, with complete IPS occlusion, resulted in fistulous flow being redirected anteriorly into both CVS and ophthalmic veins. Such a mechanism is suggested by poor opacification of the ipsilateral IPS on diagnostic angiography (Fig. 1).

FO telemetry successfully lateralized the primary epileptogenic focus in the patient we studied. In consequence, a definitive right temporal lobectomy was indicated—and successfully performed—with complete resolution of seizure activity. The need for more invasive subdural (or intracerebral depth electrode) telemetry was therefore obviated. Nevertheless, a serious complication occurred in a procedure ordinarily considered only moderately invasive. Its anticipation and early investigation are emphasized—especially in instances in which patients have reported a subjective swooshing noise after FO instrumentation (11). In addition, anatomic asymmetry in FO contour should always be borne in mind whenever FO instrumentation is being contemplated.

ACKNOWLEDGMENTS

We thank Devi Amin, Department of Neurophysiology, for her kind help in the production of the article. This article was significantly contributed to by all

named authors and was not supported by any external funds. No conflict of interest is present.

Received, December 13, 2000.

Accepted, August 24, 2001.

Reprint requests: Laurence A.G. Marshman, F.R.C.S., Department of Neurosurgery, King's College Hospital, Denmark Hill, London SE5 9RS, England.

Email: l.a.g.marshman@btinternet.com

REFERENCES

1. Apfelbaum RI: Subarachnoid hemorrhage and "normal pressure hydrocephalus": Fatal complication of percutaneous microcompression of the Gasserian ganglion—Case report. *Neurosurgery* 22:150–151, 1988 (comment).
2. Bartlow B, Penn RD: Carotid-cavernous fistula presenting as a posterior fossa mass: Case report. *J Neurosurg* 42:585–588, 1975.
3. Fernandez Torre JL, Alarcon G, Binnie CD, Polkey CE: Comparison of sphenoidal, foramen ovale and anterior temporal placements for detecting interictal epileptiform discharges in presurgical assessment for temporal lobe epilepsy. *Clin Neurophysiol* 110:895–904, 1999.
4. Fujita Y, Nakazaki K: Complications of alcohol injection into the mandibular nerve: Gasserian palsy and oculomotor palsy [in German]. *Reg Anaesth* 5:39–41, 1982.
5. Gokalp HZ, Kanpolat Y, Turner B: Carotid-cavernous fistula following percutaneous trigeminal ganglion approach. *Clin Neurol Neurosurg* 82:269–272, 1980.
6. Kuether TA, O'Neill OR, Nesbit GM, Barnwell SL: Direct carotid cavernous fistula after trigeminal balloon microcompression gangliolysis: Case report. *Neurosurgery* 39:853–856, 1996.
7. Markakis E: Transitory fourth cranial nerve palsy due to foramen ovale electrode placement. *Acta Neurochir (Wien)* 139:789–790, 1997.
8. Revuelta R, Nathal E, Balderrama J, Tello A, Zenteno M: External carotid artery fistula due to compression of the gasserian ganglion for relief of trigeminal neuralgia: Case report. *J Neurosurg* 78:499–500, 1993.
9. Rish BL: Cerebrovascular accident after percutaneous radiofrequency thermocoagulation of the trigeminal ganglion: Case report. *J Neurosurg* 44:376–377, 1976.
10. Schüler P, Stefan H, Neubauer U, Schulemann H: Vergleich von foramen ovale und subduralen streifenektroden zur präoperativen epilepsiediagnostik. Presented at the 36th Annual Meeting German EEG-Society, 10–13 Celle, 1991, p 152 (abstr).
11. Sekhar LN, Heros RC, Kerber CW: Carotid-cavernous fistula following percutaneous retrogasserian procedures: Report of two cases. *J Neurosurg* 51:700–706, 1979.
12. Spaziante R, Cappabianca P, Peca C, de Divitiis E: Subarachnoid hemorrhage and "normal pressure hydrocephalus": Fatal complication of percutaneous microcompression of the Gasserian ganglion—Case report. *Neurosurgery* 22:148–151, 1988.

13. Sweet WH: Dangerous rises in blood pressure upon heating of trigeminal rootlets: Increased bleeding times in patients with trigeminal neuralgia. *Neurosurgery* 17:843-844, 1985.
14. Sweet WH: Treatment of trigeminal neuralgia by percutaneous rhizotomy, in Youmans JR (ed): *Neurological Surgery: A Comprehensive Reference Guide to the Diagnosis and Management of Neurological Problems*. Philadelphia, W.B. Saunders Co., 1990, vol 6, ed 3, pp 3888-3921.
15. Wieser HG: Semi-invasive EEG: Foramen ovale electrodes, in Lüders H (ed): *Epilepsy Surgery*. New York, Raven Press, 1991, pp 361-370.
16. Wieser HG, Hajek M: Foramen ovale and peg electrodes. *Acta Neurol Scand Suppl* 152:33-35, 1994.
17. Wieser HG, Elger CE, Stodieck SRG: The foramen ovale electrode: A new recording method for the pre-operative evaluation of patients suffering from mesio-basal temporal lobe epilepsy. *Electroencephalogr Clin Neurophysiol* 66:314-322, 1985.

COMMENTS

The authors report an unusual case of iatrogenic carotid-cavernous fistula caused by an injury to the carotid artery induced by foramen ovale (FO) electrodes. As the authors point out, the intimate relationship between the FO and the carotid canal creates the potential for this complication with any instrumentation involving the FO. An iatrogenic carotid-cavernous fistula has been reported as a complication of percutaneous procedures for the treatment of trigeminal neuralgia, but this is the first report of this complication occurring from FO telemetry during an evaluation for epilepsy. The authors note that asymmetry of the patient's FO may have contributed to this complication because the foramen on the side ipsilateral to the injury was more slender and

had a thin posterior wall. Such asymmetry or other anatomic variants should be analyzed before placement of FO instrumentation to reduce the likelihood of this complication.

I suspect that the delayed onset of this patient's symptoms were due to gradual thrombosis of the inferior petrosal sinus and an alteration in the venous drainage of the fistula, which is the primary determinant of symptoms in patients with carotid cavernous fistulae.

Daniel L. Barrow
Atlanta, Georgia

The authors report an interesting and rare complication of FO telemetry. An internal carotid-inferior petrosal sinus fistula developed after the FO electrodes were removed. The fistula was successfully treated with coil embolization. The authors stress the need for careful pre-operative evaluation of anatomic asymmetry in FO and the importance of the patient's subjective complaints, such as the presence of a "swooshing" noise after removal of the electrodes.

Demetrius K. Lopes
Chicago, Illinois
L. Nelson Hopkins
Buffalo, New York

In this article, Marshman et al. describe a single case of an arteriovenous fistula occurring after FO electrodes were placed for evaluation of epilepsy. A few cases are described in the literature regarding such fistulae after trigeminal neuralgia procedures, but the patient that the authors describe seems

to have some other features that may have been a complication of the electrodes—and may even have come from the act of removing the electrodes. The fistula involved the inferior petrosal sinus and seemed to drain secondarily into the cavernous sinus; the patient presented 4 weeks after the instrumentation.

This is a good description of a rare complication of a common procedure. The authors suggest that anatomic variants in the shape of the FO may play a role in this predilection. They do not provide much advice as to how to avoid this complication if an abnormal FO is identified. The treatment with Guglielmi detachable coiling was successful, with only minimal residual. It is not clear why the authors took 16 months after this procedure to proceed with definitive treatment of the epilepsy, but the presence of the fistula did not seem to affect the successful epilepsy treatment.

Probably the most pertinent information in this study is the suggestion that clinical symptomatology may be delayed in appearance. This does not necessarily mean that the injury may not present immediately, but pseudoaneurysm formation or delayed thrombosis of an earlier fistula may predispose the patient to delayed presentation. The article would have been improved by including a discussion of what steps may be taken to avoid this complication if an anatomic variant is recognized.

Robert J. Dempsey
Madison, Wisconsin

Congress of Neurological Surgeons' Mission Statement

"The Congress of Neurological Surgeons exists for the purpose of promoting the public welfare through the advancement of neurosurgery, by a commitment to excellence in education, and by dedication to research and scientific knowledge. The Congress of Neurological Surgeons maintains the vitality of our learned profession through the altruistic volunteer efforts of our members and the development of leadership in service to the public, to our colleagues in other disciplines, and to the special needs of our fellow neurosurgeons throughout the world and at every stage of their professional lives."