

# Chorea, polycythaemia, and cyanotic heart disease

P. D. EDWARDS, R. PROSSER, AND C. E. C. WELLS

From the Department of Paediatrics, Royal Gwent and St. Woolos Hospitals, Newport, Gwent, and Department of Neurology, University Hospital of Wales, Cardiff

**SYNOPSIS** Two cases of polycythaemic chorea are described, both of which were complicated by severe heart disease. The first was a child with patent ductus arteriosus and coarctation of the aorta causing severe cyanosis and secondary polycythaemia. Chorea began intermittently at an early age, becoming continuous by his fifth birthday. The second was a middle-aged male with tight mitral stenosis and a story of paralytic chorea in his teens. Polycythaemia rubra vera was eventually diagnosed two years after mitral valvotomy, some seven years after the onset of chorea.

## 1. Chorea, polycythaemia, and morbus coeruleus

P. D. EDWARDS, R. PROSSER, AND C. E. C. WELLS

Congenital heart disease with a right-to-left shunt is the most common cause of polycythaemia in children. The vital signs are stunted growth, central cyanosis with bloodshot eyes and crimson lips, and clubbing. The number of red blood cells, the haematocrit and haemoglobin concentration are all elevated and the oxygen saturation of arterial blood is decreased. The haemoglobin and haematocrit levels, which may exceed 16 g/dl and 55% respectively, then correspond to a red cell mass greater than 35 ml/kg.

The natural history of polycythaemia is often studied with neurological episodes: transient ischaemic attacks or a frank stroke are typical presenting symptoms. The complications of polycythaemia rubra vera, reviewed in full by d'Eramo and Levi (1972), do not differ from those of polycythaemia which is secondary to hypoxia or to increased production of erythropoietin. Chorea is a rare manifestation. In the past 65 years it has been recorded in little more than a score of cases, mostly middle-aged or elderly females (Table 1), although the incidence of polycythaemia vera is greater in men (Wintrobe, 1967).

Chorea associated with secondary polycythaemia has been reported in a child. Polani and MacKeith (1954) described a 4 year old girl with

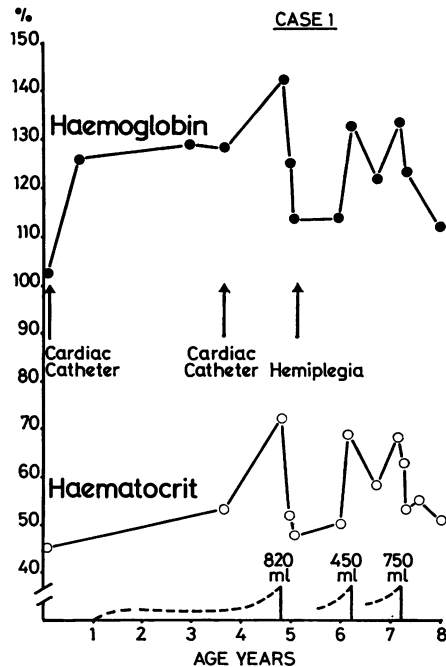


FIG. 1 Case 1. Chart showing relationship of major neurological syndromes to levels of haemoglobin and haematocrit, and the influence of venesection.

---: chorea. —: venesection.

TABLE 1  
CASES OF POLYCYTHAEMIA AND CHOREA PREVIOUSLY REPORTED IN JOURNALS CIRCULATING IN GREAT BRITAIN

| <i>Date</i> | <i>Authors</i>                     | <i>Sex</i> | <i>Age (yr)</i> | <i>History, treatment, progress</i>  | <i>F.U.</i> |
|-------------|------------------------------------|------------|-----------------|--|-------------|
| 1909        | Bardachzi (case 1)                 | F          | 59              | Abrupt onset of chorea, beginning in R hand, chiefly of face, tongue, limbs, with dysarthria and ataxia. Severe headache. Splenic infarct, skin haemorrhages, boils, carbuncle of sacrum. Hb 135%, RBC $14 \cdot 10^{12}$ , WBC $27 \cdot 10^9/l$ , splenomegaly. Remission of chorea, clearing of sepsis after sodium iodide therapy. Hb 115%, RBC $8.56 \cdot 10^{12}/l$ , splenomegaly  | 5 m         |
| 1909        | Umney                              | F          | 34              | For 5 yr increasingly livid complexion; then abortion, menorrhagia, persistent albuminuria. Hb 138%, RBC $11.5 \cdot 10^{12}$ , WBC $17 \cdot 10^9/l$ , splenomegaly. After 2 yr speech indistinct, onset of chorea and thrombosis of left innominate vein. Chorea subsided with phenazone therapy. Within 3 m generalized venous thrombosis, death in coma. No necropsy   | 3 m         |
| 1919        | Naville and Brüttsch (case 1)      | F          | 33              | Relapsing chorea aged 19–22 yr. Abrupt loss of consciousness for 3 d and R hemiplegia at 23 yr. Onset of epilepsy at 31 yr. Failing vision with papilloedema, consecutive optic atrophy at 33 yr. Hb 100%, RBC $6.758 \cdot 10^{12}$ , WBC $16.43 \cdot 10^9/l$ splenomegaly. Laparotomy for obstruction: splenic 'tumor' not excised  | 14 yr       |
| 1922        | Pollock                            | F          | 38              | For 6 m attacks of headache, dizziness, cyanosis, dyspnoea; relieved by radio-therapy. 3 w, speech indistinct, grimacing, involuntary movements of jaws, tongue, limbs. Hb 115%, RBC $8.1 \cdot 10^{12}$ , WBC $8.5 \cdot 10^9/l$ , splenomegaly. Remission of chorea after venesections and radio-therapy. RBC $6.4 \cdot 10^{12}/l$ , splenomegaly   | 3m          |
| 1933        | Schiff and Simon                   |            |                 |  |             |
| 1936        | Schiff <i>et al.</i>               | F          | 78              | Transient flaccid tetraparesis at 73 yr. Over next 5 yr increasing lividity. Hb 90%, RBC $6.8 \cdot 10^{12}$ , WBC $16 \cdot 10^9/l$ . 6 w later, sudden onset of chorea of face, trunk, limbs, with confusion, disorientation, drowsiness. Ataxia and scanning speech. Xanthochromic CSF. Death within months<br>P.M.: congestion of cerebral veins with some thromboses, demyelination of anterior globus pallidus, degeneration of hypothalamic nuclei, and loss of Purkinje cells from cerebellar cortex   | 2 m         |
| 1940        | Dameshek and Henstell (case 7)     | M          | 39              | For 1 yr inappropriate sleep, loss of concentration, irritability. Recent dizziness, nausea. Involuntary movements of arms, legs. Hb 150%, RBC $8.7 \cdot 10^{12}$ , WBC $12 \cdot 10^9$ , platelets $800 \cdot 10^9/l$ , PCV 80%, splenomegaly. Symptomatic relief with low iron diet   | —           |
| 1940        | Dameshek and Henstell (case 8)     | F          | 49              | Twitching of fingers, orofacial dyskinesia began 2 yr after complaint of headaches, hot flushes, vertigo, tinnitus. Superficial venous thrombosis. Hb 118%, RBC $10.2 \cdot 10^{12}$ , WBC $10.8 \cdot 10^9$ , platelets $2.5 \cdot 10^{12}/l$ , splenomegaly. Symptoms subsided after venesection and treatment with arsenic, phenylhydrazine, low iron diet  | —           |
| 1942        | Kotner and Tritt                   | F          | 64              | For 5 yr symptomless polycythaemia: Hb 130%, RBC $9.4 \cdot 10^{12}$ , WBC $12.7 \cdot 10^9/l$ . Ulcer of mouth after dental extraction and chorea involving face, mouth, trunk, limbs. Explosive speech. Hb 130%, RBC $9.5 \cdot 10^{12}$ , WBC $16.5 \cdot 10^9/l$ , PCV 76%, splenomegaly. Xanthochromic CSF. Despite venesection, rapid deterioration and death on 9th day<br>P.M.: pulmonary, mesenteric thrombi; congestion of all cerebral veins with multiple thrombi, choroidal haemorrhage of 4th ventricle; perivenous demyelination. No areas of necrosis or cell loss | 7 w         |
| 1946        | Reinhard <i>et al.</i> (case 19)   | F          | 56              | Nervous for many years, dizziness and nausea for 1 yr, chorea and dysarthria for 1 m. Mother had polycythaemia. Chorea improved after venesection and <i>before</i> radiophosphorus therapy  | 1 m         |
| 1950        | Harvier <i>et al.</i>              | M          | 49              | For 7 yr 'writer's cramp', mild dysarthria. Bleeding gums. 6 yr, joint pains followed by onset of chorea beginning in lips and tongue. Hb 128%, RBC $7.0 \cdot 10^{12}/l$ splenomegaly. Therapy with Boudin's solution. Chorea fluctuated, tending to worsen. Hb 150%, RBC $8.3 \cdot 10^{12}$ , WBC $28.4 \cdot 10^9/l$ . Further therapy with Boudin's solution, phenylhydrazine, and radiotherapy. Gradual remission of chorea. Final Hb 137%, RBC $6.2 \cdot 10^{12}$ , WBC $18.2 \cdot 10^9/l$  | 8½ yr       |
| 1952        | Alajouanine <i>et al.</i> (case 4) | F          | 65              | Livid complexion for 4 yr. Rapid onset of involuntary movements of face, arms, trunk, together with Parkinsonian tremor of hands. RBC $9.9 \cdot 10^{12}/l$ , splenomegaly. Remission followed venesection and radiophosphorus therapy.  | 3½ yr       |
| 1954        | Trotsenburg and Koster             | F.         | 63              | For 18 m involuntary movements chiefly of right side with orolingual dyskinesia, dysarthria, and right hemiparesis. Hb 140%, RBC $7.8 \cdot 10^{12}$ , WBC $7.0 \cdot 10^9/l$ , platelets $700 \cdot 10^9/l$ , PCV 61%, splenomegaly. After radiophosphorus therapy, remission of chorea apparent 1 m before fall of haemoglobin and red cell count  | 3 yr        |

TABLE 1—*contd*

| Date | Authors                                | Sex | Age (yr) | History, treatment, progress   | F.U.  |
|------|--|-----|----------|--|-------|
| 1958 | Paliard <i>et al.</i><br>(case 1)      | M   | 73       | After disappointment 9 m before, rapid onset of abnormal movements of arms and of slurred speech. RBC $7.8 \cdot 10^{12}/l$ , splenomegaly. Remission within few months of radiophosphorus therapy. Relapse after 4 yr, involving all four limbs, face, tongue, with rhythmic myoclonus of pharynx and larynx. RBC $4.8 \cdot 10^{12}/l$ , and no splenomegaly. Remission with chlorpromazine. Severe relapse after 5 m: Hb 140%, RBC $7.45 \cdot 10^{12}/l$ , PCV 77%. Gradual remission after radiophosphorus. Final Hb 80%, RBC $4.0 \cdot 10^{12}/l$ , slight splenomegaly   | 5½ yr |
| 1959 | Calabresi and Meyer                    | —   | —        | 'One case had choreoathetoid movements with speech impairment . . .'   | —     |
| 1962 | Bogolepov                              | M   | 70       | Polycythaemic for 10 yr. 4 yr ago nocturnal epileptic fit followed by chorea with orofacial predominance (illustrated). Remission after venesection and radiophosphorus therapy. 3 yr later, further relapse, trophic lesions of several fingers. Further remission with therapy. Final Hb $4.62 \cdot 10^{12}$ , platelets $254 \cdot 10^9/l$   | 4 yr  |
| 1963 | Bakke and Stavem                       | F   | 74       | After complaint of dizziness, developed involuntary movements of hand, arm, becoming generalized within 3 m. Staccato speech and abnormal gait. Hb 18.4%, RBC $7.7 \cdot 10^{12}$ , WBC $18.4 \cdot 10^9$ , platelets $250 \cdot 10^9/l$ , splenomegaly. Little change after venesection   | 2 yr  |
| 1965 | Friedemann <i>et al.</i>               | F   | 62       | One year after chance finding of raised haemoglobin, onset of malaise, pain in mouth and tongue, and of involuntary movements beginning in tongue and rapidly becoming generalized. Hb 18.5%, RBC $6.5 \cdot 10^{12}/l$ , WBC and platelets not increased. Total red cell volume 43.6 ml/kg. Within 2 m of venesection, radiophosphorus therapy, chorea had disappeared, remission preceding significant fall of blood count   | 9 m   |
| 1967 | Gautier-Smith and Prankerd<br>(case 1) | F   | 57       | Sydenham's chorea at age 12 yr. Onset of headaches, drop attacks, vertigo, amblyopia at 53 yr followed after 4 yr by increasing fidgetiness. Chorea chiefly of face, tongue, and upper limbs, jerky respirations, grunting speech. Hb 22.2 g/dl, RBC $8.02 \cdot 10^{12}$ , WBC $18.1 \cdot 10^9$ , platelets $450 \cdot 10^9/l$ , PCV 77%, splenomegaly. Red cell mass 81.1 ml/kg. After venesection and radiophosphorus therapy, remission of chorea preceded that of polycythaemia. Temporary relapse of chorea—RBC $8.92 \cdot 10^{12}/l$ —responding well to further venesection and radiophosphorus. Final Hb 16.0 g/dl, PCV 54%   | 18 m  |
| 1967 | Gautier-Smith and Prankerd<br>(case 2) | F   | 74       | Sudden onset dysphagia and dysarthria, confusion and chorea, deteriorating after 5 m. Hb 23.0 g/dl, WBC $8.3 \cdot 10^9$ , platelets $650 \cdot 10^9/l$ , PCV 73%. No splenomegaly. Red cell mass 65 ml/kg. Remission of chorea and general improvement after radiophosphorus therapy. Final Hb 14.0 g/dl, WBC $6.5 \cdot 10^9$ , platelets $143 \cdot 10^9/l$   | 13 m  |
| 1968 | Bietti <i>et al.</i>                   | F   | 75       | Polycythaemia diagnosed at age 56 yr and treated with radiotherapy. Further therapy at 72 yr for sciatica and at 74 yr after haemorrhages into skin. Regular venesection. After a short lapse of therapy, onset of involuntary movements of left hand and episodes of unconsciousness. RBC $8.0 \cdot 10^{12}/l$ . Progression of chorea to whole of right side and explosive speech. Hb 17.3 g/dl, RBC $7.8 \cdot 10^{12}$ , WBC $14.5 \cdot 10^9$ , platelets $360 \cdot 10^9/l$ . Died 1 m after radiophosphorus therapy. Final RBC $6.64 \cdot 10^{12}$ , platelets $320 \cdot 10^9/l$<br>P.M.: distended intracranial veins with thrombi of smaller vessels and haemorrhage of L putamen; areas of perivascular demyelination; large subdural haematoma | —     |
| 1968 | Heathfield                             | F   | 77       | Six month story of chorea involving face, tongue, limbs. Hb 18.5 g/dl, PCV 66%; 1 m later RBC $8.0 \cdot 10^{12}$ , WBC $8.8 \cdot 10^9$ , platelets $320 \cdot 10^9/l$ , PCV 64%, no splenomegaly. Chorea controlled by venesection and thiopropazate therapy   | 9 m   |
| 1969 | Nehlil <i>et al.</i>                   | F   | 70       | Onset of generalized chorea involving face, tongue, limbs at age 68 yr. RBC $7.03 \cdot 10^{12}/l$ , increased WBC, PCV 70%, no splenomegaly. Remission after venesection. Relapse after 2 yr with marked orofacial dyskinesia and dysarthria. Further remission after therapy with cytotoxic drug and haloperidol   | 2 yr  |
| 1970 | Sangster                               | F   | 71       | Six weeks after onset of giddy turns, spontaneous jerking movements of face and limbs with dysarthria. Became rapidly helpless. Hb 24.9 g/dl, RBC $8.63 \cdot 10^{12}$ , WBC $15.6 \cdot 10^9$ , platelets $120 \cdot 10^9/l$ . Total red cell volume 68 ml/kg. No splenomegaly. Immediate improvement after venesection and radiophosphorus therapy. Temporary relapse with worry. Final RBC $5.5 \cdot 10^{12}$ , platelets $100 \cdot 10^9/l$   | 2 m   |
| 1972 | Ashenhurst                             | M   | 68       | Onset of involuntary movements 7 yr after diagnosis of polycythaemia rubra vera (Hb 21.2 g/dl, WBC $6.0 \cdot 10^9$ , platelets $500 \cdot 10^9/l$ , PCV 65.5%) which was treated by venesection. Recurrence of polycythaemia after 5 yr treated by venesection and radiophosphorus, last dose being given 2 w before onset of chorea when Hb 18.0 g/dl. Chorea settled within 10 d of further venesection. Final Hb 12.7 g/dl, RBC $4.7 \cdot 10^{12}/l$  | 2 m   |

F.U. = follow-up from onset of chorea; yr = year, m = month, w = week

Fallot's tetralogy who became anoxic and hemiplegic during angiocardiology and, eight days later, developed choreoathetosis which persisted over the next two years. The abnormal movements were probably due to infarction of the upper brainstem.

In the following account of a boy with severe cyanotic heart disease and secondary polycythaemia, chorea and cerebral thrombosis were major complications. On two occasions his chorea subsided after substantial venesection but his hemiplegia persisted.

#### CASE 1

M.P. was born normally at term on 24 November 1965 after an uneventful gestation. He weighed 2 867 g. At the end of the first week his left arm, both legs, and the lower part of his body were seen to be deeply cyanosed whenever he cried. A soft systolic murmur was audible over the precordium. The femoral pulses were palpable but were weak. The systolic blood pressure was 130 mmHg in his right arm and 150 mmHg in his left. The clinical diagnosis of preductal coarctation of the aorta and patent ductus arteriosus was supported by catheter studies (Dr. L. G. Davies).

Respiratory infections were frequent and led to many admissions to hospital. Because of the risk of congestive heart failure, digoxin was started. When the child was 3 years old, Dr Davies repeated the catheter studies and confirmed his earlier findings. He also reported severe pulmonary hypertension with a right-to-left shunt through the patent ductus. In the right brachial artery oxygen saturation reached 95% but in the abdominal aorta it fell to 60%. The severity of his pulmonary hypertension excluded him from surgery.

Chorea was first seen in the paediatric outpatient clinic in 1970 when he was nearly 5 years old. With prompting, his mother then recalled having noticed occasional spells of involuntary movements since his first birthday. They were present only when he was awake, lasting a few hours at a time, and subsiding as soon as he fell asleep. They had been continuous for two months: his face would screw up, his tongue dart in and out, his grip become weak and clumsy, and he would drop things unexpectedly. More recently, his walking and balance had been affected and during the past fortnight he had been off his feet.

He was small for his age and deeply cyanosed. Finger clubbing, like the degree of cyanosis, was more intense in his left hand than in his right and was marched by similar changes in his feet. Chorea

was generalized and his speech was slurred, his words being either explosive or distorted by frequent grimacing. His limbs were hypotonic, the knee jerks pendular and 'hung up', the plantar responses flexor. Although the retinal veins were congested, the optic discs were flat. The cardiovascular signs were unchanged and both liver and spleen were easily palpable, the former extending four fingers' breadth below the costal margin. All peripheral pulses were present. Serial blood counts over the previous four

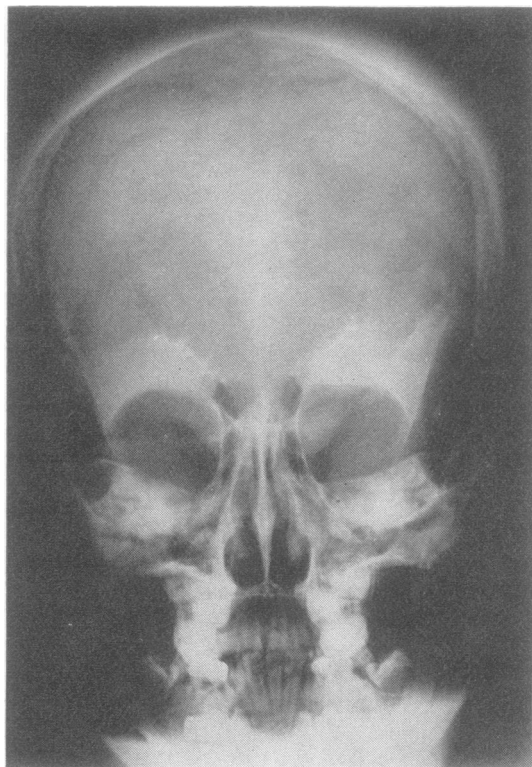


FIG. 2 Case 1. Skull showing abnormal density of vault due to hyperplasia of bone marrow.

years revealed increasing polycythaemia (Fig. 1) and a skull radiograph showed abnormal density of bone in vault and base (Fig. 2).

After repeated venesection—a total of 820 ml blood being withdrawn in a fortnight—he was able to walk again and his chorea subsided. The haemoglobin and haematocrit had then fallen to levels just above the normal range (Fig. 1). Within a month of

leaving hospital he was readmitted with another chest infection, during the course of which he developed right-sided weakness. Despite anticoagulant therapy, this progressed over the next four days to become a dense hemiplegia. His blood count had not altered. During the next two years further respiratory infections, sometimes associated with cardiac failure, responded to conventional therapy with digoxin,

frusemide, and antibiotics. Anticoagulant therapy with warfarin was continued. At the beginning of 1973, when he was aged 7 years, his chorea relapsed but again subsided after a second series of venesections. The initial haematocrit reading of 66% fell to normal levels within a month of withdrawing 750 ml blood (Fig. 1). His hemiplegia, however, remained dense.

## 2. Chorea, polycythaemia, and mitral stenosis

C. E. C. WELLS

Discussing the differences between polycythaemia rubra vera (erythraemia), a disease of unknown aetiology, and polycythaemia in response to a known stimulus (erythrocytosis), Wintrobe (1967) admitted that the distinction between the two was not always clear and that the expected splenomegaly, leucocytosis, and thrombocytosis of polycythaemia vera might be missing from an otherwise typical case. Glass and Wasserman (1972) listed 13 criteria by which they classified primary, secondary, and spurious types of polycythaemia but their table revealed the same overlap which Wintrobe (1967) had found.

The following case history describes a middle-aged man who presented with chorea and was found to have tight mitral stenosis. Respiratory function was also impaired. A mild degree of polycythaemia, affecting only the red cell series, was for many years attributed to his considerable hypoxia. When polycythaemia vera was diagnosed and treated accordingly, control of his chorea became simpler but complete remission was not achieved. Permanent structural injury may have resulted from the combined effects of venous congestion and long-continued therapy with phenothiazines grafted onto a striatum already weakened by Sydenham's chorea in adolescence.

### CASE 2

In October 1959 a 45 year old man was brought to casualty with a crush injury of his left forearm. The skin and soft tissue were intact, the circulation normal, and no signs of bone injury were found. He soon returned to his work as a machine operator but became depressed and continued to complain about his

arm. Perphenazine was prescribed and he stayed at work with occasional breaks for the next two years. In November 1961 a series of bereavements led to relapse of his depression and to the onset of chorea. He was admitted to a psychiatric hospital where change of therapy first to chlorpromazine and then to trifluoperazine, with benzhexol, seemed to control the movements and the depression. Later, Huntington's chorea was suspected and he was referred for neurological opinion.

His wife reaffirmed his story but quickly dispelled doubts about an inherited disorder. She had known his parents and grandparents as well as his three sisters and none had had chorea or been demented. His eldest sister had had rheumatic fever in her teens and was subject to fainting turns. Of their own three children, the two boys were well but their daughter had had varicella encephalitis, diagnosed by an experienced paediatric neurologist, and was left with a speech defect. She attended a school for handicapped children and had been examined in the neurological clinic when the family first moved to Wales from London.

Additional points from the past history were confirmed by the family doctor's records. Paralytic chorea of his right leg had been diagnosed in November 1932 and between that date and July 1933, when he had resumed work as a baker's roundsman, involuntary movements of his face and limbs had been recorded. During war service in West Africa he had had malaria but had otherwise remained well until his accident in 1959 to which all his present ills were attributed. From 1948 onwards he had frequented the surgery with minor complaints and at the time of a febrile illness in 1955 he had complained of pain below the left costal margin. His spleen had not been palpable. In January, February, and November 1961 he had had nocturnal epileptic fits and had also had a number of minor episodes in which he became confused, sweated profusely, and afterwards mentioned

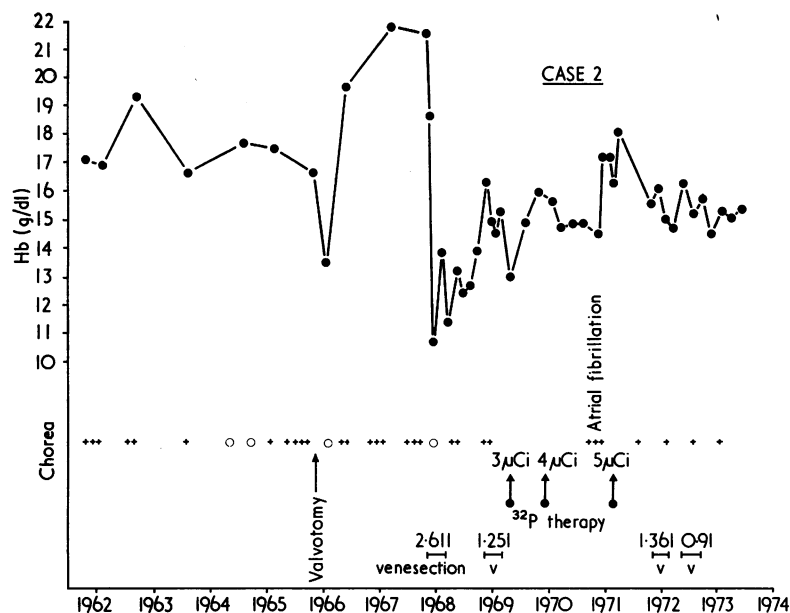


FIG. 3 Case 2. Chart showing relationship of chorea to severity of polycythaemia, as indicated by the haemoglobin level, and beneficial effects of blood loss at operation and of subsequent venesection and radiophosphorus therapy.

TABLE 2

CASE 2. REPRESENTATIVE HAEMATOLOGICAL VALUES 1962-73

| Date     | Hb (g/dl) | RBC ( $10^{12}/l$ ) | WBC ( $10^9/l$ )     | Platelets ( $10^9/l$ ) | PCV % |
|----------|-----------|---------------------|----------------------|------------------------|-------|
| 6. 4.62  | 17.1      |                     | 7.2                  |                        | 55    |
| 27. 3.63 | 19.3      | 6.16                | 11.5                 |                        | 55    |
| 15. 1.64 | 16.6      |                     | 10.4                 |                        |       |
| 6. 1.65  | 17.7      |                     | 8.6                  |                        |       |
| 28. 9.65 | 18.2      | 6.83                | 8.8                  | 469                    | 58    |
| 4.10.65  | 16.0      | 5.58                | 9.9                  | 250                    | 50    |
| 6. 6.66  | 16.7      |                     | 7.0                  |                        |       |
| 15. 6.66 |           |                     |                      |                        |       |
| 21. 3.67 | 21.8      | 7.79                | 8.0                  |                        | 63    |
| 2. 5.68  | 21.0      | 7.60                | 8.9                  | 363                    | 61    |
| 18. 5.68 |           |                     |                      |                        |       |
| 12. 6.68 | 10.7      | 3.90                | 5.2                  | 230                    | 34    |
| 22. 8.68 | 11.4      | 5.60                |                      |                        | 36    |
| 5.11.68  | 13.2      | 6.50                | 16.9                 |                        | 49    |
| 18. 7.69 | 14.6      | 7.30                | 8.3                  |                        | 46    |
| 3.10.69  |           |                     |                      |                        |       |
| 19.11.69 | 14.1      | 6.20                | 32 p 3.0 $\mu$ Ci IV | 6.0                    | 47    |
| 21. 1.70 | 14.9      | 6.10                | 6.5                  | 171                    | 48    |
| 9. 6.70  |           |                     |                      |                        |       |
| 6. 7.70  | 15.7      | 5.79                | 32 p 4.0 $\mu$ Ci IV | 5.7                    | 83    |
| 13. 1.71 | 14.9      | 5.08                | 5.9                  | 142                    | 49    |
| 16. 6.71 | 17.2      | 5.43                | 7.8                  | 138                    |       |
| 10. 8.71 |           |                     |                      |                        |       |
| 23. 8.71 | 16.3      | 5.19                | 32 p 5.0 $\mu$ Ci IV | 8.5                    | 48    |
| 14. 4.72 | 15.5      | 5.27                | 7.9                  |                        | 46    |
| 3.11.72  | 15.2      | 5.94                | 7.2                  | 140                    | 47    |
| 27. 4.73 | 14.5      | 5.93                | 8.7                  | 150                    | 45    |
| 26.10.73 | 15.1      | 5.86                | 8.8                  | 160                    | 46    |

a feeling of being 'muddled up' and of experiencing vividly events long past.

On examination he was a tall thin man with a lugubrious and unchanging expression. His speech was slurred. His cheeks, lips, and tongue were crimson, his fingers and toes brick red. He had signs of mitral stenosis with normal rhythm and was not in congestive failure. He was moderately dyspnoeic and disliked lying flat. Liver and spleen were not palpable. Despite the improvement recorded in his psychiatric notes, he showed typical chorea of face, tongue, and extremities and his gait was interrupted by bizarre movements. His limbs were hypotonic and knee jerks pendular. His IQ was 108 on the Wechsler scale with no evidence of dementia. A sharp wave focus was recorded from the left temporal region in the EEG, which was otherwise normal. The spinal fluid was normal and the Wassermann reaction negative in blood and fluid. Serum copper oxidase activity was normal. Cardioscopy and electrocardiography (ECG) (Dr A. J. Thomas) confirmed tight mitral stenosis and, after a short period of observation, valvotomy was advised but refused. His haemoglobin level was slightly elevated but the other blood elements were in the expected range (Table 2).

His subsequent progress is recorded graphically in Fig. 3 and essential haematological data in Table 2. Little change was observed over the next two years apart from slowly progressive dyspnoea but fixity of expression and bradykinesia without tremor or

rigidity were frequently mentioned. These signs were attributed to the trifluoperazine without which his chorea became troublesome. At a visit in January 1964 he complained of increasing shortness of breath and his spleen was palpable. Deterioration over the following year led to his readmission in the autumn of 1965 when the cause of his obvious polycythaemia was again questioned. Mild dementia was confirmed by psychometry but the severity of his hypoxia was still held responsible for his polycythaemia. Eventually he agreed to operation and valvotomy was performed on 15 June 1966. Remission of chorea was immediate but it relapsed later in the year. The effect on his cardiorespiratory function was less satisfactory and his shortness of breath was not relieved.

Polycythaemia rubra vera was not established until April 1968 when Professor Allan Jacobs demonstrated a red cell volume of 52 ml/kg (normal range 26–33 ml/kg) and a total blood volume of 91 ml/kg (normal range 60–80 ml/kg). Repeated venesection improved his chorea but sustained control of the polycythaemia proved difficult and radioactive phosphorus was given in October 1969, July 1970, and August 1971. With the improved blood picture, his chorea again subsided but never disappeared and mild relapse often signalled, or preceded, a significant rise in the haemoglobin level.

### 3. DISCUSSION

Chorea is a rare complication of polycythaemia. Since 1909 when Bardachzi and Umney published their reports within a few days of each other only 22 cases have appeared in journals circulating in Britain (Table 1). This contrasts with the frequency of strokes and other neurological disasters in the literature of polycythaemia. Several of the early accounts, beginning with Vaquez's classic case of vertigo (Vaquez, 1892), mentioned the nervous system (Cabot, 1899; Osler, 1903; Hutchison and Miller, 1906) and a neurological syndrome soon became commonplace in the natural history of the disorder (Jacobs, 1912; Lucas, 1912; Christian, 1917; Weber, 1921; Brockbank, 1929; Sloan, 1933; de Secondi, 1940). In recent years, the predominance of cerebral symptoms has emerged from many reviews and the neurological complications of polycythaemia, both central and peripheral, are now regarded as a major source of morbidity and mortality (Tinney *et al.*, 1943; Videbaek, 1950; Johnson and Chalgren, 1951; Lawrence *et al.*, 1953; Calabresi and Meyer, 1959; Croizat *et al.*,

1960; Silverstein *et al.*, 1962; Campbell *et al.*, 1970).

The chorea of polycythaemia is usually a lone disorder, although it may sometimes be associated with other cerebral and peripheral complications. It resembles hereditary, rheumatic, and senile chorea and, particularly in its orofacial-lingual emphasis, the tardive dyskinesia of prolonged phenothiazine treatment (Hunter *et al.*, 1964; Crane, 1968) and the chorea induced by the oestrogens of the contraceptive pill (Fernando, 1966; Lewis and Harrison, 1969) or by the dopamine of levodopa therapy (Cotzias, 1969; Godwin-Austen *et al.*, 1969; Yahr *et al.*, 1969). It should be distinguished from choreoathetosis due to infarction of basal nuclei and their associated pathways (Martin, 1957) and from the many types of metabolic disturbance including the acute lesions of hypoxia (Foley, 1954; Cree, 1969), hypernatraemia (Mann, 1969), and withdrawal of alcohol (Mullin *et al.*, 1970) and such chronic disorders as hepatolenticular degeneration (Wilson, 1912) and hepatic cirrhosis (Victor *et al.*, 1965). It is also distinct from the transient involuntary movements which may precede a cerebral haemorrhage (Cabot, 1899).

Crosetti (1929) mentioned polycythaemia in a case of Huntington's chorea and Doll and Rothschild (1922) described an extraordinary family afflicted with the two disorders. In none of the reported cases of polycythaemic chorea (Table 1) nor in the two cases described above was a family history of dementia or of chorea obtained.

The first of the two patients reported by Gautier-Smith and Pranker (1967) had had Sydenham's chorea at puberty and the young woman described by Naville and Brüttsch (1919) had had three attacks of chorea in the four years before the onset of catastrophic symptoms more certainly attributable to polycythaemia. Paralytic hemichorea followed by more generalized symptoms which persisted for six months was diagnosed in our second case 29 years before his presentation with polycythaemic chorea.

The occasional involvement of basal structures during the course of polycythaemia is indicated by the reports of tremor (Lucas, 1912; Dameshek and Henstell, 1940; Kramer, 1961), dystonia resembling Wilson's disease (Brockbank, 1929), narcolepsy with chills, tremors, and cataplexy (Lhermitte and Peyre, 1930), and essential

tremor with additional extrapyramidal signs (Liessens, 1951).

Epilepsy, another uncommon feature of our second case, has previously been reported by Naville and Brütsch (1919), Tinney *et al.* (1943), Alajouanine *et al.* (1952), and Forsberg (1962).

The extent of the pathological lesion underlying chorea is unknown (Yahr, 1972). Denny-Brown (1962) suggested that degeneration of basal ganglia was matched by a spectrum of clinical phenomena: as the disorder advanced the shifting postures of chorea and athetosis changed into the fixed attitudes of dystonic rigidity. As chorea is a symptom of early disease the visible changes might well be slight.

Three cases of polycythaemic chorea have been studied at necropsy (Schiff *et al.*, 1936; Kotner and Tritt, 1942; Bietti *et al.*, 1968). Congestion of cerebral and meningeal veins, multiple small thrombi, and scattered zones of perivenous demyelination were findings common to all three; in addition, subdural and putaminal haemorrhages were described in the Italian case (Bietti *et al.*, 1968). The basal ganglia shared in the generalized venous engorgement but local lesions were reported only by Schiff *et al.* (1936) who found intense demyelination of the anterior pallidum on both sides. The benign consequences of long-continued venous engorgement—at least in terms of light microscopy—were emphasized by Courville (1958). In the brain of a polycythaemic respiratory cripple, also an alcoholic, whose last months had been complicated by signs of dementia and Parkinsonism, he found an extraordinary degree of venous engorgement but a dearth of thrombi and more or less intact arteries and capillaries. Despite the presumed severity of carbon dioxide retention, the signs of tissue injury were slight and almost wholly attributable to agonal changes.

At the molecular level, information has come principally from cases of Huntington's chorea but also from chorea induced by phenothiazines, butyrophenones, levodopa, and oestrogens (Klawans *et al.*, 1970). The normal concentration of catecholamines in the striatum suggests that dopamine is more active than acetylcholine in the conditions which cause chorea and that this functional derangement is eventually accompanied by loss of type II Golgi cells, particularly in the caudate nuclei (Barbeau, 1973). The re-

lease which follows of the globus pallidus and substantia nigra from the inhibitory caudofugal fibres is the probable basis of chorea. As the neurotransmitter of these fibres is gamma-aminobutyric acid (GABA), support for this hypothesis has come from the studies of Perry *et al.* (1973) and of Bird *et al.* (1973) who found reduced levels of GABA and its biosynthetic enzyme glutamic-acid decarboxylase in the brains of patients dying of chorea. The latter authors (Bird *et al.*, 1973) also found reduced activity of choline-acetyltransferase, further evidence of depressed cholinergic transmission.

Although the fluctuations of polycythaemic chorea suggest a reversible biochemical lesion nothing is yet known of catecholamine and acetylcholine activity. Stagnation of the capillary and venous circulation is almost certainly the immediate precipitant of striatal dysfunction but the rarity of the syndrome suggests another and more subtle defect. Riddoch *et al.* (1971) in their discussion of oestrogen-induced chorea came to a similar conclusion. The slowed circulation of polycythaemia was attributed by Millikan *et al.* (1960) to increased viscosity of the blood with resultant rise in cerebrovascular resistance and fall in blood flow (Nelson and Fazekas, 1956). Abnormal stickiness of platelets (Shield and Pearn, 1969) adds to the stagnation. Multiple small thrombi form when the fragile platelets disintegrate *en masse* (Fiehrer, 1950) but they readily break up (Rosenthal, 1949) and allow the circulation to return promptly to the obstructed vessels; hence the lack of visible tissue injury (Courville, 1938).

#### 4. CONCLUSION

The importance of chorea as a warning sign of polycythaemia far outweighs its rarity as, in the majority of cases, diagnosis leads to effective therapy and to avoidance of a catastrophic illness (Table 1). In the child reported above (case 1), venesection was at first performed reluctantly as the polycythaemia was compensatory but the result fully justified the decision. The subsequent hemiplegia should not be regarded as a total failure of treatment: the early literature of polycythaemia vera abounds with examples of generalized thrombosis in untreated patients, such as the cases of Hutchison and Miller (1906),



Umney (1909) and Naville and Brütsch (1919). If this child's polycythaemia had been left uncorrected, the thrombosis might well have extended to other vessels.

The adult patient (case 2) is a lesson in the risks of delayed diagnosis. Had polycythaemia rubra vera been diagnosed in 1962 and treated appropriately, years of needless therapy with phenothiazines would have been avoided and valvotomy might have been postponed indefinitely. It is very probable that the drug which alone controlled his chorea, trifluoperazine, so damaged his striatal neurones that full remission of his chorea became impossible. In an environment of transmitter imbalance, perhaps aggravated by carbon dioxide retention, a dwindling population of dopaminergic receptor neurones, damaged first by adolescent chorea and secondly by chronic phenothiazine blockade, may have become supersensitive to dopamine, thus releasing lower centres from inhibitory control. His epilepsy may also indicate deficiency of gamma-aminobutyric acid. The persistence of his chorea despite a normal blood count and withdrawal of trifluoperazine suggests, like the slowly progressive dementia, Parkinsonian mask, and bradykinesia, that an initially reversible disorder has now passed beyond the point of recovery.

#### ADDENDUM

Aminoff *et al.* (1974) have recently reported an abnormal uptake of dopamine and of 5-hydroxytryptamine by the platelets of patients with Huntington's chorea. This suggests a mechanism in polycythaemia, whereby an excess of dopamine might be concentrated near receptors by increased numbers of normally loaded platelets circulating sluggishly through the basal ganglia. The chorea thus induced would be theoretically reversible by receptor blockade—for example, by phenothiazines—or by reducing platelet numbers by venesection. This mechanism would also account for the familial cases of polycythaemia with Huntington's chorea.

We are grateful to Dr L. G. Davies and to Dr A. J. Thomas for their cardiological advice in cases 1 and 2 and to Professor A. Jacobs for the haematological investigation of case 2.

#### REFERENCES

- Alajouanine, T., Boudin, G., André, R., and Goudal, H. (1952). Les manifestations nerveuses de la maladie de Vaquez. *Bulletins et Mémoires de la Société Médicale des Hôpitaux de Paris*, **68**, 538–549.
- Aminoff, M. J., Trenchard, A., Turner, P., Wood, W. G., and Hills, M. (1974). Plasma uptake of dopamine and 5-hydroxytryptamine and plasma-catecholamine levels in patients with Huntington's chorea. *Lancet*, **2**, 1115–1116.
- Ashenurst, E. M. (1972). Chorea complicating polycythemia rubra vera. *Canadian Medical Association Journal*, **107**, 434–437.
- Bakke, J. V., and Stavem, P. J. (1963). Chorea og polycythem. *Nordisk Medicin*, **69**, 200–202.
- Barbeau, A. (1973). Biochemistry of Huntington's chorea. In *Advances in Neurology*, vol. 1, pp. 473–516. Edited by A. Barbeau, T. N. Chase, and G. W. Paulson. Raven Press: New York.
- Bardachzi, F. (1909). Polyzythämie mit chorea. *Prager Medizinische Wochenschrift*, **34**, 253–255.
- Bietti, C., Pompili, A., and Sinibaldi, L. (1968). Coreoatetosi in malattia di Vaquez. (Contributo anatomoclinico). *Rivista di Neurologia*, **38**, 615–626.
- Bird, E. D., Mackay, A. V. P., Rayner, C. N., and Iversen, L. L. (1973). Reduced glutamic-acid-decarboxylase activity of post-mortem brain in Huntington's chorea. *Lancet*, **1**, 1090–1092.
- Bogolepov, N. K. (1962). (La chorée en association avec la gangrène des doigts de la main dans la polycythémie.) *Zhurnal Nevropatologii i Psikhiatrii Imeni S.S. Korsakova*, **62**, 45–50.
- Brockbank, T. W. (1929). Neurologic aspects of polycythemia vera. *American Journal of the Medical Sciences*, **178**, 209–215.
- Cabot, R. C. (1899). A case of chronic cyanosis without discernable cause, ending in cerebral hemorrhage. *Boston Medical and Surgical Journal*, **141**, 574–575.
- Calabresi, P., and Meyer, O. O. (1959). Polycythemia vera. I. Clinical and laboratory manifestations. *Annals of Internal Medicine*, **50**, 1182–1202.
- Campbell, A., Emery, E. W., Godlee, J. N., and Pranker, T. A. J. (1970). Diagnosis and treatment of primary polycythaemia. *Lancet*, **1**, 1074–1077.
- Christian, H. A. (1917). The nervous symptoms of polycythemia vera. *American Journal of the Medical Sciences*, **154**, 547–554.
- Cotzias, G. C. (1969). Metabolic modification of some neurologic disorders. *Journal of the American Medical Association*, **210**, 1255–1262.
- Courville, C. B. (1958). Changes in the vasculature of the encephalic gray matter in marked congestion (polycythemia vera). *Bulletin of the Los Angeles Neurological Society*, **23**, 134–141.
- Crane, G. E. (1968). Tardive dyskinesia in patients treated with major neuroleptics. A review of the literature. *American Journal of Psychiatry*, **124**, Suppl., 40–48.
- Cree, J. E. (1969). Transient choreo-athetosis following severe anoxia. *Proceedings of the Royal Society of Medicine*, **62**, 323–324.
- Croizat, P., Revol, L., and Viboud, G. P. (1960). La maladie de Vaquez (à propos de 62 observations). *Journal de Médecine de Lyon*, **41**, 1279–1345.
- Crosetti, L. (1929). Policitemia vera ed affezioni degenerativi del sistema nervoso. (Sull' importanza di fattori costituzionali nell'etiologia della sindrome di Vaquez). *Archiv per le Scienze Mediche*, **53**, 96–113.
- Dameshek, W., and Henstell, H. H. (1940). The diagnosis of polycythemia. *Annals of Internal Medicine*, **13**, 1360–1387.
- Denny-Brown, D. (1962). *The Basal Ganglia and their Relation*

- to Disorders of Movement. Oxford University Press: London.
- Doll, H., and Rothschild, K. (1922). Familiäres Auftreten von Polycythaemia rubra in Verbindung mit Chorea progressiva hereditaria Huntington. *Klinische Wochenschrift*, **1**, 2580.
- d'Eramo, N., and Levi, M. (1972). Neurological symptoms in polycythemia vera. In *Neurological Symptoms in Blood Diseases*, pp. 46–62. Harvey Miller and Medcalf: London.
- Fernando, S. J. M. (1966). An attack of chorea complicating oral contraceptive therapy. *Practitioner*, **197**, 210–211.
- Fiehrer, A. (1950). Sang incoagulable et maladie de Vaquez. *Sang: Biologie et Pathologie*, **21**, 655–658.
- Foley, J. (1954). Cortical blindness and spastic quadriplegia following apnoea in an asthmatic attack. *Proceedings of the Royal Society of Medicine*, **47**, 296–297.
- Forsberg, S. A. (1962). Polycythaemia vera and essential thrombocythaemia. Two variants of the myelo-proliferative syndrome. *Acta Medica Scandinavica*, **171**, 209–221.
- Friedemann, M., Mumenthaler, M., and Kummer, H. (1965). Chorea bei Polycythaemia vera. *Deutsche Zeitschrift für Nervenheilkunde*, **187**, 585–594.
- Gautier-Smith, P. C., and Pranker, T. A. J. (1967). Polycythaemia vera and chorea. *Acta Neurologica Scandinavica*, **43**, 357–364.
- Glass, J. L., and Wasserman, L. R. (1972). Primary polycythemia. In *Haematology*, pp. 527–544. Edited by W. J. Williams, E. Beutler, A. J. Ersler, and R. W. Rundles. McGraw-Hill: New York.
- Godwin-Austen, R. B., Tomlinson, E. B., Frears, C. C., and Kok, H. W. L. (1969). Effects of L-dopa in Parkinson's disease. *Lancet*, **2**, 165–168.
- Harvier, P., Laffitte, A., and Lavarenne, G. (1950). Maladie de Vaquez et chorée. *Paris Médical*, **139**, 277–282.
- Heathfield, K. W. G. (1968). Polycythaemia and chorea. *British Medical Journal*, **1**, 250.
- Hunter, R., Earl, C. J., and Janz, D. (1964). A syndrome of abnormal movements and dementia in leucotomized patients treated with phenothiazines. *Journal of Neurology, Neurosurgery and Psychiatry*, **27**, 219–223.
- Hutchison, R., and Miller, C. H. (1906). A case of splenomegalic polycythaemia, with report of post-mortem examination. *Lancet*, **1**, 744–746.
- Jacobs, C. (1912). Zwei weitere Beiträge zur primären Polyhämie und deren Genese. *Münchener Medizinische Wochenschrift*, **59**, 2384–2388.
- Johnson, D. R., and Chalgren, W. S. (1951). Polycythemia vera and the nervous system. *Neurology*, **1**, 53–67.
- Klawans, H., Jr, Ilahi, M. M., and Shenker, D. (1970). Theoretical implications of the use of L-dopa in parkinsonism. A review. *Acta Neurologica Scandinavica*, **46**, 409–441.
- Kotner, L. M., and Tritt, J. H. (1942). Chorea complicating polycythemia vera: report of a case. *Annals of Internal Medicine*, **17**, 544–548.
- Kramer, W. (1961). Neurologische stoornissen bij polycythemia vera. *Nederlandsch Tijdschrift voor Geneeskunde*, **105**, II, 1277–1281.
- Lawrence, J. H., Berlin, N. I., and Huff, R. L. (1953). The nature and treatment of polycythemia. Studies on 263 patients. *Medicine*, **32**, 323–388.
- Lewis, P. D., and Harrison, M. J. G. (1969). Involuntary movements in patients taking oral contraceptives. *British Medical Journal*, **4**, 404–405.
- Lhermitte, J., and Peyre, E. (1930). La narcolepsie-cataplexie, symptôme révélateur et unique de l'érythrémie occulte. Maladie de Vaquez. *Revue Neurologique*, **1**, 286–290.
- Liessens, P. (1951). Manifestations neurologiques au cours de la maladie de Vaquez. *Acta Neurologica et Psychiatrica Belgica*, **51**, 300–308.
- Lucas, W. S. (1912). Erythremia, or polycythemia with chronic cyanosis and splenomegaly. Report of two cases with a summary of 179 cases reported to date. *Archives of Internal Medicine*, **10**, 597–667.
- Mann, T. P. (1969). Transient choreo-athetosis following hypernatraemia. *Developmental Medicine and Child Neurology*, **11**, 637–640.
- Martin, J. P. (1957). Hemichorea (hemiballismus) without lesions in the corpus Luysii. *Brain*, **80**, 1–10.
- Millikan, C. H., Siekert, R. G., and Whisnant, J. P. (1960). Intermittent carotid and vertebro-basilar insufficiency associated with polycythemia. *Neurology*, **10**, 188–196.
- Mullin, P. J., Kershaw, P. W., and Bolt, J. M. W. (1970). Choreoathetotic movement disorder in alcoholism. *British Medical Journal*, **4**, 278–281.
- Naville, F., and Brüttsch, P. (1919). Les complications cérébrales et médullaires de la maladie de Vaquez (érythrémie). Note sur l'importance de l'hématologie en neurologie. *Schweizer Archiv für Neurologie und Psychiatrie*, **4**, 88–103.
- Nehllil, J., Thurel, R., Loutre, J. C., and Renouardière, R. (1969). Syndrome choréique et polyglobulie. *Revue Neurologique*, **121**, 182–183.
- Nelson, D., and Fazekas, J. F. (1956). Cerebral blood flow in polycythemia vera. *Archives of Internal Medicine*, **98**, 328–331.
- Osler, W. (1903). Chronic cyanosis, with polycythaemia and enlarged spleen: a new clinical entity. *American Journal of the Medical Sciences*, **126**, 187–201.
- Paliard, F., Croizat, P., and Schott, B. (1958). Choréo-athétose récidivante révélatrice de Maladie de Vaquez. *Lyon Médical*, **200**, 353–362.
- Perry, T. L., Hansen, S., and Kloster, M. (1973). Huntington's chorea. Deficiency of  $\gamma$ -aminobutyric acid in brain. *New England Journal of Medicine*, **288**, 337–342.
- Polani, P. E., and MacKeith, R. (1954). The sequelae of anoxia. A brief report of two cases recorded cinematographically. *Guy's Hospital Reports*, **103**, 54–58.
- Pollock, L. J. (1922). A case of chorea and erythremia. *Journal of the American Medical Association*, **78**, 724–726.
- Reinhard, E. H., Moore, C. V., Bierbaum, O. S., and Moore, S. (1946). Radioactive phosphorus as a therapeutic agent. A review of the literature and analysis of the results of treatment of 155 patients with various blood dyscrasias, lymphomas, and other malignant neoplastic diseases. *Journal of Laboratory and Clinical Medicine*, **31**, 107–218.
- Riddoch, D., Jefferson, M., and Bickerstaff, E. R. (1971). Chorea and the oral contraceptives. *British Medical Journal*, **4**, 217–218.
- Rosenthal, R. L. (1949). Blood coagulation in leucemia and polycythemia; value of the heparin clotting time and clot retraction rate. *Journal of Laboratory and Clinical Medicine*, **34**, 1321–1335.
- Sangster, J. F. (1970). Polycythaemia vera and chorea. *Australasian Annals of Medicine*, **19**, 354–357.
- Schiff, P., and Simon, R. (1933). Erythémie avec accès de cataplexie, de chorée et de confusion mentale. *Annales Médico-psychologiques*, Pt. 1, **91**, 616–619.
- Schiff, P., Trelles, J. O., and Ajuriaguerra, J. (1936). Sur un syndrome particulier d'origine pallidale. Erythémie avec chorée. *Encéphale*, **31**, 153–173.
- Secondi, R. de (1940). Sopra un caso di policitemia con gravi complicazioni cerebrali. *Riforma Medica*, **56**, 441–447.
- Shield, L. K., and Pearn, J. H. (1969). Platelet adhesiveness in polycythaemia rubra vera. *Medical Journal of Australia*, **56**, 711–715.
- Silverstein, A., Gilbert, H., and Wasserman, L. R. (1962). Neurologic complications of polycythemia. *Annals of Internal Medicine*, **57**, 909–916.
- Sloan, L. H. (1933). Polycythemia rubra vera. Neurologic

- complications; report of four cases. *Archives of Neurology and Psychiatry*, **30**, 154–165.
- Tinney, W. S., Hall, B. E., and Giffin, H. Z. (1942). Central nervous system manifestations of polycythemia vera. *Proceedings of the Staff Meetings of the Mayo Clinic*, **18**, 300–303.
- Trotsenburg, L. van, and Koster, M. (1954). Chorea caused by polycythaemia vera and treated with radioactive phosphorus. *Folia Psychiatrica, Neurologica et Neurochirurgica Neerlandica*, **57**, 429–434.
- Umney, W. F. (1909). Notes on a fatal case of splenomegalic polycythaemia (erythraemia). *Lancet*, **1**, 1243–1245.
- Vaquez, M. H. (1892). Sur une forme spéciale de cyanose s'accompagnant d'hyperglobulie excessive et persistante. *Comptes Rendus des Séances de la Société de Biologie, et de ses Filiales*, **4**, 384–388.
- Victor, M., Adams, R. D., and Cole, M. (1965). The acquired (non-Wilsonian) type of chronic hepatocerebral degeneration. *Medicine*, **44**, 345–396.
- Videbaek, A. (1950). Polycythaemia vera; course and prognosis. *Ugeskrift for Læger*, **112**, 795–799.
- Weber, F. P. (1921). *Polycythaemia, Erythrocytosis and Erythraemia (Vaquez-Osler Disease)*. Lewis: London.
- Wilson, S. A. K. (1912). Progressive lenticular degeneration: a familial nervous disease associated with cirrhosis of the liver. *Brain*, **34**, 295–509.
- Wintrobe, M. M. (1967). Polycythemia. In *Clinical Hematology*, pp. 855–885, 6th edn. Lea and Febiger: Philadelphia.
- Yahr, M. D. (1972). Involuntary movements. In *Scientific Foundations of Neurology*, pp. 83–88. Edited by M. Critchley, J. L. O'Leary, and B. Jennett. Heinemann: London.
- Yahr, M. D., Duvoisin, R. C., Schear, M. J., Barrett, R. E. and Hoehn, M. M. (1969). Treatment of parkinsonism with levodopa. *Archives of Neurology*, **21**, 343–354.