

Left Atrial Free-Floating Ball Thrombus With Recent Cardioembolic Stroke

A 67-year-old man was admitted to a local hospital complaining of hemiparesis. Because of coexisting arrhythmia, he was examined by echocardiography and found to have an oval free-floating thrombus in the left atrium concomitant with mitral and aortic stenosis. He was transferred to our hospital for emergency surgery. He underwent an operation on the ninth day from the onset of neurological dysfunction, when a $2.5 \times 2.5 \times 3.0$ cm ball thrombus was removed, and the diseased mitral and aortic valves were replaced. His postoperative course was uneventful, with no neurological sequelae. Though left atrial ball thrombus is rarely found in patients with mitral valve disease, when it is found, then immediate surgical intervention is recommended to avoid sudden death. However, there is a high risk that any cerebral lesion may worsen due to systemic heparinization. Therefore, the optimal time of surgery in a patient with a recent neurological deficit is controversial. (JJTCVS 2002; 50: 34–36)

Key words: left atrial ball thrombus, mitral stenosis, cardiopulmonary bypass, cardioembolic stroke

Nanritsu Matsuyama, MD, Toshihiro Kodama, MD, Naoki Wada, MD, Shigeto Hasegawa, MD,*
Kunio Asada, MD,* and Shinjiro Sasaki, MD.*

In mitral valve disease, mural thrombus in the left atrium is common, especially on the atrial appendage in patients with atrial fibrillation, but free-floating thrombus in the left atrium is a rare clinical problem associated with sudden death.^{1–3} Once the diagnosis of a free-floating ball thrombus is made, prompt surgical removal is mandatory. However, in surgery there is a risk that any recent neurological injury could be extended or exacerbated due to systemic anticoagulation and cardiopulmonary bypass.⁴ In this paper, we present a patient who successfully underwent cardiac surgery on the ninth day from the onset of cerebral infarction.

Case

A 67-year-old man was admitted for speech distur-

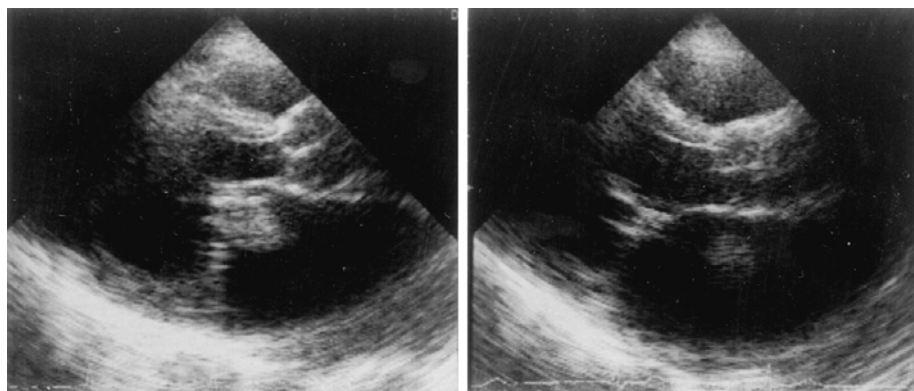
bance and right hemiparesis on the fourth day from the onset. He had a vague history of valvular heart disease without medication. On admission, his blood pressure was 150/82 mmHg with an irregular pulse at a rate of 50 beats per min. There were no abnormal physical findings, including jugular venous distention, hepatojugular reflux, bilateral r les, or pretibial edema. On auscultation, an accentuated first heart sound, a grade 3/6 diastolic rumbling murmur and an opening snap sound were heard at the cardiac apex. In addition, a grade 3/6 to and fro murmur was heard in the third left intercostal space. Hematological and biochemical examinations revealed no abnormalities. An electrocardiogram showed atrial fibrillation and left ventricular hypertrophy by voltage criteria. The cardiothoracic ratio was 0.77 with an enlarged left atrium on the chest radiograph. Two-dimensional echocardiography revealed an abnormal, solid, and mobile echogenic mass measuring 3.0 cm in greatest diameter in the dilated left atrium. This mass moved erratically through the cavity, careening against opposing walls or the mitral valve and then floating off on another trajectory. There was periodic diastolic impaction of the mass against the mitral valve orifice, with abrupt rebound back into the left atrial cavity towards the pulmonary vein orifices with each onset

From the Department of Thoracic Surgery, Hirakata City Hospital, and the *Department of Thoracic and Cardiovascular Surgery, Osaka Medical College, Osaka, Japan.

Received for publication February 1, 2001.

Accepted for publication August 9, 2001.

Address for reprints Nanritsu Matsuyama, MD, Department of Thoracic Surgery, Hirakata City Hospital, 2–14–1 Kinya-Motomachi, Hirakata City, Osaka 573–1013, Japan.



A | B

Fig. 1. A parasternal long axis recording showed a free-floating ball thrombus in the left atrium. A (left): The thrombus is within the mitral orifice during diastole and appears to occlude the valve. B (right): Also recorded during systole, the thrombus is in the superior portion of the atrium.

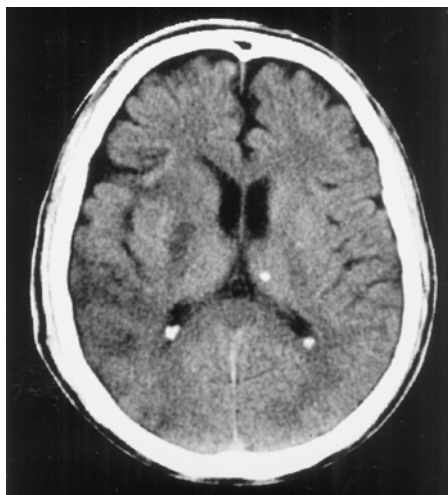

Fig. 2. A computed tomography scan of the brain showed left cerebral infarction.

of ventricular systole. An echocardiogram showed the mass completely occluded the mitral valve orifice (Fig. 1A), and another showed it was located in the middle of the cavity (Fig. 1B). The mitral valve was grossly thickened and stenotic with an estimated valve area of 0.7 cm². The left ventricular dimensions were normal. Doppler echocardiography revealed grade III aortic regurgitation. A preoperative computed tomographic (CT) scan of the brain showed left cerebral infarction (Fig. 2). Based on these findings, a diagnosis of rheumatic combined aortic and mitral valve disease with a free-floating ball thrombus in the left atrium was made and removal of the thrombus with double valve replacement was scheduled. To minimize the risk that cardiopulmonary bypass and hep-

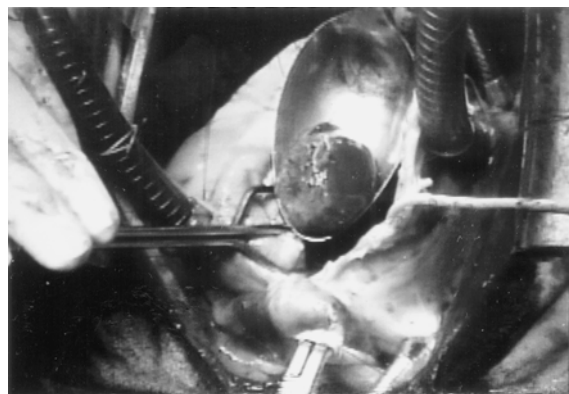


Fig. 3. A 2.5 × 2.5 × 3.0 cm free-floating ball thrombus weighing 10 g was removed.

arinization might exacerbate the cerebral infarction, we awaited recovery from neurological dysfunction and confirmed that no sign of bleeding appeared on a CT scan of the brain. We did not use any anticoagulant before surgery.

The operation was performed on the ninth day after the onset of the neurological symptom. Under a median sternotomy and a standard cardiopulmonary bypass with cold blood cardioplegia, the left atrium was opened. This revealed a round unattached thrombus measuring 2.5 × 2.5 × 3.0 cm in size weighing 10 g, together with a mural thrombus. The ball thrombus, almost spherical, had a smooth external surface (Fig 3), and on sectioning, consisted entirely of old laminar thrombotic material. The mitral valve was both stenotic and incompetent, and showed “fish-mouth” deformity produced by fusion of commissures and fibrous thickening of the valve leaflets. The aortic and

mitral valves were replaced with an Edwards-Tekna prosthesis (size 23A) and an Edwards-Tekna prosthesis (size 27M) respectively. Simultaneously, the left atrial appendage was closed by occluding its orifice from the inside of the left atrium with a purse-string suture to prevent blood stasis and subsequent thromboembolism. Histological examination showed red thrombus consisting of a meshwork of fibrin strands in which numerous red cells were contained. Pacemaker implantation (VVIR type) was performed for bradycardia with atrial fibrillation on the twenty-eighth postoperative day. His postoperative course was thereafter uneventful.

Discussion

The formation of a free-floating ball thrombus within the left atrium is a rare clinical entity.^{1,2} It usually occurs in an enlarged left atrium associated with a diseased mitral valve. Clinically, a free-floating ball thrombus can produce symptoms of heart failure, embolize peripherally or cause sudden death.³ Once the diagnosis of a free-floating ball thrombus is established, an emergency surgery is essential to prevent catastrophic complications.³ In this case, there was the risk that the recent cerebral lesion may be exacerbated by early surgical intervention. Generally, neurologists do not recommend early anticoagulant therapy after cardioembolic stroke. They observe the patient's condition at least one month and begin to give anticoagulants. Zisbrod et al.⁴ reported fifteen cases with recent cardioembolic stroke undergoing corrective cardiac surgery. The mean time of surgery after the onset of neurological event was 12.7 ± 7.9 (2–28) days. One patient died at 7 days after surgery from sepsis and multiple system organ failure, six patients had improvement in their neurological symptoms, and eight patients had complete neurological recovery postoperatively. Cerebral Embolism Study⁵ described nine patients with cardioembolic stroke who

experienced clinical deterioration associated with computed tomography-documented hemorrhagic transformation. They concluded that secondary hemorrhage in patients with cardioembolic stroke was not entirely predictable. The optimal time of surgery in patients with existing neurological dysfunction or previous recent stroke has not yet been adequately discussed.⁶ In our patient, a delayed brain CT on the seventh day from the onset showed no hemorrhagic transformation. We are not sure yet the optimal time of surgery in patients with recent cardioembolic stroke and a free-floating ball thrombus. It is clear that there is always the risk of "hole-in-one" sudden death and hemorrhagic transformation preoperatively, and neurological deterioration postoperatively.

REFERENCES

1. Wrisley D, Giambartolomei A, Lee I, Brownlee W. Left atrial thrombus: review of clinical and echocardiographic manifestations with suggestions for management. *Am Heart J* 1991; 121: 1784–90.
2. Chow WH, Chow LTC, Ng W. Free-floating but immobile ball thrombus in left atrium: diagnosis aided by transoesophageal echocardiography. *Intern J Cardiol* 1993; 39: 213–5.
3. Lie JT, Entman ML. "Hole-in-one" sudden death: mitral stenosis and left atrial ball thrombus. *Am Heart J* 1976; 91: 798–804.
4. Zisbrod Z, Rose DM, Jacobowitz IJ, Kramer M, Acinapura AJ, Cunningham JN. Results of open heart surgery in patients with recent cardiogenic embolic stroke and central nervous system dysfunction. *Circulation* 1987; 76 (Suppl V): V-109–2.
5. Ando M, Kawazoe K, Ego Y, Kosakai Y, Ohara K, Kito Y, et al. Successful re-aortic valve replacement of a patient with prosthetic valve endocarditis immediately after the episode of cerebral embolization (Eng abstr). *J Jpn Assn Thorac Surg* 1984; 32: 1406–11.
6. Cerebral Embolism Study Group. Cardioembolic stroke, early anticoagulation, and brain hemorrhage. *Arch Intern Med* 1987; 147: 636–40.