

Cerebral Germinoma with Hemiatrophy of the Brain: Report of Three Cases

C. H. Kim¹, S. H. Paek¹, I. A. Park², J. G. Chi², and D. G. Kim¹

¹Department of Neurosurgery, Seoul National University College of Medicine, Clinical Research Institute, Seoul National University Hospital, Seoul, Korea

²Department of Pathology, Seoul National University College of Medicine, Clinical Research Institute, Seoul National University Hospital, Seoul, Korea

Summary

Background. The authors report three cases of cerebral germinoma that occurred in young adults with unusual presentation.

Method. All three patients presented with hemiparesis and were treated at Seoul National University. A histological diagnosis of germinoma was made by a stereotactic biopsy in all three cases.

Findings. Magnetic resonance (MR) images showed that their tumors were located in the internal capsule and thalamus, and were associated with ipsilateral cerebral hemisphere and brain stem atrophy. The hemiparesis slowly progressed and this was accompanied by a haemorrhagic cyst in each patient.

Interpretation. Clinical diagnosis was not easy because of the unusual clinical presentations and atypical MR imaging findings. It is suggested that cerebral germinoma should be included in the differential diagnosis of a haemorrhagic mass which is associated with cerebral atrophy in the thalamus, basal ganglia, or internal capsule, especially in adolescents or young adults.

Keywords: Germinoma; brain; atrophy; haemorrhage; Wallerian degeneration.

Introduction

The incidence of intracranial germ cell tumour is approximately 2% in primary intracranial neoplasms in patients who are younger than 20-years, however it is as high as 6.5% in Japan [2]. Germ cell neoplasms usually develop along the intracranial midline structures and a germinoma is the most common intracranial germ cell tumour.

Neuroradiologically, most lesions are well circumscribed and show a homogeneous contrast enhancement [1, 3]. Serologically, no specific tumor marker is elevated in a pure germinoma [2]. The diagnosis is usually not difficult to make and the mainstay of management is a combination of chemotherapy and radiotherapy [2].

An intracranial germinoma sometimes arises from

the cerebral parenchyma outside the suprasellar or pineal area and especially occurs adjacent to the basal ganglia, thalamus, or internal capsule. This accounts for 10% of intracranial germinomas [1, 13]. The clinical manifestations and neuro-imaging are unusual and the diagnosis is usually not easy.

Haemorrhages and cerebral hemiatrophy are reported in ectopic cerebral germinomas, and, the etiology is presently not clearly documented [3]. Three cases of ectopic germinoma are reported and suggestions as to the mechanisms lead to the unusual clinical and radiological presentations which are discussed.

Cases

Case 1

This 17-year-old boy was admitted to our hospital for the evaluation of a right spastic hemiparesis. Two years before his admission, a limping gait began after he had a falling accident. The weakness and clumsiness in the right leg slowly progressed and the upper extremity also became involved soon after. There were no accompanying sensory changes. A brain magnetic resonance (MR) image, obtained one year after the beginning of the symptoms, showed a small haemorrhagic lesion in the genu and posterior limb of the left internal capsule without contrast enhancement. The cerebral and brainstem hemiatrophy in the left side were not significant (Fig. 1). Cerebral angiography was done, but, there were no abnormalities noted. Further diagnostic procedures or management were not performed and the symptoms persisted. Follow-up MR images at 10-, 13-, and 20-months later demonstrated that the lesion that was thought to be a haemorrhagic cyst which had progressively enlarged and a solid portion that showed a contrast enhancement started to be seen (Fig. 2). Stereotactic biopsy was recommended, but, the parents very much hesitant. The hemiparesis progressed and the patient was admitted to our department to undergo the biopsy procedure 7-months later. On admission, a right spastic hemiparesis was noted. (Grade III–IV). The beta-human chorionic gonadotrophin was slightly elevated (8 ng/ml: normal range 0–3 ng/ml) but other tumour makers

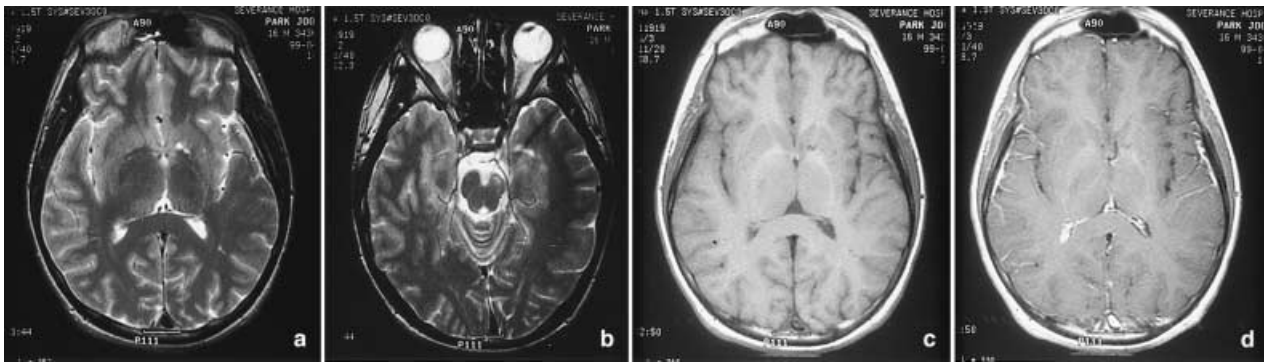


Fig. 1. A T2-weighted axial magnetic resonance (*MR*) image showing small high signal intensity lesions in the genu and posterior limb of left internal capsule (a). Atrophy with high signal intensity, suggesting Wallerian degeneration, is shown in the left crus of midbrain (b). T1-weighted axial MR images demonstrate small low signal intensity lesions in the same area (c) and there is no contrast enhancement in the gadolinium enhanced T1-weighted axial image (d)

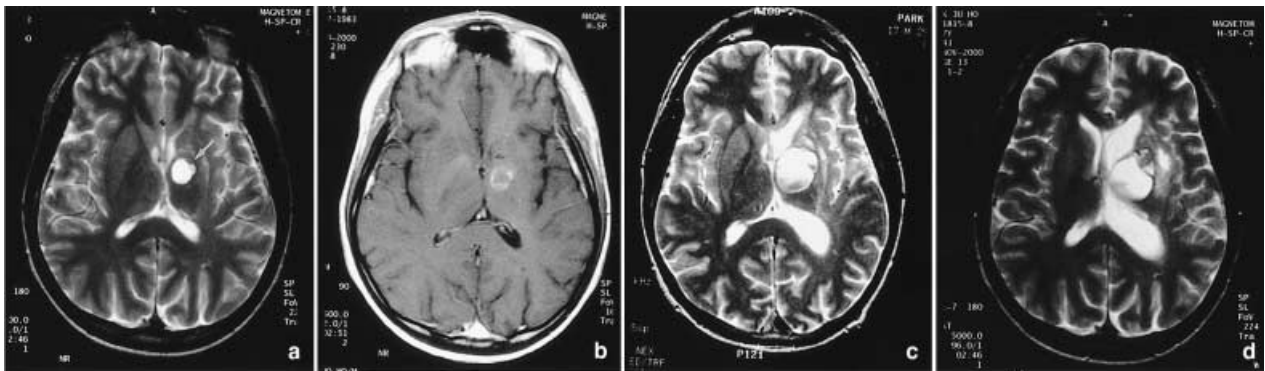


Fig. 2. The lesion shown in Fig. 1 has grown and a small solid part (white arrow) starts to be seen in the anterior lateral part of the lesion in the T2-weighted axial magnetic resonance (*MR*) image obtained 10 months after the first MR image. The left lateral ventricle is larger than the right one, which suggests ipsilateral brain atrophy (a). A gadolinium enhanced T1-weighted axial image shows rim enhancement (b). T2-weighted axial images obtained 13 months (c) and 20 months (d) after first brain MR image show the further growth of both the cystic and solid portions of the lesion and the aggravation of ipsilateral cerebral atrophy including ventricular enlargement

were within the normal range. A stereotactic biopsy of the solid portion was performed. The content of the cyst was dark brown in color, which suggested that this was an old haemorrhage. The histological diagnosis was germinoma. A whole spine MR image was obtained and this confirmed that there was no cerebrospinal seeding. Chemotherapy with bleomycin, etoposide, and cisplatin and radiation therapy (5220 cGy) were carried out, but the neurological status did not improve.

Case 2

A 17-year-old boy was admitted with a one-year history of right hemiparesis. The right hemiparesis developed insidiously and slowly progressed. Neurological examination on admission revealed a hemiparesis (Grade IV) and hemihypesthesia on the right side. The deep tendon reflexes on the right side were increased. Brain MR imaging showed a focal enhancing lesion in the posterior limb of the internal capsule that was associated with a cyst and a perilesional high signal lesion in the T2-weighted images. A lateral ventricular enlargement and brain stem atrophy accompanied these on the same side (Fig. 3). Cerebrospinal fluid examination and serological studies for tumour makers were normal. A Stereotactic biopsy was performed and a

histological diagnosis of germinoma was made. There was no evidence of seeding on spinal MR imaging and radiotherapy followed using a dose of 5040 cGy. Subsequent MR imaging showed a focal cerebromalacia around the left basal ganglia, but there was no residual enhancing lesion. The hemiparesis improved slightly.

Case 3

This 30-year-old man was admitted for the evaluation of a left hemiparesis and hemihypesthesia. Headaches and a visual field defect developed insidiously about 1.5 years prior to admission and these were followed by a left hemiparesis and hemihypesthesia. Polydipsia and polyuria were present during this year, however, no diagnostic procedures were performed. On neurological examination, a left hemiparesis (Grade IV), and hemihypesthesia (60~70% than right) were noted. The visual acuity was 20/40 on the right and 20/100 on the left and a visual field examination showed a left homonymous hemianopia. The urinary specific gravity was 1.005 and the urine-output was about 4.5 L per day. On a MR image, multiple high signal cystic lesions in T2-weighted images were observed in the right thalamus, hypothalamus, cerebral peduncle, pons, and medulla (Fig. 4). Tumour markers in the cerebrospinal fluid and serum were within

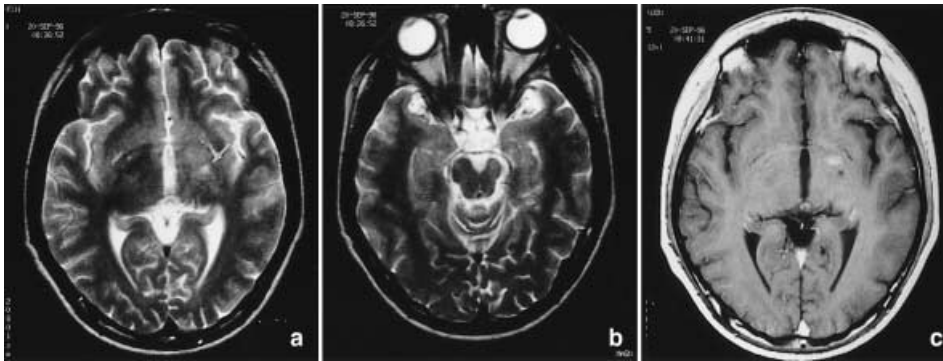


Fig. 3. A T2-weighted axial magnetic resonance (*MR*) image showing a small cystic lesion in the left basal ganglia (white arrow). A peri-lesional high signal intensity area extend to the surrounding basal ganglia and posterior limb of internal capsule. An ipsilateral lateral ventricular enlargement and atrophy of the brain are seen (a). Atrophy of the ipsilateral crus of the midbrain is also shown to have a high signal lesion which is thought to be due to Wallerian degeneration on a T2-weighted axial image (b). A T1-weighted axial image demonstrates a focal enhancing lesion in basal ganglia and the posterior limb of internal capsule (c)

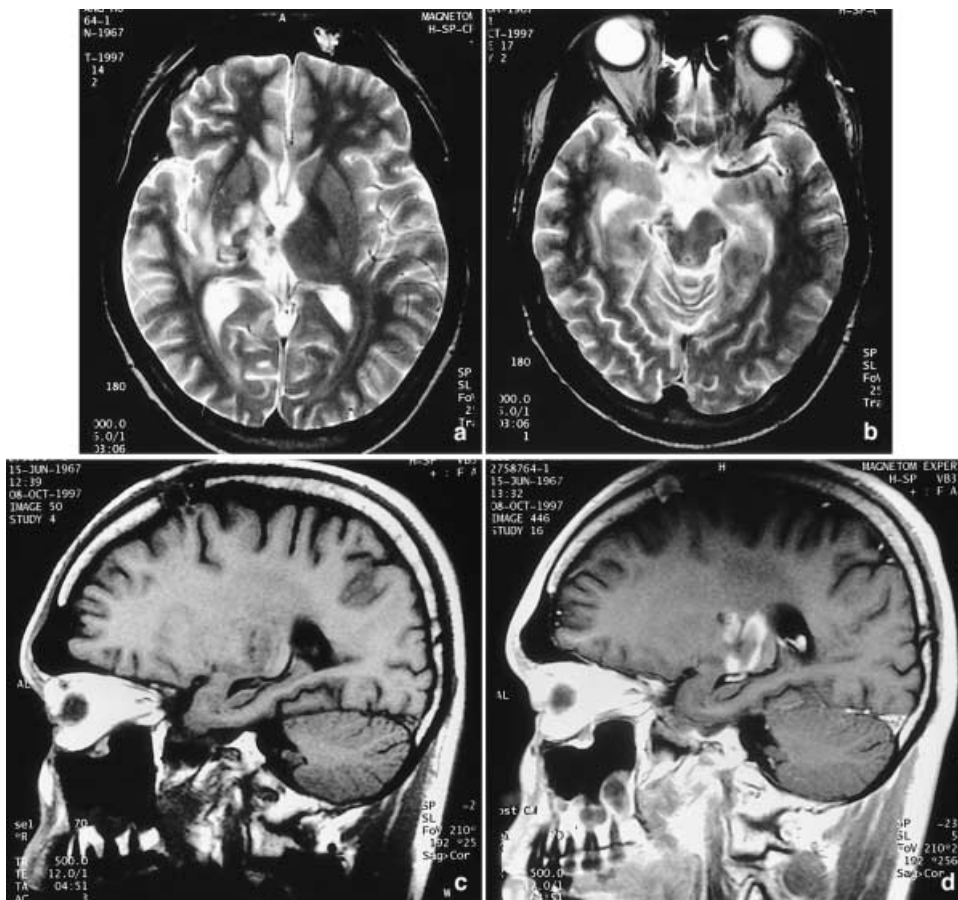


Fig. 4. A T2-weighted axial magnetic resonance (*MR*) image shows a mixed high and low signal intensity lesion that is located in the right thalamus and basal ganglia which extended to the ipsilateral posterior limb of the internal capsule and was associated with ipsilateral ventricular enlargement. This lesion suggests a haemorrhage (a). A high signal intensity lesion with atrophy, suggesting Wallerian degeneration, is also shown in the right crus of midbrain (b). T1-weighted sagittal MR images reveal a low signal intensity lesion (c) that shows a thick peripheral rim enhancement in a gadolinium enhanced T1-weighted image (d)

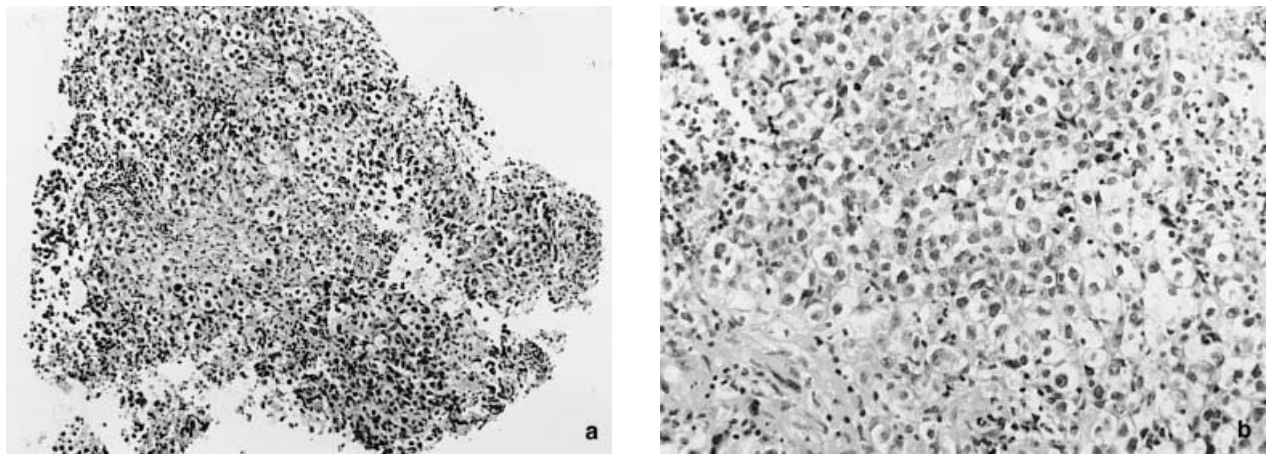


Fig. 5. (a) Histopathology showing proliferation of tumour cells that are divided into poorly demarcated lobules by scant fibrous stroma, and infiltration by mature lymphocytes. (H&E, $\times 100$) (b): High-power view of the tumor showing a sheet-like proliferation of round-to-polyhedral cells having a distinct cell membrane, a clear cytoplasm, and a large, central nucleus with a prominent nucleolus. (H&E, $\times 200$)

their normal ranges. A stereotactic biopsy for the thalamic lesion was performed and a histological diagnosis of germinoma with granuloma formation was made (Fig. 5). Conventional fractionated radiotherapy with a dose amount of 5400 cGy was given, but, the neurological status remained stationary.

Discussion

Literature Review

Intracranial germinomas are thought to arise from the midline stream of totipotential cells of the rostral neural tube [3]. This tumour represents 0.5~2.1% of all intracranial tumours and has a peak incidence in the latter half of the second decade of life [7]. Most intracranial germinomas occur in the midline areas such as the pineal or suprasellar regions and have characteristic clinical and radiological features. Typical symptoms and signs for germinoma are diabetes insipidus, visual field deficits, hypopituitarism, Parinaud's syndrome, and/or symptoms of increased intracranial pressure due to hydrocephalus [2]. Magnetic resonance (MR) imaging results are well documented for suprasellar or pineal germinomas. On both T1- and T2-weighted images, the signal intensity is almost the same as that of the adjacent brain, and on contrast enhancement images, the lesion usually shows an intense, homogeneous contrast enhancement [3].

Atypical cases which have unusual locations have also been reported [1–10], and these ectopic germinomas make up 10% of intracranial germinomas [1, 13]. Early diagnosis is difficult because of the non-specific

symptoms and signs and the unusual neuroradiological findings. Common sites for ectopic germinomas are the thalamus and basal ganglia [6]. Third ventricular development may cause migration of ectopic germ cells from the midline and this could explain the occurrence in the off-midline structures [3–5]. The MR finding is usually subtle in the early stage of the disease but the ectopic germinoma proves to be a heterogeneous solid lesion that is mixed with a cystic component which is caused by a haemorrhage followed by disease progression [1, 3]. Ipsilateral cerebral atrophy including brain stem accompanies about 20% of intracranial ectopic germinoma [3]. Symptoms and signs are non-specific, but, hemiparesis is a common symptom and mental deterioration, ocular motor palsy, involuntary movement, seizures, and diabetes insipidus have also been observed in ectopic germinomas [4]. Haemorrhage also occurs in 50% of patients [3] and Kim *et al.* [3] offered a presumptive cause of the haemorrhage as follows; An Ectopic germinoma grows rapidly compared with a suprasellar or pineal germinoma and this rapid tumour growth causes a haemorrhage by means of secondary degeneration of the tumour cells [3]. In Case 1, the disease began with a small haemorrhage and the solid mass was seen in the late stage. Initial MR images showed only a subtle cystic lesion in the left internal capsule and the sign for which was a slowly progressing right hemiparesis. The cyst which was caused by a haemorrhage that showed gradual enlargement as the disease progressed and this lesion was found to extend to the thalamus on following images, causing the haemorrhagic cyst to become promi-

ment. Therefore the hypothesis proposed by Kim *et al.* can not explain the status in Case 1. The authors think that the germinoma originally has a tendency to bleed even if it is small in size and this makes it possible for the germinoma to present a pure haemorrhagic cyst in the early stage as was demonstrated in our patients.

The prognosis is favorable for the mass itself, but, the associated neurological deficits such as weakness or sensory change usually persist because of the hemiatrophy of the brain [1, 5, 11, 12]. An early diagnosis and prompt treatment before the full-blown neurological deficits emerge are mandatory.

Cerebral Hemiatrophy

A progressive hemiparesis is the common presenting sign in ectopic intracranial germinomas as in our patients and an ipsilateral brain atrophy as seen by neuro-imaging is the usual associated finding [4, 6–8]. Several hypotheses have been proposed to explain the ipsilateral brain atrophy and motor/sensory signs in cases of a mass lesion around the basal ganglia or thalamus; however, the cause of these remains obscure [1, 6]. Kwak *et al.* [6] proposed that there was an involvement of thalamic ganglionic cells, the infiltration of afferent and efferent nerve fibers from the thalamus and a subsequent anterograde and retrograde Wallerian degeneration to be the main causes [5]. Such findings are not restricted to ectopic germinoma and other neoplasms which have a low degree of malignancy that is accompanied by slow growth in same location also show brain atrophy [3, 6]. However, malignant tumours in the thalamus or the basal ganglia usually present with the symptoms and signs of increased intracranial pressure and focal neurological deficits [6, 8, 9]. The theory appears to explain the findings that occur with ectopic germinoma, but, it cannot explain the reason why brain atrophy does not develop in every benign thalamic mass. Moreover this hypothesis does not adequately account for the motor signs in the early stages.

A second hypothesis is that the infiltration of tumour cells into the internal capsule is the main cause of the brain atrophy [1]. This hypothesis is supported by the observations that tumours restricted to the thalamus or basal ganglia do not show brain atrophy but this atrophy is very pronounced in cases of internal capsule invasion [1]. In two of our three patients, the masses involved both the thalamus and internal capsule from the beginning, and led to the presenting signs

of hemiparesis and hemihypesthesia. However, the chief complaint was hemiparesis in our remaining one case (Case 1) and the mass was restricted only to the internal capsule as shown by the initial MR images. There were no sensory symptoms. This case (Case 1) is strongly indicative of the second hypothesis and it is suggested that the involvement of the internal capsule might be the main cause of the hemiparesis and Wallerian degeneration which is seen in ectopic germinomas.

Conclusion

Germinomas can occur in the area of the basal ganglia and/or internal capsule and are associated with cerebral hemiatrophy including the brain stem. Symptoms and signs are weakness and sensory changes with a slow progression. Consequently the diagnosis might be delayed because of such unusual clinical and radiological presentations.

Cerebral germinomas might be included in the differential diagnosis of intracranial masses around the thalamus or internal capsule, which have a haemorrhagic cyst and cerebral hemiatrophy, especially if it occurs in adolescents or young adults.

Acknowledgments

This work was supported in part by a grant from Seoul National University Hospital.

References

1. Higano S, Takahashi S, Ishii K, Matsumoto K, Ikeda H, Sakamoto K (1994) Germinoma originating in the basal ganglia and thalamus: MR and CT evaluation. *AJNR* 15: 1435–1441
2. Youmans JR, Becker DP, Dunsker SB, Friedman WA, Hoffman HJ, Smith RR, Wilson CB (1996) *Neurol Surg* 4: 2715–2745
3. Kim DI, Yoon PH, Ryu YH, Jeon P, Hwang GJ (1998) MRI of germinomas arising from the basal ganglia and thalamus. *Neuroradiology* 40: 507–511
4. Kobayashi T, Kageyama N, Kida Y, Yoshida J, Shibuya N, Okamura K (1981) Unilateral germinomas involving the basal ganglia and thalamus. *J Neurosurg* 55: 55–62
5. Komatsu Y, Narushima K, Kobayashi E, Ebihara R, Enomoto T, Nose T, Maki Y (1989) CT and MR of germinoma in the basal ganglia. [Suppl] *AJNR* S9–11
6. Kwak R, Saso SI, Suzuki J (1978) Ipsilateral cerebral atrophy with thalamic tumor of childhood. Case report. *J Neurosurg* 48: 443–449
7. Liu E, Robertson RL, du Plessis A, Pomeroy SL (1999) Basal ganglia germinoma with progressive cerebral hemiatrophy. *Pediatr Neurol* 20: 312–314
8. Maehara T, Machida T, Tsuchiya K, Iio M (1983) Brain tumors with ipsilateral cerebral hemiatrophy. *AJNR* 4: 478–480
9. Mutoh K, Okuno T, Ito M, Fujii T, Mikawa H, Moritake M,

- Yamashita J, Ishikawa M, Kikuchi H (1988) Ipsilateral atrophy in children with hemispheric cerebral tumors: CT findings. *J Comput Assist Tomogr* 12: 740–743
10. Nagata K, Nikaido Y, Yuasa T, Fujimoto K, Kim YJ, Inoue M (1998) Germinoma causing wallerian degeneration. Case report and review of the literature. *J Neurosurg* 88: 126–128
 11. Sawamura Y, Ikeda J, Shirato H, Tada M, Abe H (1998) Germ cell tumours of the central nervous system treatment consideration based on 111 cases and their long-term clinical outcomes. *Eur J Cancer* 34: 104–110
 12. Shirato H, Nishio M, Sawamura Y, Myohjin M, Kitahara T, Nishioka T, Mizutani Y, Abe H, Miyasaka K (1997) Analysis of long-term treatment of intracranial germinoma. *Int J Radiat Oncol Biol Phys* 37: 511–515
 13. Tamaki N, Lin T, Shirataki K, Hosoda K, Kurata H, Matsu-moto S, Ito H (1990) Germ cell tumors of the thalamus and the basal ganglia. *Childs Nerv Syst* 6: 3–7

Comments

Three cases of young adults with germinoma unilaterally involving internal capsule and thalamus are reported. Ipsilateral atrophy of brain stem and cerebral hemisphere were associated with the tumor (MRI); in one patient an additional small hemorrhagic lesion in the internal capsule was found. All cases presented with hemiparesis. The histological diagnosis was made on a tumoral specimen obtained by stereotactic biopsy. Radio- and chemotherapy were given in all cases, with satisfactory results in one.

The literature on this uncommon presentation of cerebral germ cell tumors, as well as on the origin of the hemiparesis, is discussed. The tumoral (and hemorrhagic in one case) involvement of the internal capsule and the subsequent Wallerian degeneration are regarded as the most likely causes of the ipsilateral brain atrophy and, obviously, of the hemiparesis.

The cases are described in detail in the text and by the MRI pictures. Similar cases were previously reported and no original data or comments can be found in the present paper. However, the rare occurrence of cases like these might justify the publication.

J. F. Rossi

This is a well-written, straightforward and interesting short paper. The authors coherently present three new cases of cerebral ectopic germinomas arising in the area of the basal ganglia and internal capsule associated with ipsilateral brain atrophy and cystic haemorrhage. They point out the difficulties of establishing a diagnosis and advise to include such a diagnostic suspicion when the above is present in young adults with a clinical history of progressive hemiparesis and the corresponding neuro-imaging. The already proposed hypotheses for explaining the high incidence of accompanying haemorrhage and of cerebral hemi-atrophy are well discussed and criticized.

F. Isamat

Correspondence: Dong Gyu Kim, M.D., Department of Neurosurgery, Seoul National University College of Medicine, 28 Yongon-dong, Chongno-gu, Seoul 110-744, Korea.