

## Encephalitis related to primary varicella-zoster virus infection in immunocompetent children

M. Häusler<sup>a,\*</sup>, L. Schaade<sup>b,1</sup>, S. Kemény<sup>c</sup>, K. Schweizer<sup>d</sup>,  
C. Schoenmackers<sup>a</sup>, V.Th. Ramaekers<sup>a</sup>

<sup>a</sup>Department of Pediatrics, Pediatric Neurology Division, University Hospital, RWTH Aachen, Pauwelsstr. 30, D-52074 Aachen, Germany

<sup>b</sup>Department of Microbiology, Virology Division, University Hospital, RWTH Aachen, Aachen, Germany

<sup>c</sup>Department of Neuroradiology, University Hospital, RWTH Aachen, Aachen, Germany

<sup>d</sup>Department of Microbiology, Immunology Division, University Hospital, RWTH Aachen, Aachen, Germany

Received 30 August 2001; received in revised form 6 December 2001; accepted 6 December 2001

### Abstract

**Introduction:** Encephalitis is a rare complication of primary varicella-zoster virus (VZV) infection in immunocompetent children. **Methods:** The clinical and laboratory findings of two girls with VZV-related encephalitis are reported. **Results:** Both children presented with focal epileptic seizures, corresponding to cortical/subcortical as well as white matter lesions. The first showed a typical vesicular skin rash. She was easily diagnosed and made a rapid recovery during acyclovir and steroid treatment. In the second girl, a preceding measles–mumps–rubella virus vaccination and the absence of skin vesicles were misleading with respect to the diagnosis, which was finally proven by IgG seroconversion and intrathecal synthesis of IgG antibodies to VZV. She developed left parieto-occipital tissue necrosis and recovered only transiently during initial acyclovir/steroid treatment. Eight weeks after onset, progressive white matter demyelination and the occurrence of erythema nodosum in the lower limbs necessitated a second 4-month course of oral steroids. The VZV PCR from cerebrospinal fluid was negative in both children. **Conclusions:** Primary VZV infection may cause severe encephalitis that may occur without skin vesicles and lead to a chronic course with systemic vasculitis. The coincidence of vaccination and neurologic diseases offers no proof per se of a causal relationship. © 2002 Elsevier Science B.V. All rights reserved.

**Keywords:** Varicella-zoster virus; Encephalitis, viral; Vaccination, adverse effects; White matter disease; Acyclovir, therapeutic use

### 1. Introduction

Primary varicella-zoster virus (VZV) infection may cause various neurologic complications. In immunocompetent children, its frequency is considered to be below 1%, with postinfectious ataxia, a usually benign disease, being the most frequent manifestation [1–3]. Myelitis, encephalitis or stroke, in contrast, are considered rare events. During recent years, however, increasing data suggest an underestimated impact of VZV on pediatric neurologic disease. Recently, Askalan et al. [4] showed a close epidemiologic link between recent VZV infection and childhood stroke, and according to our own experience, patients with VZV-related cerebral vasculitis may present even up to 4 years after the

primary infection [5]. Therefore, at our hospital, all patients with acute, otherwise unexplained neurologic symptoms, are routinely investigated for acute primary VZV infection and intrathecal synthesis of anti-VZV antibodies. Between January 2000 and March 2001, two children presented with severe VZV-related encephalitis, a disorder that has hitherto been reported in 15 cases only [3,6–19]. The clinical data of these two children, the diagnostic approach and the treatment response are summarized below.

### 2. Methods

Specific antiviral antibody titers were measured using Enzygnost enzyme immune assays and the BEP III instrument (Dade Behring, Marburg, Germany). Peripheral blood lymphocyte subsets were analyzed by means of two-color flow cytometry (FACScan™) according to standard protocols (Becton Dickinson Immunocytometry Systems). The

\* Corresponding author. Tel.: +49-241-8088-773; fax: +49-241-8082-484.

E-mail address: Haeusler@RWTH-Aachen.de (M. Häusler).

<sup>1</sup> These authors have contributed equally.

Table 1  
Virological findings in both children with VZV encephalitis

	Serum		CSF				
	VZV IgG (mU/ml)	VZV IgM (OD)	VZV AI	CSF VZV PCR	HSV AI	Blood–brain barrier	Intrathecal IgG-synthesis (%)
Patient 1	960	0.718	1.57	negative	<1.5	disrupted	29
Patient 2	seroconversion	<0.1	initially negative, later 4.2	negative	initially negative, later 4.1	disrupted	30
Normal/negative	<50	<0.1	<1.5	negative	<1.5	intact	absent

AI: IgG antibody index; VZV: varicella-zoster virus; HSV: herpes simplex virus; OD: optical density.

following subsets were investigated: B cells (CD19)-, helper T cells (CD3CD4)-, NK cells (CD16CD56)-, cytotoxic/suppressor T cells (CD3CD8), HLA-DR antigen and interleukin-2 receptor expression on T cells. Control values were available from another study, approved by the Ethics Committee of the University. Autochthonous intrathecal synthesis of total IgG, IgA or IgM antibodies and of specific antiviral IgG antibodies was calculated as described elsewhere [20] using Dade Behring Enzygnost enzyme immune assays and a nephelometer for measurement of total antibody concentrations in sera and cerebrospinal fluid (CSF). A specific antibody index (AI) greater than 1.5 was regarded as proof of intrathecal synthesis of specific anti-

bodies. HSV PCR and VZV PCR in CSF were performed with the LightCycler instrument (Roche, Mannheim, Germany), with two hybridization probes being applied for amplicon detection (sensitivity: 1000 genome equivalents/ml).

### 3. Results

Basic clinical and serologic data are described in the patient reports. Table 1 summarizes the virologic data. Table 2 shows detailed laboratory data referring to the prolonged course of Patient 2.

Table 2  
Laboratory and clinical data of Patient 2

	Weeks after admission	0	4	6	8	12	16	20	23	26	29	38	Normal
CSF	Intrathecal IgG synthesis <sup>a</sup>	30%		58%		40%							Negative
	Intrathecal IgM synthesis <sup>a</sup>	n.d.		0%		Negative							Negative
	Intrathecal IgA synthesis <sup>a</sup>	n.d.		20%		Negative							Negative
	Blood–brain barrier	Disrupted		Normal		Normal							Normal
	CSF protein (g/l)	1.24		0.23		0.13							<0.4
	CSF cells/ $\mu$ l	32		6		1							<5/ $\mu$ l
	Intrathecal IgG anti-VZV synthesis (AI) <sup>b</sup>	0.7				4.1							AI $\leq$ 1.5
	Intrathecal IgG anti-HSV synthesis (AI) <sup>b</sup>												AI $\leq$ 1.5
Serum	IgG anti-VZV	<50		160		120	120	110		95		63	<50 mU/ml
	IgM anti-VZV	<0.1		<0.1		<0.1	<0.1	<0.1		<0.1		<0.1	<0.1 OD
	IgG anti-HSV	1:10,000		1:22,000		1:16,000		1:24,000					<1:320
	Anti-Purkinje-cell autoantibodies	<10	12		<10	<10	22	25		15		<10	<10 U
	C1q immune complexes			Negative		68	40	60		Negative			<34 kU/l
	C3d immune complexes			Negative		35	24	38		Negative			<8 kU/l
Clinical data	Erythema nodosum	–	–	–	+++	+++	+++	+++	++	++	+	–	
	Steroid-dose (mg/kg/day)	2	0	0	0	2	1	1	0.75	0.25	0.25	0	

AI: antibody index; VZV: varicella-zoster virus; HSV: herpes simplex virus; n.d.: not done; OD: optical density.

<sup>a</sup> Percentage of intrathecally synthesized immunoglobulin among total intrathecal immunoglobulin (IgG, IgM or IgA).

<sup>b</sup> Presence of intrathecally synthesized specific antiviral IgG.

### 3.1. Patient 1

One week after a typical vesicular skin eruption, this previously healthy 4-year-old girl suffered a right-sided focal seizure. On admission to hospital, she was drowsy and febrile. Magnetic resonance imaging (MRI) showed a subcortical inflammation within the left parietal lobe as well as within the right operculum, corresponding to left parieto-occipital baseline slowing on electroencephalography (EEG). CSF analysis revealed a slightly increased protein concentration (0.41 g/l; normal <0.4 g/l), pleocytosis (135 cells/ $\mu$ l) and intrathecal IgG (29%), IgA (48%) and IgM (73%) synthesis. Serologic studies confirmed the primary VZV infection (IgM and IgG anti-VZV positive). The VZV AI was slightly positive (1.57; normal <1.5). VZV PCR from CSF and AI to further neurotropic viruses were negative. Despite immediate intravenous acyclovir administration (30 mg/kg/day), somnolence and repeated epileptic seizures, unresponsive to clonazepam, persisted. Three days after admission, the MRI showed new lesions affecting the right lentiform nucleus, both caudate nuclei and the right parietal gyri (Fig. 1). Now, oral steroid treatment (2 mg/kg/

day) was started, resulting in clinical recovery and cessation of fits within 2 days. Because of persistent baseline slowing on EEG, however, phenytoin treatment was initiated. The steroids were slowly phased out over 6 weeks. Oral acyclovir therapy was continued throughout the oral steroid treatment phase. Control MRI scans, performed 11 days after the beginning and after the end of steroid therapy, were normal, as was repeated duplex sonography of intracranial arteries. At 2 months of follow-up, the child showed full recovery. There were no more seizures and the EEG findings were normal. Immunophenotyping of peripheral lymphocytes performed on admission and during follow-up, serum concentrations for circulating immune complexes, immunoglobulins, anti-Purkinje cell and antinuclear autoantibodies proved normal.

### 3.2. Patient 2

Six weeks after her first measles, mumps and rubella virus triple vaccination (Priorix<sup>®</sup>, MMR), the previously healthy 16-month-old girl suffered a right-sided epileptic seizure. Upon admission, she was febrile, irritable and drowsy. Meningism was absent, neurologic investigation was normal, an upper airway infection was noted, and liver enzymes were slightly elevated. At that time, resulting from the recent vaccination, the IgG anti-mumps, -rubella and -measles titers were positive, as were IgM anti-mumps titers. IgM anti-measles and -rubella titers, in contrast, were negative, as were IgM anti-VZV, -cytomegalovirus, -herpes simplex (HSV) and -Epstein–Barr virus titers.

Three days after admission, a second seizure occurred. Although the results of contrast-enhanced cranial computed tomography were normal, the MRI scan revealed a left-sided thalamic and parieto-occipital cortical/subcortical lesion. MRI angiography and duplex sonography revealed no intracranial large vessel stenoses. EEG showed left-sided sharp wave discharges. The CSF protein concentration (1.24 g/l) and leukocyte counts (32/ $\mu$ l, 22% lymphocytes, 78% neutrophils) were elevated, and the blood–brain barrier was severely disrupted. Microbiologic investigations proved normal. Since herpetic encephalitis was suspected despite the negative initial CSF PCR findings, acyclovir (30 mg/kg/day) treatment was started, combined with primidone and dexamethasone (1 mg/kg/day). Within 2 days of treatment, vigilance and body temperature normalized. After 8 more days, a control MRI scan showed slight progression of the cortical and white matter lesions. Because of the excellent clinical recovery, however, acyclovir and steroids were phased out and therapy was finished after 14 days in total. On the 19th day after admission, the child was discharged from the hospital.

Two days after discharge, however, she developed subfebrile temperatures, and 3 weeks later, erythema nodosum at the lower limbs. Simultaneously, autoantibody titers to Purkinje cells and circulating immune complex concentrations increased (Table 2). At that time, IgG anti-VZV titers showed

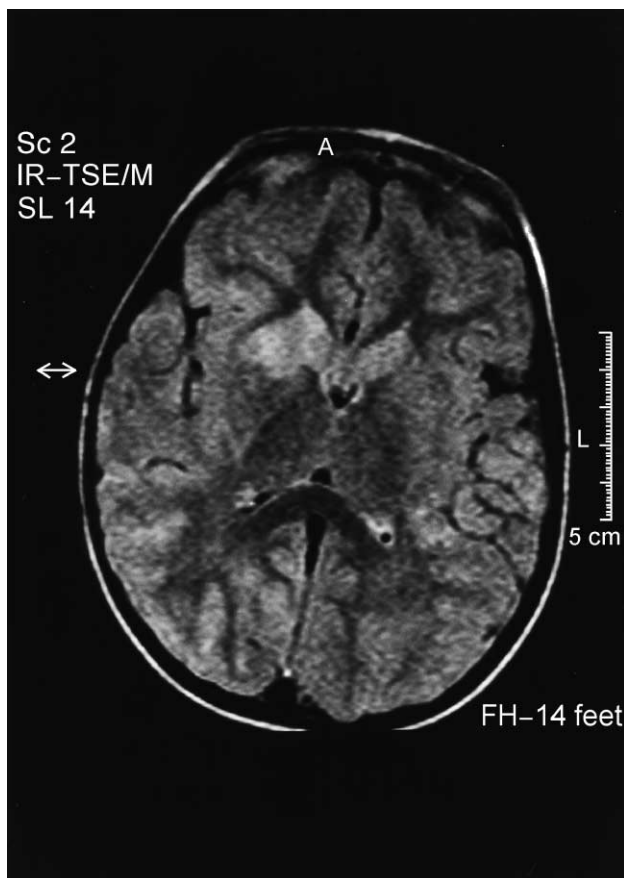


Fig. 1. MRI image of Patient 1 (T2-weighted FLAIR) showing high signal intense lesions within the right nucleus lentiformis, both caudate nuclei and the right parietal gyri 3 days after admission. Native and contrast-enhanced T1-weighted images were normal.

a seroconversion, whereas antibody titers to adeno-, influenza A and B, parainfluenza 1–3, human herpes virus type 6, Coxsackie and ECHO viruses showed no significant changes. IgG antibody titers to borrelia, to polyoma-, FSME-, lymphochoriomeningitis-, cytomegalo- and Epstein–Barr viruses remained negative. Simultaneously with the IgG anti-VZV seroconversion, the VZV and HSV AI became positive (Table 2), whereas no intrathecal synthesis of antibodies to the vaccination viruses was present. Again, CSF PCR investigations were negative for VZV and HSV DNA.

When a control MRI performed 11 weeks after onset of illness showed extensive left parieto-occipital necrosis and marked bilateral white matter lesions (Fig. 2), steroid therapy (prednisolone, 2 mg/kg/day maximum) was started again. Within 4 weeks, the white matter lesions regressed significantly. After 2 more months, the erythema nodosum disappeared, autoantibody titers and circulating immune complex concentrations became negative, and corticosteroid therapy could be withdrawn. Ten months after onset of the disease, permanent right-sided hemianopsia was found as the single deficit on follow-up neurological examination. The follow-up MRI scans showed a residual parieto-occipital tissue defect but gradual near complete resolution of

the white matter and thalamic lesions. Repeated immunophenotyping of peripheral blood lymphocytes proved normal, as did serum immunoglobulin concentrations as well as in vitro lymphocyte proliferation and immunoglobulin synthesis to mitogens ( $^3\text{H}$ -thymidine incorporation).

#### 4. Discussion

This report describes two children with encephalitis related to primary VZV infection. In the first, a typical skin rash rapidly established the diagnosis, whereas in the second, the preceding vaccination might have suggested post-vaccination acute demyelinating encephalomyelitis (ADEM) [21,22]. ADEM, however, was unlikely as it commonly occurs within 4 weeks of the vaccination, rapidly responds to steroids, rarely causes cortical/subcortical lesions and usually shows a monophasic course. Vaccination itself rarely causes ADEM, and 45% of patients with severe post-vaccination neurologic complications show additional triggers, including infections in 33% of cases [22–24]. In our patient, further infections were ruled out, no intrathecal synthesis of antibodies to the vaccination viruses was found, and the IgG anti-VZV seroconversion and intrathecal IgG anti-VZV antibody synthesis finally established the diagnosis [25]. Neither the absence of IgM anti-VZV antibodies, nor the negative VZV PCR or the positive HSV AI question this diagnosis. Similar data are described in the literature [1,26–29]. The simultaneous increase of the HSV AI, for instance, is explained by cross-reactivity between anti-VZV and anti-HSV antibodies or simultaneous proliferation of HSV-specific B-cell clones.

Subcortical/cortical white matter and basal ganglia lesions have also been found in patients with other herpes virus infections, such as Epstein–Barr-, cytomegalo- or herpes simplex virus [30,31], but may nevertheless be highly suggestive of VZV-related neurologic disease, being present on T2-weighted MRI images of three of the six previously reported surviving patients with severe VZV-related encephalitis and in the histopathology of the nine patients who died [3,6–19]. As also known from further VZV-related neurologic complications, the most prominent pathologic changes did affect the vascular system, showing small vessels with perivascular mononuclear inflammation and demyelination. In contrast to the VZV-related small vessel vasculopathy of immunodeficient patients, however, perivascular necrosis or viral inclusions were not reported [32–34]. The bilateral involvement observed in both present and all but one of the previously published patients furthermore contrasts the large vessel angiitis of post-varicella stroke which is unilateral in the majority of cases [4,5].

Two major pathomechanisms can be discussed to contribute to VZV-encephalitis, i.e. direct viral invasion and an autoimmune process. The autoimmune hypothesis can be suggested from the following findings: In both children, the CSF VZV PCR was negative. In Patient 1, the clinical

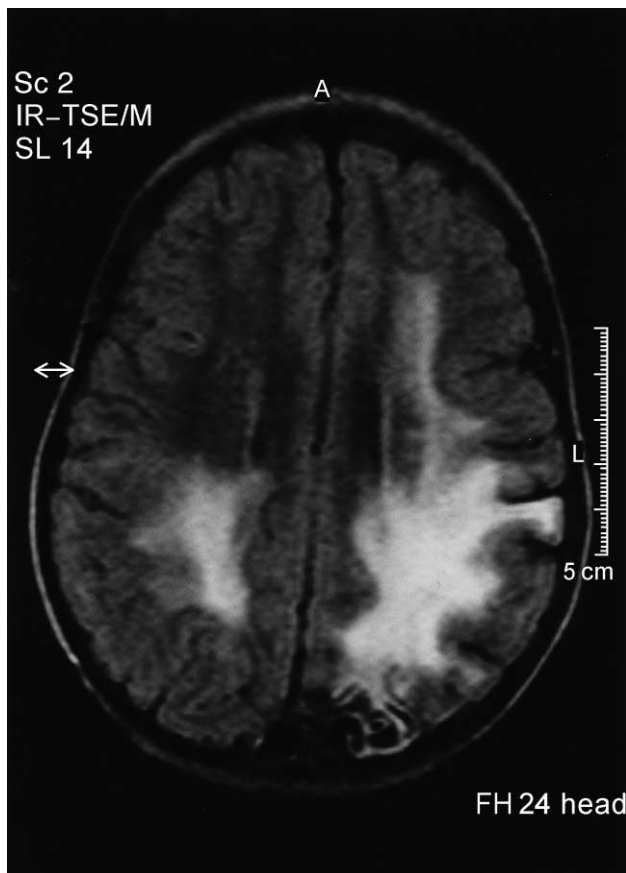


Fig. 2. MRI of Patient 2 (T2-weighted FLAIR) showing left-sided parieto-occipital necrosis with marked bilateral white matter lesions 11 weeks after admission before the second course of steroid treatment.

symptoms worsened during acyclovir monotherapy but rapidly responded to steroids, as did the prolonged white matter lesions and the systemic vasculitis of Patient 2. Moreover, during her chronic course Patient 2 showed an increase of serum anti-Purkinje cell autoantibody titers which have been suggested to mirror VZV-triggered anti-neuronal autoimmunity, and erythema nodosum is a small vessel vasculopathy that rarely complicates chickenpox disease and shares histopathologic characteristics with the above mentioned small vessel angiitis [33,35]. Finally, one previously published patient also developed a chronic course with recurrent white matter demyelination that necessitated steroid treatment [16]. Nevertheless, these data do not prove an autoimmune pathogenesis. The presence of a positive VZV AI indicates a specific antibody response against intrathecal viral particles which should have been present at least transiently in the central nervous compartment, and the negative CSF PCR does not prove the absence of viral particles from the CNS either. On the one hand, the intrathecal VZV quantity may have been below the detection threshold. On the other hand, as VZV encephalitis seems to be of a mainly vascular nature, VZV may be present within vessels without becoming detectable in the CSF. Furthermore, anti-Purkinje cell autoantibodies might not be the cause of but a reaction to tissue destruction, and the response to steroids might also be based on the suppression of a destructive bystander effect resulting from the antiviral inflammatory response.

Considering these possible pathomechanisms, we would recommend combining steroid with acyclovir therapy in comparable cases, although it is pointed out that early acyclovir treatment may have suppressed the skin vesicles in Patient 2 and delayed the diagnosis. This can be hypothesized from immunodeficient patients with VZV reactivation where acyclovir can prevent the skin rash but not the neurologic complications [36].

One further question is why the children suffered these severe complications. In neither of them did we find laboratory changes indicative of a severe congenital immunodeficiency disorder, nor did we see a lowering of helper T-cell counts or of the CD4/CD8 ratio, comparable to our previously published patients with post-varicella stroke [5]. However, in the course of a primary VZV infection there should be an increase of CD8(+) or of HLA-DR antigen positive T cells, indicating antiviral immune defense [26]. This marker of T-cell cytotoxicity was not observed in the present cases. In Patient 2, this may have been due to the preceding measles vaccination which can suppress delayed hypersensitivity reactions and the memory T-cell response [37]. The coincidental VZV infection and MMR vaccination may also have contributed to the prolonged peripheral and central nervous disease of Patient 2. Preceding viral infections can enhance antibody formation to the MMR vaccine viruses, and immune stimulation by different agents such as antigen and adjuvant has also been hypothesized in patients who developed white matter demyelination after vaccination

and who were simultaneously suffering from latent infections [38,39].

We suggest that VZV-related encephalitis may be more frequent than commonly assumed. The diagnosis should be suspected in the presence of cortical/subcortical lesions, even in the absence of typical skin lesions or in the presence of alternative triggering factors. Vaccines should not readily be made responsible for diseases observed in close temporal relationship unless clear-cut proof has been established. VZV vaccination, in turn, might have prevented our patients' severe neurologic complications.

## References

- [1] Kleinschmidt-DeMasters BK, Gilden DH. Varicella-zoster virus infections of the nervous system. *Arch Pathol Lab Med* 2001;125:770–80.
- [2] Gilden DH, Kleinschmidt-DeMasters BK, LaGuardia JJ, Mahalingam R, Cohrs RJ. Neurologic complications of the reactivation of varicella-zoster virus. *N Engl J Med* 2000;342:635–45.
- [3] Bauman ML, Bergman I. Postvaricella encephalitis. *Arch Neurol* 1984;41:556–8.
- [4] Askalan R, Laughlin S, Mayank S, Chan A, MacGregor D, Andrew M, et al. Chickenpox and stroke in childhood. A study of frequency and causation. *Stroke* 2001;32:1257–62.
- [5] Häusler MG, Ramaekers VT, Reul J, Meilicke R, Heimann G. Early and late onset manifestations of cerebral vasculitis related to varicella zoster. *Neuropediatrics* 1998;29:169–224.
- [6] Zimmerman HM, Yannet H. Nonsuppurative encephalomyelitis accompanying chickenpox. *Arch Neurol Psychiatry* 1931;26:322–32.
- [7] van Bogaert L. Contribution clinique et anatomique à l'étude des manifestations neurologiques et psychiatriques de l'infection varicelleuse. *J Neurol Psychiatry* 1930;30:623–41.
- [8] Dagnelie J, Dubois R. Documents personnels inédits des rapporteurs: complications neurologiques des exanthèmes. *J Neurol Psychiatry* 1932;32:630–44.
- [9] Bergman R, Magnusson JH. Studie über Enzephalitis bei Varizellen mit besonderer Berücksichtigung der Spätprognose. *Acta Paediatr* 1939;26:31–61.
- [10] Swan C. A case of post-varicella encephalitis showing bilateral softening of the neostriatum and terminal "tetanoid chorea". *Med J Aust* 1946;26:697–702.
- [11] Heppleston JD, Pearce KM, Yates PO. Varicella encephalitis. *Arch Dis Child* 1959;34:318–21.
- [12] Geibel H, Kramer B, Naji AF. Encephalitis complicating chickenpox. *Am J Dis Child* 1960;99:669–79.
- [13] Abbruzzi WA. Varicella encephalitis. *NY State J Med* 1961;61:3912–5.
- [14] Jenkins RB. Severe chickenpox encephalopathy. *Am J Dis Child* 1965;110:137–9.
- [15] Hurst DL, Mehta S. Acute cerebellar swelling in varicella encephalitis. *Pediatr Neurol* 1988;4:122–3.
- [16] Tenorio G, Whitaker JN. Steroid-dependent postvaricella encephalomyelitis. *J Child Neurol* 1991;6:45–8.
- [17] Sebag O, Mas JC, Bebin B, Ferracci JP, Sebag F. Leucoencéphalite avec hémiparésie au cours d'une varicelle. *Arch Pédiatr* 1997;4:1100–2.
- [18] Wagner HJ, Seidel A, Grande-Nagel I, Kruse K, Spemer J. Pre-eruptive varicella encephalitis: case report and review of the literature. *Eur J Pediatr* 1998;157:814–5.
- [19] Caruso JM, Tung GA, Brown WD. Central nervous system and renal vasculitis associated with primary varicella infection in a child. *Pediatrics* 2001;107:e9.
- [20] Reiber H, Felgenhauer K. Protein transfer at the blood CSF barrier and

- the quantitation of the humoral immune response within the central nervous system. *Clin Chim Acta* 1987;163:319–28.
- [21] Sriram S, Steinman L. Postinfectious and postvaccinial encephalomyelitis. *Neurol Clin* 1984;2:341–53.
- [22] Dale RC, de Sousa C, Chong WK, Cox TCS, Harding B, Neville BGR. Acute disseminated encephalomyelitis, multiphasic disseminated encephalomyelitis and multiple sclerosis in children. *Brain* 2000;123:2407–22.
- [23] Weibel RE, Caserta V, Benor DE, Evans G. Acute encephalopathy followed by permanent brain injury or death associated with further attenuated measles vaccines: a review of claims submitted to the national vaccine injury compensation program. *Pediatrics* 1998;101: 383–7.
- [24] Patja A, Davidkin I, Kurki T, Kallio MJT, Valle M, Peltola H. Serious adverse events after measles–mumps–rubella vaccination during a fourteen-year prospective follow-up. *Pediatr Infect Dis J* 2000;19: 1127–34.
- [25] Moriuchi H, Rodriguez W. Role of varicella-zoster virus in stroke syndromes. *Pediatr Infect Dis J*. 2000;19:648–53.
- [26] Arvin AM, Koropchak CM, Williams BRG, Grumet FC, Fong SKH. Early immune response in healthy and immunocompromised subjects with primary varicella-zoster virus infection. *J Infect Dis* 1986;154: 422–9.
- [27] Echevarria JM, Casas I, Tenorio A, deOry F, Martinez-Martin P. Detection of varicella-zoster virus-specific DNA sequences in cerebrospinal fluid from patients with acute aseptic meningitis and no cutaneous lesions. *J Med Virol* 1994;43:331–5.
- [28] Gildden DH, Bennett JL, Kleinschmidt-DeMasters BK, Song DD, Yee AS, Steiner I. The value of cerebrospinal fluid antiviral antibody in the diagnosis of neurologic disease produced by varicella zoster virus. *J Neurol Sci* 1998;159:140–4.
- [29] Schmidt NJ. Further evidence for common antigens in herpes simplex and varicella-zoster viruses. *J Med Virol* 1982;9:27–36.
- [30] Tien RD, Felsberg GJ, Osumi AK. Herpesvirus infections of the CNS: MR findings. *AJR* 1993;161:167–76.
- [31] Leonard JR, Moran CJ, Cross III DT, Wippold II FJ, Schlesinger Y, Storch GA. MR Imaging of herpes simplex type I encephalitis in infants and young children: a separate pattern of findings. *AJR* 2000; 174:1651–5.
- [32] Kleinschmidt DeMasters BK, Amlie-Lefond C, Gildden DH. The patterns of varicella zoster virus encephalitis. *Hum Pathol* 1996;27:927–38.
- [33] Somer T, Finegold SM. Vasculitides associated with infections, immunization, and antimicrobial drugs. *CID* 1995;20:1010–36.
- [34] Carmack MA, Twiss J, Enzmann DR, Amylon MD, Arvin AM. Multifocal leukoencephalitis caused by varicella-zoster virus in a child with leukemia: successful treatment with acyclovir. *Pediatr Infect Dis* 1993; 12:402–6.
- [35] Adams C, Diadori P, Schoenroth L, Fritzier M. Autoantibodies in childhood post-varicella acute cerebellar ataxia. *Can J Neurol Sci* 2000;27:316–20.
- [36] Débat Zoguéréh D, Saadoun R, Zandotti C, Cawston P, Moreau J. AIDS-related varicella zoster meningoencephalitis and radicular pain without cutaneous eruption. *AIDS* 1996;10:1604–6.
- [37] Munyer TP, Mangi RJ, Dolan T, Kantor FS. Depressed lymphocyte function after measles–mumps–rubella vaccination. *J Infect Dis* 1975;132:75–8.
- [38] Ziola B, Karvonen B, Stewart J. Prior infection by respiratory syncytial virus or parainfluenza viruses augments virus-specific IgG responses induced by the measles/mumps/rubella vaccine. *Viral Immunol* 1994; 7:205–14.
- [39] Forster J, Urbanek R. Encephalitis following measles–mumps vaccination simultaneous to an EBV infection. *Klin Pädiatr* 1982;194:29–30.