

Pediatric Granulomatous Cerebral Amebiasis: A Delayed Diagnosis

Marcelo Galarza, MD, Vicente Cuccia, MD,
Fidel P. Sosa, MD, and Jorge A. Monges, MD

We present four cases of cerebral amebae infection treated at our neurosurgical department. Patient 1 was a 12-year-old male with skin lesions of 2 years' progression involving the midface. He received a corticosteroid course, and, after that, he presented a right body hemiparesis. Patient 2 was a 5-year-old male, with a past surgical history of fibula fracture and osteomyelitis of 1-year evolution, associated with lesions of the surrounding skin that presented with partial seizures. Patient 3 was a 3-year-old female who presented with a stroke-like episode and with partial seizures. Patient 4 was a 6-year-old male who had ulcerative lesions in the face of 1-year evolution. After a corticosteroid course, he presented with right-body hemiparesis. All patients were human immunodeficiency virus-negative and died 1 month or less after surgery because of progressive evolution of the disease. Histopathology revealed granulomatous amebic encephalitis. All patients revealed infection from *Balamuthia mandrillaris* (Leptomyxiidae). Treatment consisting of pentamidine, clarithromycin, fluconazole, and 5-fluorocytosine was ineffective. Although extremely uncommon, granulomatous amebic encephalitis should be considered in the differential diagnosis of cerebral lesions while nonspecific, associated granulomatous skin lesions support the diagnosis of amebiasis. © 2002 by Elsevier Science Inc. All rights reserved.

Galarza M, Cuccia V, Sosa FP, Monges JA. Pediatric granulomatous cerebral amebiasis: A delayed diagnosis. *Pediatr Neurol* 2002;26:153-156.

Introduction

Free-living amebas, such as *Naegleria fowleri*, *Acanthamoeba*, and *Balamuthia*, have been known to cause fatal meningoencephalitis since Fowler and Carter reported the first four human cases in 1965 [1]. Amebic diseases have been reported with increased frequency in the last years because of better recognition of the entity. However, because of its difficult pathologic diagnosis, a subregistry of the entity still exists [2-4]. Although extremely rare, infection usually affects immunocompromised persons of any age [2,4]. The disease becomes evident in two different clinical fashions: primary amebic meningoencephalitis, which is caused mainly by *Naegleria fowleri*, and granulomatous amebic encephalitis, which is principally induced by species of *Acanthamoeba* and *Balamuthia* [5,6]. We report our experience at the National Pediatric Hospital of Buenos Aires, describing four patients affected by this infectious disease. Of a total of 1,100 cerebral tumors operated from 1988-2000 at the Department of Neurosurgery, we describe three (0.27%) patients with free-living ameba infection and a fourth patient who was referred to us for consultation. These patients required surgery for presumptive diagnosis of cerebral neoplasia on imaging studies or for progressive cerebral lesions without diagnosis.

Case Reports

Patient 1

A 12-year-old male was transferred to our hospital for diagnosis of granulomatous noncaseous skin and soft tissue lesions involving the midface. The lesions had progressed for 2 years without diagnosis. Because of a presumptive histopathology diagnosis of sarcoidosis performed in the skin lesions, the child received a prednisone course. After that, he presented with fever, increased lethargy, and right body hemiparesis. Noncontrast computed tomography (CT) demonstrated multiple hypodense cerebral lesions in both hemispheres. On magnetic resonance imaging (MRI) without contrast the child presented multiple cerebral isointense to slightly hyperintense lesions on T₁-weighted images and hyperintensity lesions on T₂-weighted images (Fig 1). The lesions involved cerebral hemispheres, brainstem, and cerebellum. No enhancement was observed after administration of gadolinium diethylenetriamine penta-acetic acid. A frontal craniotomy with resection of a cortical lesion was performed. The resected specimen consisted of an irregularly rounded soft and grayish mass without gross infiltration of normal tissue. Histopathologic examination revealed granulomatous infection and perivascular trophozoites, which were difficult to distinguish morphologically from macrophages. Indirect immunofluorescence

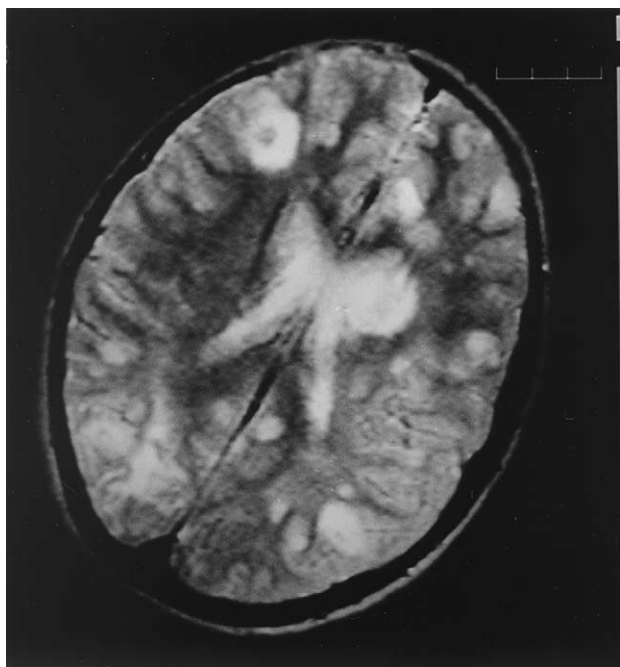


Figure 1. Patient 1. Axial T₂-weighted image MRI scan without contrast, obtained for the diagnostic determination of acute neurologic deterioration after a corticosteroid course in a 12-year-old male with midface granulomatous lesions. Multiple hyperintense cortico-subcortical lesions involving the entire cerebrum.

test revealed central nervous system infection with *Balamuthia mandrillaris*. Final neuropathologic report was granulomatous cerebral amebiasis. The patient received pentamidine, 5-fluorocytosine, and fluconazole at usual doses. However, 1 month after surgery he died because of septic shock and progressive coma. Parents rejected authorization for postmortem examination.

Patient 2

A 5-year-old male, with a past surgical history of fibula fracture with chronic osteomyelitis evolving for 1 year associated with nonspecific granulomatous lesions of the surrounding skin, was admitted to the emergency room. The child presented clonic upper limb seizures and progressive loss of consciousness. No fever was evident. Noncontrast CT scanning revealed multiple hypodense cerebral lesions. The lesions mainly involved both frontal lobes. No hydrocephalus was evident. Mild enhancement was evident in one of the cortical lesions after contrast administration. Electroencephalogram revealed bilateral temporal spikes. The child persisted in a semicomatose state without diagnosis. It was decided that a brain biopsy would be performed on the most evident lesion. After resection of a frontal lesion through a right frontal craniotomy, histopathologic examination revealed necrotizing encephalitis, amebic trophozoites, and cysts in brain parenchyma. Immunofluorescence test revealed central nervous system infection with *Balamuthia mandrillaris*. Granulomatous amebic encephalitis was the most consistent diagnosis for this patient. After surgery, the child received pentamidine, 5-fluorocytosine, fluconazole, and clarithromycin at usual doses. Nonetheless, 2 weeks after admission, the child died because of a multiorgan failure syndrome and progressive coma. Parents denied permission for postmortem examination.

Patient 3

A 3-year-old female, previously healthy, presented with clonic partial seizures involving the left hemibody associated with profound deterior-

ation in level of consciousness. After this acute episode, she presented with a progressive paresis of left hemibody. No fever was evident. After 2 months, the child was presented to our hospital without neurologic diagnosis. Electroencephalogram revealed right frontal and bilateral temporal spikes. CT scanning demonstrated a hyperdense lesion involving right frontal lobe, which mildly enhanced after administration of contrast (Fig 2A). MRI demonstrated the lesion as heterogeneous and iso-hyperintense on T₁-weighted images (Fig 2B); and markedly hyperintense on T₂-weighted images. A homogeneous enhancement was evident after contrast administration. By using a right frontal approach, the lesion was radically resected. The specimen consisted of a soft, white-grayish mass. The microscopic examination disclosed patchy, subacute granulomatous encephalitis with the presence of trophozoites and cysts. *Balamuthia mandrillaris* was confirmed to be the infecting agent on immunofluorescence studies. The child received broad-spectrum antibiotics (pentamidine, 5-fluorocytosine, fluconazole, and clarithromycin) at high doses. However, the child developed hydrocephalus and coma progressing to death 18 days after onset of symptoms. Parents denied permission for postmortem examination.

Patient 4

A 6-year-old male was seen in a community hospital for ulcerative cutaneous lesions in the face that had evolved for 1 year. A previous biopsy demonstrated an inflammatory granulomatous lesion with vasculitis. Because of a presumptive diagnosis of Wegener granulomatosis, he received corticosteroid therapy. After that, he presented with neurologic symptoms, including right body hemiparesis and consciousness deterioration, associated with a left parietal and occipital lesion on imaging studies. The lesion appeared hypodense without enhancement on CT scanning. On MRI examination the lesion was homogeneous, hypointense on T₁-weighted images and hyperintense on T₁-weighted images without enhancement after administration of gadolinium diethylenetriamine pentaacetic acid. A cerebral biopsy was performed at the community hospital and, after that, the patient was referred to our hospital with the biopsy material. Neuropathologic examination disclosed a necrotic granulomatous lesion with vasculitis and isolated amebic structures. Immunofluorescence test revealed central nervous system infection with *Balamuthia mandrillaris*. He received pentamidine, 5-fluorocytosine, fluconazole, and clarithromycin at usual doses. Nonetheless, 1 week after admission, the patient presented with continued generalized seizures and lethargy, progressing to coma and death. Parents denied permission for postmortem examination.

Discussion

We describe three patients of ameba infection who underwent surgery for either presumptive diagnosis of cerebral neoplasia on imaging studies or for progressive cerebral lesions without diagnosis. A fourth case was initially admitted at a community hospital and referred to our institution for diagnosis and treatment. One of the present patients has been previously reported [5].

Free-living amebas etiologically associated with central nervous system infection in children have included *Acanthamoeba*, *Naegleria*, and, recently, *Balamuthia mandrillaris* (Leptomyxiidae). These opportunistic protozoa are ubiquitous in nature. Amebas are found in soil, water, and air samples from all over the world. The epidemiology, immunology, protozoology, pathology, and clinical features of the infections produced by these protozoa vary markedly [2-8]. The portal of entry is likely through the respiratory tract or an ulceration of the skin reaching the

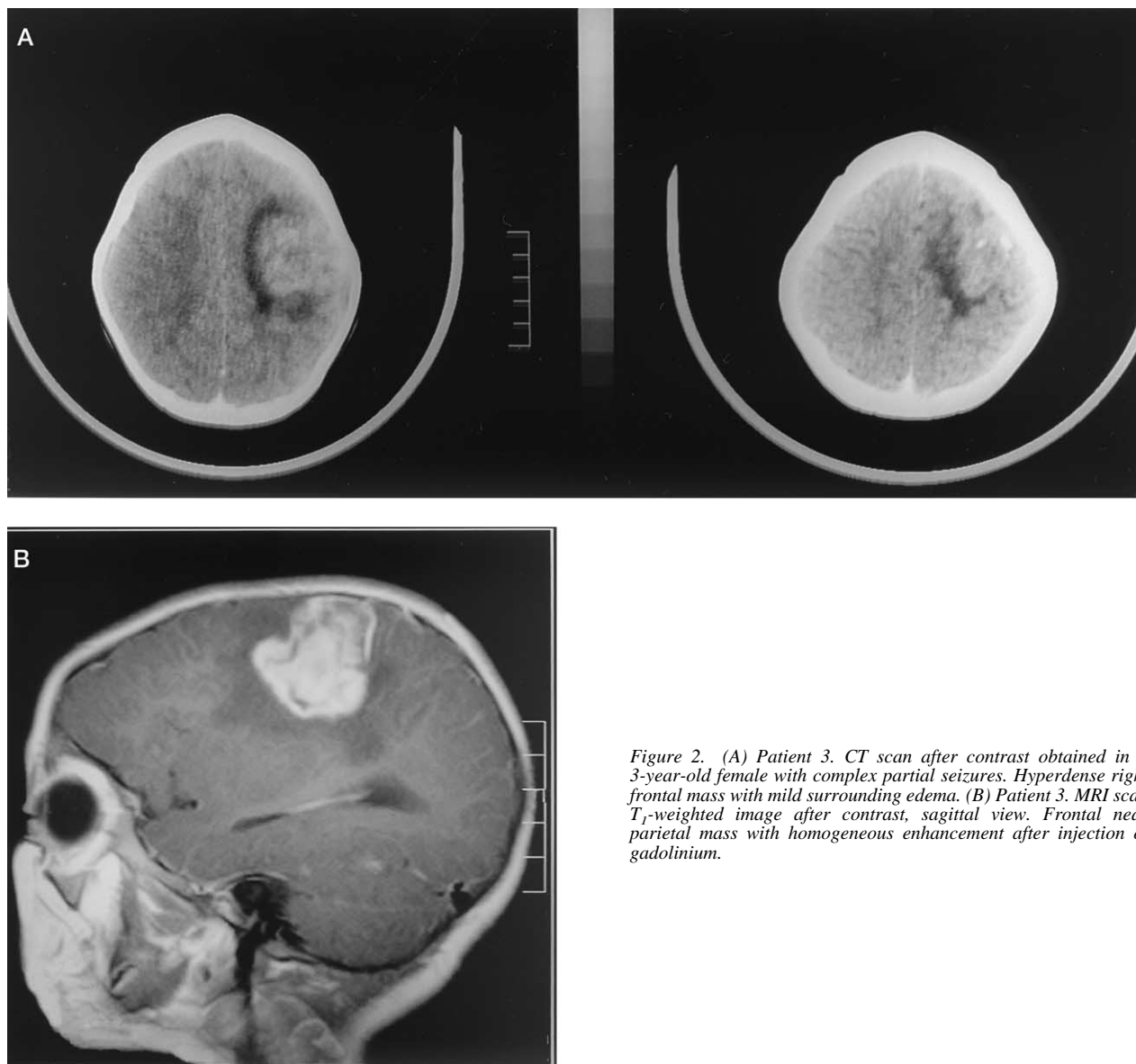


Figure 2. (A) Patient 3. CT scan after contrast obtained in a 3-year-old female with complex partial seizures. Hyperdense right frontal mass with mild surrounding edema. (B) Patient 3. MRI scan T_1 -weighted image after contrast, sagittal view. Frontal near parietal mass with homogeneous enhancement after injection of gadolinium.

central nervous system by hematogenous spread. Nonetheless, human infection resulting from these amebas, involving brain, skin, lung, and eyes has increased significantly during the last 10 years [8-13]. Immunosuppression and debilitating illnesses are associated with multifocal or unifocal brain lesions from *Acanthamoeba* and *Balamuthia* species. These illnesses include granulomatous amebic encephalitis, which is distinct from the acute, water sport-related primary amebic meningoencephalitis that is caused by *Naegleria fowleri* [7-9,14,15]. Granulomatous amebic encephalitis is an infection that is usually observed in debilitated, malnourished individuals, in patients undergoing immunosuppressive therapy for organ transplants, and in patients with acquired immunodeficiency syndrome. It has a much more prolonged course than primary amebic meningoencephalitis characterized by mass lesions of the central nervous system in its terminal stages and has an even more consistently fatal

outcome. All of our patients were negative for human immunodeficiency virus. Three of our patients presented with chronic infections of the skin and mucosae. Corticosteroid therapy was performed in two of these patients, resulting in acute neurologic deterioration in both patients after that.

No characteristic clinical presentation, laboratory results, or radiologic findings have been found to be particularly associated with granulomatous amebic encephalitis. Cerebrospinal fluid studies may disclose a mononuclear pleocytosis or mildly elevated protein [16]. However, these are inconsistent findings [9,11,16]. Cerebrospinal fluid examination was performed in both children with multifocal lesions and disclosed normal results. CT or MRI studies usually demonstrate one or more contrast-enhancing lesions that are nonspecific and could be observed in other conditions, such as bacterial abscesses, fungal infections, tuberculomas, toxoplasmosis, or neo-

plasm [10,13,14]. Diffuse edema may be evident on imaging studies and, in the case of granulomatous amebic encephalitis, there is evidence of large and small arterial occlusion with subsequent infarction [10]. Of our series of patients, two patients presented with multifocal lesions on CT and MRI examination, one child revealed a frontal tumor and the fourth exhibited a parieto-occipital tumor.

Brain biopsy or surgical resection is important in diagnosing granulomatous amebic encephalitis and may be part of curative treatment if the disease has not evolved to diffuse encephalitis [16]. Granulomatous amebic encephalitis revealed a marked necrotizing granulomatous chronic inflammatory reaction with angiitis. However, the granulomatous component could be negligible, particularly in immunocompromised individuals [3,15-18]. In the present series, brain biopsy demonstrated no granuloma formation in two of the patients but did reveal severe necrotizing chronic inflammation with angiitis and thrombosis. Special stains were negative for fungus and mycobacteria. Culture for microorganisms was negative in all patients. The differential diagnoses included infectious process, sarcoidosis, and lymphomatoid granulomatosis. Two of our patients presented with previous diagnoses of sarcoidosis and Wegener granulomatosis. A third patient demonstrated a nonspecific granulomatous skin lesion associated with an osteomyelitis of the leg. Once the diagnosis of granulomatous amebic encephalitis was made, amebas were typified through indirect immunofluorescence at the Centers for Disease Control and Prevention (Atlanta, GA, USA).

Treatment of cerebral amebiasis is usually late and nonspecific. Some in vitro studies demonstrate that pentamidine, azithromycin, and certain phenothiazines can inhibit the growth of *Balamuthia*, but none are amebicidal at nontoxic concentrations [9,13,16,18]. In fact, treatment was not effective in our patients, mainly because of the late diagnosis. All our patients died in a short period after conclusive diagnosis of granulomatous amebic encephalitis.

Although extremely uncommon, granulomatous amebic encephalitis should be considered in the differential diagnosis of cerebral lesions, especially when associated with chronic mucocutaneous wounds. Nonetheless, the number of pediatric cerebral amebiasis in a single community is too small for appraisal of final conclusions.

References

- [1] **Fowler M**, Carter RF. Acute pyogenic meningitis probably due to *Acanthamoeba* sp.: A preliminary report. *BMJ* 1965;5464:740-2.
- [2] **Martinez AJ**, Garcia CA, Halks-Miller M, Arce-Vela R. Granulomatous amebic encephalitis presenting as a cerebral mass lesion. *Acta Neuropathol (Berl)* 1980;51:85-91.
- [3] **Huang ZH**, Ferrante A, Carter RF. Serum antibodies to *Balamuthia mandrillaris*, a free-living amoeba recently demonstrated to cause granulomatous amebic encephalitis. *J Infect Dis* 1999;179:1305-8.
- [4] **Martinez AJ**, Visvesvara GS. Free-living, amphizoic and opportunistic amebas. *Brain Pathol* 1997;7:583-98.
- [5] **Taratuto AL**, Monges J, Acefe J. Leptomyxid amoeba encephalitis: Report of the first case in Argentina. *Trans R Soc Trop Med Hyg* 1991;85:77-8.
- [6] **Villegas J**, Mercado CA, De Lachica M. Generalized amebiasis in children. Report of 4 cases of cerebral amebiasis. *Rev Invest Salud Publica* 1968;28:193-220.
- [7] **Cerva L**, Novak K. Amoebic meningoencephalitis: 16 fatalities. *Science* 1968;160:92-3.
- [8] **Visvesvara GS**, Stehr-Green JK. Epidemiology of free-living amoeba infections. *J Protozool* 1990;37:25-33.
- [9] **Griesemer DA**, Barton LL, Reese CM, et al. Amebic meningoencephalitis caused by *Balamuthia mandrillaris*. *Pediatr Neurol* 1994;10:249-54.
- [10] **Schumacher DJ**, Tien RD, Lane K. Neuroimaging findings in rare amebic infections of the central nervous system. *Am J Neuroradiol* 1995;16(Suppl):930-5.
- [11] **Duke BJ**, Tyson RW, DeBiasi R, Freeman JE, Winston KR. *Balamuthia mandrillaris* meningoencephalitis presenting with acute hydrocephalus. *Pediatr Neurosurg* 1997;26:107-11.
- [12] **Chimelli L**, Hahn MD, Scaravilli F, Wallace S, Visvesvara GS. Granulomatous amoebic encephalitis due to leptomyxid amoebae: report of the first Brazilian case. *Trans R Soc Trop Med Hyg* 1992;86:635-6.
- [13] **Lasner TM**, Sutton LN, Rorke LB. Multifocal noninfectious granulomatous encephalitis in a child. Case report. *J Neurosurg* 1997;86:1042-5.
- [14] **Lowichik A**, Rollins N, Delgado R, Visvesvara GS, Burns DK. Leptomyxid amebic meningoencephalitis mimicking brain stem glioma. *Am J Neuroradiol* 1995;16(Suppl):926-9.
- [15] **Koide J**, Okusawa E, Ito T, et al. Granulomatous amoebic encephalitis caused by *Acanthamoeba* in a patient with systemic lupus erythematosus. *Clin Rheumatol* 1998;17:329-32.
- [16] **Deol I**, Robledo L, Meza A, Visvesvara GS, Andrews RJ. Encephalitis due to a free-living amoeba (*Balamuthia mandrillaris*): Case report with literature review. *Surg Neurol* 2000;53:611-6.
- [17] **Kodet R**, Nohynkova E, Tichy M, Soukup J, Visvesvara GS. Amebic encephalitis caused by *Balamuthia mandrillaris* in a Czech child: Description of the first case from Europe. *Pathol Res Pract* 1998;194:423-9.
- [18] **Ma P**, Visvesvara GS, Martinez AJ, Theodore FH, Daggett PM, Sawyer TK. *Naegleria* and *Acanthamoeba* infections: Review. *Rev Infect Dis* 1990;12:490-513.