

Cerebral vasculitis in a child following post-streptococcal glomerulonephritis

W WONG and MC MORRIS

Renal Unit, Starship Children's Hospital, Auckland, New Zealand

Abstract: Cerebral vasculitis following acute post-streptococcal glomerulonephritis (APSGN) is a rare neurological complication. An 11-year-old girl with biopsy proven APSGN developed an acute seizure disorder. Clinical and computed tomography findings were consistent with vasculitis.

Key words: post-streptococcal glomerulonephritis; seizures; vasculitis.

Acute post-streptococcal glomerulonephritis (APSGN) has become an uncommon cause of acute renal disease in many developed countries. In contrast, APSGN remains a frequent and important cause of acute renal disease in New Zealand. A recent audit of admissions to inpatient paediatric facilities in our region has shown an overall annualized rate of 11.5 cases per 100 000 children under 15 years of age. The burden of disease is fivefold higher in Maori children and 10-fold higher in Pacific Island children than in European children (S Bhatia *et al.*, unpubl. obs., 1999).

The clinical severity of APSGN is variable, with some children having mild disease and being asymptomatic.¹ Rarely, APSGN may be associated with rapidly progressive glomerulonephritis with severe acute renal failure requiring dialysis.²

Central nervous system abnormalities are uncommon and are thought to be secondary to acute severe hypertension, electrolyte disturbances and uraemia.³ Post-streptococcal glomerulonephritis may also present with hypertensive encephalopathy with seizures.³ A rare complication of central nervous system involvement is vasculitis, which has been previously described in children with APSGN.^{4,5} The present report describes a child who developed cerebral vasculitis and a crescentic glomerulonephritis after a streptococcal infection.

CASE REPORT

An 11-year-old girl was transferred from a peripheral hospital with a 6 day history of nausea, vomiting, epigastric pains and 3 days of poor urine output and dark coloured urine. She had been well previously and was not on any medications. On arrival, she was mildly dehydrated, with a blood pressure of 113/70 mmHg. There were a number of healing impetiginous lesions on both hands and feet. She also had a heliotropic rash over the bridge of her nose. Blood tests showed her haemoglobin was 124 g/L, the leucocyte count was 26.2×10^9 /L, potassium was 6.5 mmol/L, urea was 76 mmol/L and creatinine was 1340 μ mol/L. An ultrasound scan showed large echogenic kidneys without focal abnormality.

Urgent peritoneal dialysis was commenced and a renal biopsy obtained on day 3 showed almost 100% of all glomeruli affected with cellular crescents. All glomeruli showed infiltration by neutrophils and increased cellularity with obliteration of capillary loops. Arteries and arterioles were normal. Immunofluorescence showed coarse granular membranous staining for IgG and C3. Electron microscopy showed subepithelial humps. The appearances were consistent with crescentic glomerulonephritis secondary to APSGN. The patient's antistreptolysin titre was 515 IU (normal < 280 IU) and the antistreptokinase titre was > 20 480 IU (normal < 640 IU). Her C3 complement was 0.63 g/L (normal 0.8–1.8 g/L). The patient was immediately commenced on daily pulses of methylprednisolone for 3 days. This was followed by two further doses on alternate days before switching to daily oral prednisone at 1 mg/kg per day.

On day 5 of admission, the patient developed severe headaches and blurred vision and subsequently had a generalized seizure. At the time, her blood pressure was 120/70 mmHg, calcium was 2.27 mmol/L, phosphate was 4.9 mmol/L, magnesium was 1.09 mmol/L, sodium was 137 mmol/L and urea was 48 mmol/L. A computed tomography (CT) scan of her brain the following day showed several areas of hypodensity in the cerebellar hemispheres and in the right frontal lobe, consistent with infarction or vasculitis (Fig. 1). An electroencephalogram showed focal disturbance in the right hemisphere and background slowing of activity. Serological tests for systemic lupus erythematosus (antinuclear antibody screen, double-stranded DNA) were negative. Antineutrophil cytoplasmic antibodies and antiglomerular basement antibodies were not detected.

The patient continued to have focal and generalized seizures for a further 4 days and required treatment with diazepam, phenytoin, phenobarbitone and carbamazepine.

Peritoneal dialysis and nutritional support continued until day 28, when she recovered sufficient renal function to become independent of dialysis. Upon discharge from hospital, her plasma creatinine was 280 μ mol/L. Her anticonvulsants were discontinued without recurrence of her seizures and subsequent neurological examination was normal.

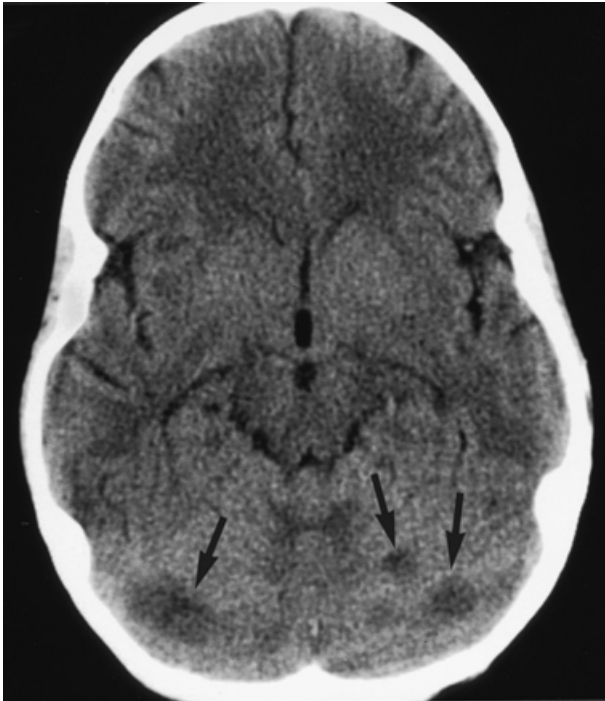


Fig. 1 Patient's cerebral computed tomography scan showing several areas of hypodensity in the cerebellar hemispheres. There is no evidence of cerebral oedema.

The patient was seen 6 weeks later and her creatinine level had fallen to 80 $\mu\text{mol/L}$. She was normotensive, but her urine showed 3+ of protein and 4+ blood.

DISCUSSION

Streptococcal infections are known to cause vasculitic lesions affecting the brain, skin and other organ systems. Cerebral vasculitis following APSGN is thought to be rare, although there are no systematic cerebral imaging studies of patients with neurological signs and symptoms during acute APSGN. Nissenon *et al.* reported that 10% of children with APSGN had central nervous system symptoms.⁶ In our audit of 143 children under 15 years of age with APSGN, six children had seizures at the time of initial presentation (S Bhatia *et al.*, unpubl. obs., 1999). All had severe hypertension, as defined by criteria of the Second Task Force Report.⁷ Four of six children had cranial CT scans performed, one of which showed low-attenuation lesions in the occipital and posterior parietal cortex. These lesions may have been due to a combination of severe hypertension and a vasculitic process.

Severe headaches with nausea and vomiting are frequently encountered in patients with cerebral vasculitis. Our patient complained of moderately severe headaches with nausea shortly before the onset of seizures, a pattern that was repeated for 3 days. Transient focal neurological signs can also occur. Visual disturbances, such as blurred vision, transient visual

loss and ophthalmoplegia, may also occur.⁴ Vasculitis associated with APSGN appears to be rare, with only three other reports in the paediatric literature.^{4,5,8}

Our patient displayed signs and symptoms that are consistent with a cerebral vasculitis. She was normotensive and had a normal serum electrolyte profile at the time of her severe headaches and subsequent seizures. There were no signs of cerebral oedema on the CT scan. Although her plasma urea was 48mmol/L, at the time of her central nervous system disturbance this had been gradually falling during the previous 3 days, making a dysequilibrium syndrome very unlikely.

Pulse intravenous methylprednisolone was used to treat our patient's crescentic glomerulonephritis. Seizures are a well-recognized complication in adult renal transplants treated with pulse methylprednisolone. In non-transplant patients, Bettinelli *et al.*⁹ described two children who developed seizures and transient blindness following pulse intravenous methylprednisolone given for idiopathic nephrotic syndrome and endo-extra capillary glomerulonephritis. It is likely that the seizure threshold in our patient was reduced by a combination of a uraemic state, cerebral vasculitis and methylprednisolone. It is unlikely that the intravenous steroids would have caused the anatomical lesions seen on the CT scan.

The treatment of rapidly progressive or crescentic glomerulonephritis (RPGN) consists of immunosuppression with intravenous steroids often in combination with cyclophosphamide and or plasmapheresis.^{2,10} Of all the different causes of RPGN, post-streptococcal RPGN has the best prognosis for renal recovery. In a review by Couser of 76 patients with postinfectious RPGN, 50% recovered spontaneously without specific therapy, 18% partially recovered and 32% progressed to end-stage renal failure.¹¹ Although the prognosis was relatively good, a significant number of patients progressed and, therefore, in the setting of a child requiring acute dialysis and severe crescentic glomerulonephritis, treatment of our patient with intravenous methylprednisolone appeared justified in order to optimize her chances of full recovery.

Acute hypertension associated with APSGN may also cause seizures and six of 143 children presented with acute seizures secondary to severe hypertension. Significant hypertension was not present in our patient in the 3 days prior to her seizures. The mean of her blood pressure recordings was 115/70 mmHg with two spikes of up to 120/80 mmHg. These readings are below the 95th percentile for age and gender. Immediately after the seizure, her blood pressure was 127/82 mmHg, which is on the 95th percentile. Therefore, it seems unlikely that acute hypertension was a significant contributor to the development of this patient's seizure activity.

Cerebral vasculitis associated with APSGN in childhood appears to have an excellent prognosis for complete neurological recovery. The appearance of lesions on cerebral imaging and their complete resolution is consistent with transient vasculitis. Although rare, it should be considered in children who develop significant seizures, neurological signs and symptoms.

ACKNOWLEDGEMENTS

The authors thank Dr J Zwi, Auckland Hospital, for reviewing the histology.

REFERENCES

- 1 Sagel I, Treser G, Antonia TY *et al.* Occurrence and nature of glomerular lesions after group A streptococcal infections in children. *Ann. Intern. Med.* 1973; **79**: 492–9.
- 2 Jardim HM, Leake J, Risdon A *et al.* Crescentic glomerulonephritis in children. *Pediatr. Nephrol.* 1992; **6**: 231–5.
- 3 Yap HK, Low PS, Lee BW *et al.* Factors influencing the development of hypertensive encephalopathy in acute glomerulonephritis. *Child. Nephrol. Urol.* 1988–89; **9**: 147–52.
- 4 Rovang RD, Zawada ET, Santella RN *et al.* Cerebral vasculitis associated with acute post streptococcal glomerulonephritis. *Am. J. Nephrol.* 1997; **17**: 89–92.
- 5 Kaplan AL, Zwick DL, Hellerstein S, Warady BA, Alon U. Cerebral vasculitis in acute post-streptococcal glomerulonephritis. *Pediatr. Nephrol.* 1993; **7**: 194–5.
- 6 Nissenson AR, Baraff LJ, Fine RN, Knutson DW. Poststreptococcal acute glomerulonephritis: Fact or fiction. *Ann. Intern. Med.* 1979; **91**: 76–86.
- 7 Report of the Second Task Force on Blood Pressure Control in Children, 1987. *Pediatrics* 1987; **79**: 1–25.
- 8 Bodaghi E, Kheradpir KM, Maddah M. Vasculitis in acute post streptococcal glomerulonephritis. *Int. J. Pediatr. Nephrol.* 1987; **8**: 69–74.
- 9 Bettinelli A, Paterlini G, Mazzucchi E, Giani M. Seizures and transient blindness following intravenous pulse methylprednisolone in children with primary glomerulonephritis. *Child. Nephrol. Urol.* 1991; **11**: 41–3.
- 10 Jindal KK. Management of idiopathic crescentic and diffuse proliferative glomerulonephritis. Evidence-based recommendations. *Kidney Int.* 1999; **70** (Suppl. Jun): S33–40.
- 11 Couser WG. Rapidly progressive glomerulonephritis. Classification, pathogenetic mechanisms and therapy. *Am. J. Kidney Dis.* 1988; **11**: 449–64.