

Posterior Cerebral Artery Occlusion Associated With *Mycoplasma pneumoniae* Infection

Charalampos Antachopoulos, Theodota Liakopoulou, Fani Palamidou, Dimitra Papathanassiou and Sotiris Youroukos

J Child Neurol 2002 17: 55

DOI: 10.1177/088307380201700115

The online version of this article can be found at:

<http://jcn.sagepub.com/content/17/1/55>

Published by:



<http://www.sagepublications.com>

Additional services and information for *Journal of Child Neurology* can be found at:

Email Alerts: <http://jcn.sagepub.com/cgi/alerts>

Subscriptions: <http://jcn.sagepub.com/subscriptions>

Reprints: <http://www.sagepub.com/journalsReprints.nav>

Permissions: <http://www.sagepub.com/journalsPermissions.nav>

Citations: <http://jcn.sagepub.com/content/17/1/55.refs.html>

>> [Version of Record](#) - Jan 1, 2002

[What is This?](#)

Posterior Cerebral Artery Occlusion Associated With *Mycoplasma pneumoniae* Infection

ABSTRACT

Cerebral infarction is a rare complication of *Mycoplasma pneumoniae* infection. In all cases previously reported in the literature, vascular occlusion occurred in the anterior brain circulation, either the internal carotid or the middle cerebral artery. We report a case of a child with posterior cerebral artery occlusion and resultant hemiparesis associated with *M. pneumoniae* infection. (*J Child Neurol* 2002;17:55–57).

Cerebral infarction is a rare neurologic complication of *Mycoplasma pneumoniae* infection. It is usually manifested as hemiparesis^{1–4} but has also been associated with facial palsy.⁵ A total of nine cases of cerebral infarction after serologically proven *M. pneumoniae* infection have been reported in the literature, including four adults and five children.^{1–5} In all of these cases, vascular occlusion occurred in the anterior circulation of the brain, either in the internal carotid or the middle cerebral artery, a fact that has been pointed out by previous authors.⁴ We report a case of posterior cerebral artery occlusion in an 8-year-old boy after *M. pneumoniae* infection.

Case Report

An 8-year-old boy was referred to our department with a 2-day history of acute-onset, right-sided hemiparesis. Two weeks prior to admission, he had developed a dry cough, followed by moderate fever 5 days later. At that time, he was seen by a pediatrician and was treated with a course of oral cefprozil and inhaled salbutamol. His past medical and family history were unremarkable, apart from the fact that his mother had the sickle cell trait.

On admission, he was afebrile, fully conscious, and oriented, with a blood pressure of 110/70 mm Hg. Muscle strength was markedly diminished in the right arm and leg, but sensation was normal. Tendon reflexes were asymmetric, more brisk on the right side. Babinski reflexes were present on the right. Cranial nerves were intact. The rest of the physical examination, including cardiovascular and respiratory systems, was unremarkable.

Brain computed tomography (CT) on admission demonstrated a small area of decreased density in the left thalamus. This finding was confirmed by a magnetic resonance imaging (MRI) scan 2 days later, which revealed an infarct in the left thalamus also affecting the posterior part of the internal capsule (Figure 1). Magnetic resonance arteriography of the brain, performed on the same day, demonstrated marked stenosis (almost complete occlusion) of the left posterior cerebral artery near the bifurcation of the basilar artery, with faint signal of the distal branches of the left posterior cerebral artery (Figure 2).

Laboratory investigations revealed a white blood cell count of 17,300/ μ L, with 86% neutrophils, 8% lymphocytes, and 6% monocytes; hemoglobin 12.3 g/dL; and platelets 353,000/ μ L. The biochemistry and lipid profile were within normal limits. Hemoglobin studies revealed the presence of Hb S at 38.5% and Hb F at 0.7%, with a confirmatory sickle testing. These findings were consistent with sickle cell trait. Extensive coagulation studies, including plasma levels of clotting factors, serum proteins C and S, plasminogen and antithrombin III, and testing for the lupus anticoagulant, did not reveal any abnormalities. Anticardiolipin, antinuclear, and anti-DNA antibody tests were negative. Screening for homocystinuria in plasma and urine was negative. The cerebrospinal fluid, chest radiography, electrocardiography, and echocardiography, were normal. Antibodies to specific infectious agents that are known to be associated with stroke, such as varicella-zoster virus, *Chlamydia pneumoniae*, and *Borrelia burgdorferi*,⁶ were negative. However, antibody titers to *M. pneumoniae*, determined by the enzyme-linked immunosorbent assay, were IgG 1:1280 and IgM 1:1280 2 days post admission, followed by IgG 1:640 and IgM negative 3 weeks later. These findings indicated acute *M. pneumoniae* infection.⁷

The patient was given a 2-week course of clarithromycin and a 1-month course of low-dose aspirin (1 mg/kg of body weight daily). Early physiotherapy was also started. There was a remarkable and steady improvement of motor function. He was re-examined 3 months later, and only mild pyramidal signs could be seen on the right side. A repeated magnetic resonance arteriography of the brain demonstrated persistence of the stenosis in the proximal part of the left posterior cerebral artery, with an almost normal signal of the distal branches of the left posterior cerebral artery.

Discussion

Our patient was extensively investigated for possible causes of cerebral infarction and was found to have serologic evidence of recent *M. pneumoniae* infection, which was consistent with the relevant history of cough and fever. He was also found to have the sickle cell trait. Although cerebral infarction is a rare but recognized complication of *M. pneumoniae* infection, one could question the role of the sickle cell trait in this case. Sickle cell trait is associated with a benign clinical course and is not a recognized risk factor for ischemic stroke in children. Vaso-occlusive complications may occur only in the presence of predisposing factors leading to severe hypoxia, such as general anesthesia.⁸ Such conditions were not suggested by the patient's history.

By reviewing the literature, we did find two reports of cerebral infarction in children with the sickle cell trait in whom no predisposing factor to hypoxia was identified by the authors.^{9,10} One

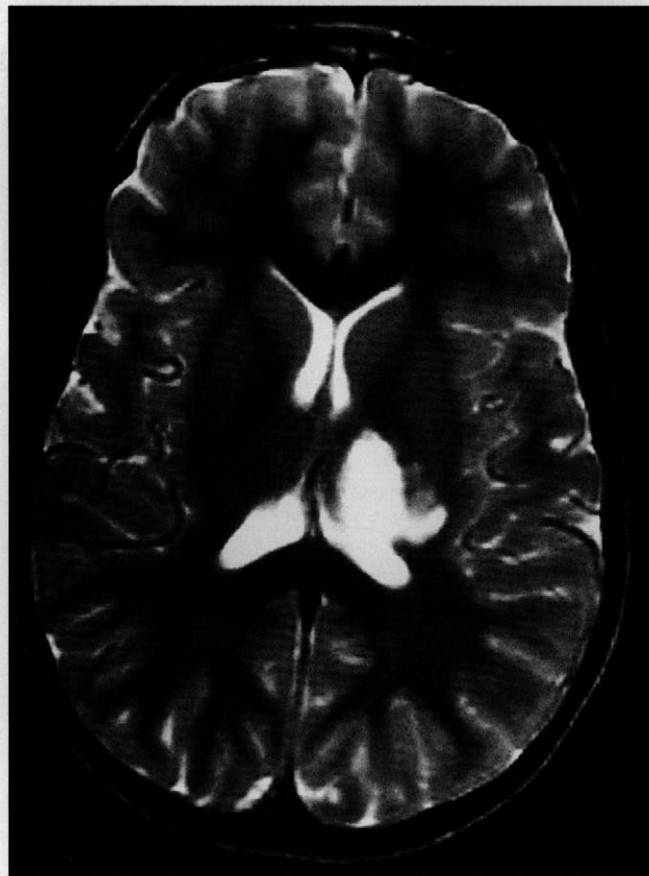


Figure 1. T₂-weighted MRI demonstrating infarction in the area of left thalamus also affecting the posterior part of the internal capsule.

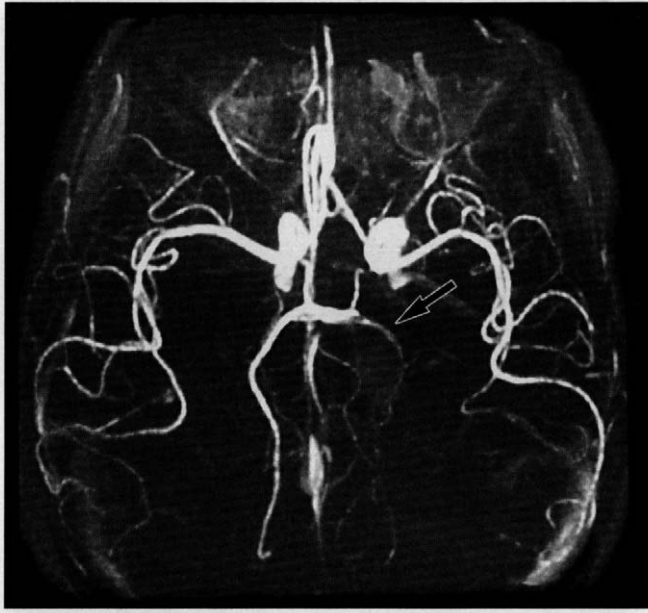

Figure 2. Magnetic resonance arteriography demonstrating almost complete occlusion of the left posterior cerebral artery near the bifurcation of the basilar artery.

should be very cautious, however, when evaluating these two cases. The failure to identify any precipitating or other risk factors for ischemic stroke in these patients does not necessarily imply the lack of their existence. The frequency of sickle cell trait is high in certain population groups (about 8% in African Americans),⁸ and if this was indeed a risk factor for stroke in childhood, far more than two cases should have been reported in the literature. Consequently, the primary cause of the posterior cerebral artery infarct in our patient was thought to be the recent *Mycoplasma* infection. However, given the fact that the precise mechanism of neurologic complications associated with *M. pneumoniae* has not yet been elucidated, the possibility that the presence of Hb S (38.5%) played a role in the sequence of events triggered by the *Mycoplasma* infection could not be excluded.

Besides cerebral infarction, *M. pneumoniae*-associated neurologic complications include encephalitis, meningoencephalitis, myelitis, neuropathies, Guillain-Barré syndrome, ataxia, choreoathetosis, and psychosis.^{7,11-14} Cerebral infarction is a rare complication, with a total of four adult and five pediatric cases reported to date, all involving the anterior brain circulation (internal carotid, middle cerebral artery).¹⁻⁵ Our patient is the first case reported in whom the infarct involved the posterior brain circulation.

In the above five pediatric patients with *M. pneumoniae*-associated cerebral infarction (aged 4–12 years, including four girls), vascular occlusion occurred 6 to 10 days after the onset of the respiratory illness.¹⁻⁵ It was manifested as hemiparesis (four cases)¹⁻⁴ or isolated facial palsy (one case),⁵ without changes in mental status. Conventional or magnetic resonance angiography confirmed the diagnosis in three patients,²⁻⁴ whereas in the remaining two children, cerebral infarction was demonstrated on a CT or MRI brain scan.^{1,5} In all cases, *Mycoplasma* infection was established serologically by enzyme-linked immunosorbent assay or a complement fixation test. Isolated facial palsy resolved within 2 weeks.

The course of hemiparesis varied from complete resolution within 2 months to permanent mild unilateral spasticity.

The pathogenesis of neurologic complications after *Mycoplasma* infection is not fully understood. Different mechanisms have been proposed, including direct invasion of the central nervous system by the organism, production of autoantibodies, or formation of immune complexes and, less likely, the release of neurotoxin.^{1-5,11-14} The uncertainty of the pathogenesis makes the treatment of these complications difficult. Depending on the patient's condition, antibiotics, corticosteroids, other anti-inflammatory agents, and plasma exchange have been tried, with variable results.^{1-5,7,11-14} The use of low-dose aspirin (1 mg/kg of body weight daily) has been advocated by some authors for patients with vascular occlusion.⁶ Prognosis is related to the type of neurologic complication. Mortality is higher in patients with encephalitis or polyneuropathy, reaching 8 to 10%. Full recovery is common, but up to one third of patients may have permanent neurologic sequelae.^{2,5,11,14} This outcome could probably be improved with the implementation of new therapeutic strategies based on further research and understanding of the pathogenesis of central nervous system complications associated with *M. pneumoniae* infection.

Charalampos Antachopoulos, MD
Theodota Liakopoulou, MD
Fani Palamidou, MD
Dimitra Papathanassiou, MD
Sotiris Youroukos, MD
First Department of Pediatrics
Athens University
"Aghia Sophia" Children's Hospital
Athens, Greece

Received Feb 12, 2001. Received revised July 12, 2001. Accepted for publication July 27, 2001.

Address correspondence to Dr Sotiris Youroukos, 15 Gounari str., 15124 Marousi, Athens, Greece. Tel: 00301-8061714; fax: 00301-8023703; e-mail: sotel@hol.gr.

References

1. Parker P, Puck J, Fernandez F: Cerebral infarction associated with *Mycoplasma pneumoniae*. *Pediatrics* 1981;67:373-375.
2. Visudhiphan P, Chiemchanya S, Sirinavin S: Internal carotid artery occlusion associated with *Mycoplasma pneumoniae* infection. *Pediatr Neurol* 1992;8:237-239.
3. Ganesan V, Savvy L, Chong WK, Kirkham FJ: Conventional cerebral angiography in children with ischemic stroke. *Pediatr Neurol* 1999;20:38-42.
4. Fu M, Wong KS, Lam WWM, Wong GWK: Middle cerebral artery occlusion after recent *Mycoplasma pneumoniae* infection. *J Neurol Sci* 1998;157:113-115.
5. Papaevangelou V, Falaina V, Syriopoulou V, Theodorou M: Bell's palsy associated with *Mycoplasma pneumoniae* infection. *Pediatr Infect Dis J* 1999;18:1024-1026.
6. Kirkham FJ: Stroke in childhood. *Arch Dis Child* 1999;81:85-89.
7. Thomas NH, Collins JE, Robb SA, Robinson RO: *Mycoplasma pneumoniae* infection and neurological disease. *Arch Dis Child* 1993;69:573-576.
8. Honig GR: Hemoglobin disorders, in Behrman RE, Kliegman RM, Jenson HB (eds): *Nelson Textbook of Pediatrics*, 16th ed. Philadelphia, WB Saunders, 2000, 1478-1488.
9. Riggs JE, Ketonen LM, Wang DD, Valanne LK: Cerebral infarction in a child with sickle cell trait. *J Child Neurol* 1995;10:253-254.

10. Leavitt JA, Butrus SI: Internuclear ophthalmoplegia in sickle cell trait. *J Neuroophthalmol* 1994;14:49-51.
11. Koskiniemi M: CNS manifestations associated with *Mycoplasma pneumoniae* infections: Summary of cases at the University of Helsinki and review. *Clin Infect Dis* 1993;17(Suppl 1):S52-S57.
12. Abramovitz P, Schwartzman P, Harel D, et al: Direct invasion of the central nervous system by *Mycoplasma pneumoniae*: A report of two cases. *J Infect Dis* 1987;155:482-487.
13. Fernandez CV, Bortolussi R, Gordon K, et al: *Mycoplasma pneumoniae* infection associated with central nervous system complications. *J Child Neurol* 1993;8:27-31.
14. Nishimura M, Saida T, Kuroki S, et al: Post-infectious encephalitis with anti-galactocerebroside antibody subsequent to *Mycoplasma pneumoniae* infection. *J Neurol Sci* 1996;140:91-95.

Prevalence of Hypopigmented Maculae and Café-au-lait Spots in Idiopathic Epileptic and Healthy Children

ABSTRACT

The cutaneous lesions and findings related to the central nervous system are frequently seen concomitantly in many patients. Neurocutaneous syndromes are the most typical examples supporting this observation. The prevalences of hypopigmented maculae and café-au-lait spots were investigated in 210 idiopathic epileptic children between the ages of 2 and 17 years and 2754 healthy children between the ages of 5 and 15 years. In the group of epileptic children, hypopigmented maculae and café-au-lait spots were observed in 30 (14.3%) and 63 (30%) children, respectively. In the group of healthy children, the prevalence of hypopigmented maculae was 1.6% (44 children) and of café-au-lait spots was 2.83% (78 children). The difference between the two groups was very significant statistically ($P < .0001$). (*J Child Neurol* 2002;17:57-59).

Hypopigmented or hyperpigmented skin lesions may coexist with some central nervous system disorders such as tuberous sclerosis and neurofibromatosis. Symptoms related to the central nervous system are significant in such neurocutaneous disorders, and the presence of hypopigmented and hyperpigmented spots is crucial in the diagnosis of these disorders.¹⁻³ Our study has two interconnected objectives. First, we aimed to determine the prevalence of

hypopigmented maculae and café-au-lait spots in idiopathic epileptic children similar to the copresence of skin and central nervous system lesions in many neurocutaneous syndromes. Second, we attempted to compare the results with those of healthy children.

Patients and Methods

A total of 210 patients, referred to Hacettepe University Children's Hospital's Department of Pediatric Neurology, were diagnosed as having idiopathic epilepsy according to the classification of the International League Against Epilepsy. Patients with epilepsy of organic and metabolic origin and a history of hypoxic-ischemic birth were excluded. To detect the cause of the epilepsy, cranial computed tomography scans or magnetic resonance images, serum glucose, calcium, phosphorus, alkaline phosphatase, sodium, potassium, magnesium, and urine-blood amino acids were examined in all patients. Patients were examined by a pediatric neurologist completely naked under daylight, including the genital region, palms of the hands, and soles of the feet. As well, 2754 healthy children selected randomly from five primary schools in the province of Malatya were examined by a dermatologist under daylight. Patients who had a history of skin inflammation, burn scars, pityriasis alba, tinea versicolor, and nevus anemicus on physical examination and epileptic children were excluded from the study.⁴ The number, location, and diameter of the lesions both in epileptic and healthy children who had hypopigmented and café-au-lait spots were recorded. The results obtained were evaluated statistically by chi-square test.

Results

The prevalence of hypopigmented maculae and café-au-lait spots was investigated in a total of 210 epileptic children (99 girls and 111 boys) between the ages of 2 and 17 years and in 2754 healthy children (1338 girls and 1416 boys) between the ages of 5 and 15 years. The hypopigmented maculae were polygonal, ash leaf, and fingerprint shape. Café-au-lait spots were discrete, round or oval, uniformly hyperpigmented skin patches. Their color varied from light to dark brown, and the borders were generally smooth and rarely irregular. Those lesions were classified according to the number, location, and diameter (Tables 1 to 3). In epileptic children, the prevalence of hypopigmented maculae was 14.3% (30 children) and of café-au-lait spots was 30% (63 children). In healthy children, the prevalence of hypopigmented maculae was found as 1.6% (44 children) and of café-au-lait spots as 2.83% (78 children).

It was found that $\chi^2 = 123.88$ and $P < .0001$ for hypopigmented maculae and $\chi^2 = 311.89$ and $P < .0001$ for café-au-lait spots. The difference between the two groups was very significant statistically.

Discussion

Since both the central nervous system and skin have an ectodermal origin embryologically, they can disclose common manifestations in the course of some diseases. This condition is seen

Table 1. Locations of Hypopigmented Maculae and Café-au-lait Spots in Healthy Group and Epileptic Patients

Location	Hypopigmented Maculae				Café-au-lait Spots			
	Healthy Group n	%	Epileptic Group n	%	Healthy Group n	%	Epileptic Group n	%
Head and neck	12	17.4	9	17.6	10	6.5	7	6.8
Trunk	33	47.8	28	54.9	114	74	58	56.3
Arms	22	31.9	8	15.7	11	7.1	23	22.3
Legs	2	2.9	6	11.8	19	12.4	15	14.6
Total	69	100	51	100	154	100	103	100