

Hemiplegic Migraine With Prolonged Symptoms: Case Report

ABSTRACT

Hemiplegic migraine is defined by the occurrence of migraine during attacks of unilateral weakness. Neurologic symptoms last for 15 to 60 minutes in most cases. Attacks usually start in childhood, adolescence, or early adulthood. Diagnosis may be delayed if there is no relevant family history. A 16-year-old girl who was diagnosed with hemiplegic migraine presenting with prolonged left hemiparesis is reported. The importance of this case is that the pediatrician will also consider migraine in the differential diagnosis of a child presenting with hemiparesis even if there is no previous headache and family history. (*J Child Neurol* 2002;17:80–81).

Hemiplegic migraine is characterized by acute episodes of hemiplegia, hemisensory deficits, and other neurologic abnormalities occurring before or together with headache, nausea, and vomiting.¹ The frequency of hemisindrome in children is not known exactly. In some series, the hemisindrome was confined to the aura in about 30% of the cases, and in the remainder it could persist beyond the aura or develop during the headache phase. The hemisindrome of the aura rarely lasts more than 1 hour and is usually 5 to 15 minutes in duration. Type I hemisindrome is brief and confined to the aura, and type II hemisindrome develops during the headache phase and is prolonged.^{2,3} In this report, we defined a case with type II hemiplegic migraine whose hemisindrome was prolonged and whose weakness persisted over a period of 6 days. We used magnetic resonance imaging (MRI) techniques for the differential diagnosis.

Case Report

A 16-year-old girl was referred to the hospital with the first headache attack with weakness and numbness on her left side. Her weakness lasted for about 8 hours and was followed by spontaneous improvement. Headache and hemiparesis began at the same time, and she had visual symptoms before headache. Her past history revealed no headache attacks. In her family history, her mother had common migraine. Her MRI and electroencephalography were normal. She was diagnosed as having migraine with aura, and a calcium-channel blocker (flunarizine) was started. After hospital discharge, she had headache attacks one or two times per month and was treated with nonsteroidal anti-inflammatory drugs. Five months later, she was referred to our hospital again with left hemiparesis and headache. Her headache and hemiparesis started at the same time. At admission, she had headache and left hemiparesis for 5 hours. For the exclusion of cerebral infarct, diffusion MRI was obtained immediately and was normal (Figure 1). She was evaluated for risk factors. Her routine hemogram revealed iron deficiency anemia. The electrolytes, lipid profile, lipoprotein a, lactate, pyruvate levels, coagulation tests (prothrombin time, partial thromboplastin time, thrombin time, fibrinogen, antithrombin III, protein S, protein C, activated protein C resistance, factor V Leiden), and autoantibodies (antinuclear antibodies, anti-double-stranded DNA, anticardiolipin) were normal. On the fourth day of hospitalization, hemiparesis continued. Her fluid-attenuated inversion-recovery magnetic resonance sequences and magnetic resonance angiography were obtained and were normal (Figures 2 and 3). Her weakness persisted, with improvement over a period of 6 days. She started to walk with support on the sixth day. She was treated with calcium-channel blockers (flunarizine 10 mg/day), nonsteroidal anti-inflammatory drugs, and low-

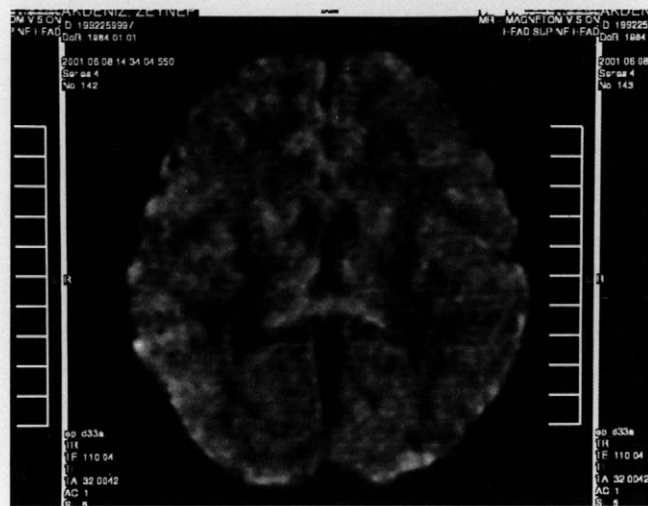


Figure 1. Axial diffusion image of the case identified no infarction at the sixth hour.

dose (80 mg/day) salicylate. She was diagnosed with hemiplegic migraine type II and was discharged with flunarizine and salicylate prophylaxis.

Discussion

Our case had left hemiplegia occurring at the same time with headache attack. Headache was localized in the occipital region.

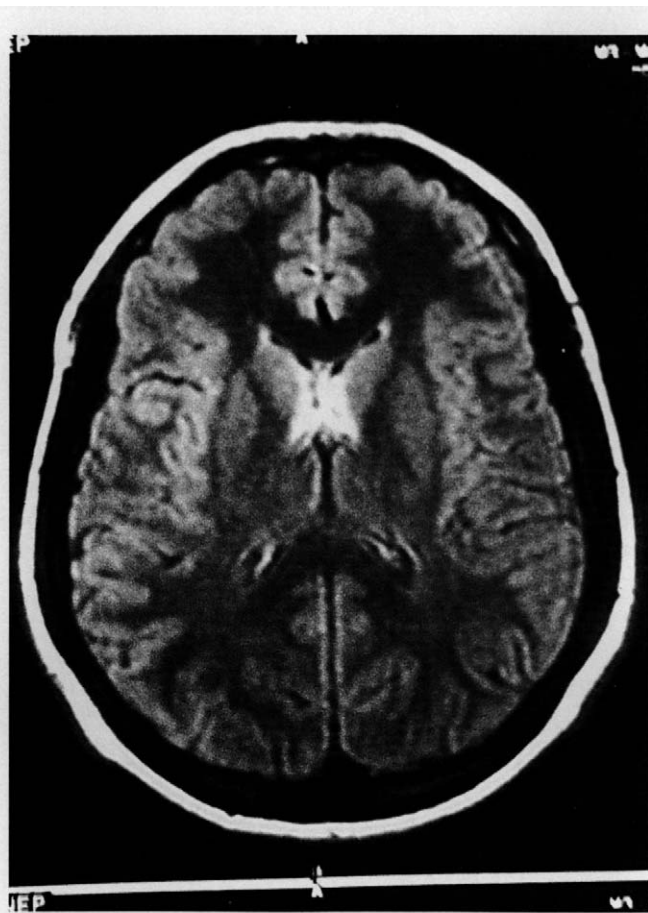

Figure 2. Axial fluid-attenuated inversion-recovery (FLAIR) image was normal on the fourth day.

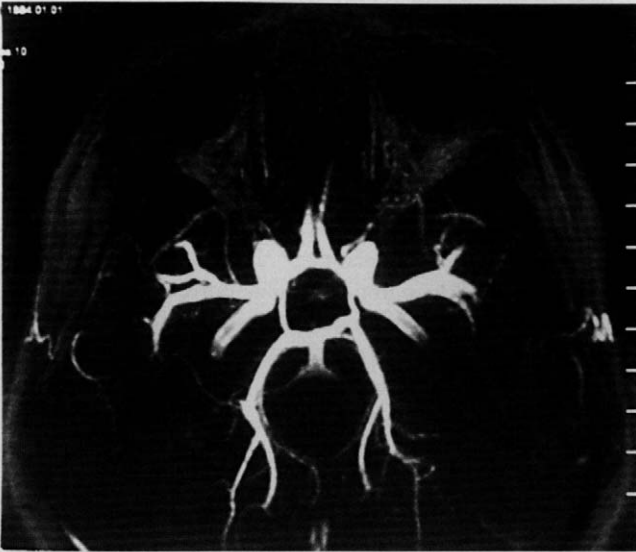

Figure 3. Magnetic resonance angiography of the case was normal.

In almost 60% of cases with hemiplegic migraine, symptoms last less than 1 hour, but there are also cases reported in whom hemisyn-drome symptoms persisted for more than 5 days.² Familial hemiplegic migraine has an autosomal dominant inheritance, and it has recently been reported that the gene locus was on chromosome 19.⁴⁻⁶ The mother of our case had common migraine, but she did not have a family history of hemiplegic migraine.

The condition is relatively common in adolescent patients, but Rajput and Kramer⁷ reported a 75-year-old man who presented with multiple episodes of reversible hemiplegia followed by headache. This case had seven members in his family with the same clinic.

In hemiplegic migraine, neuroimaging is usually normal, but sometimes the aura including hemiparesis may be prolonged, and severe attacks may be associated with confusion or coma. Hayashi et al⁸ reported a case whose aura was prolonged and resulted in irreversible brain damage. Prolonged neurologic abnormalities were also present in our case, but the diffusion MRI was normal at the sixth hour. Ebinger et al⁹ reported two cases with migraine-associated cerebral infarction. They discussed whether ischemic stroke was a coincidence or a causal relation. On MRI, the best way to identify infarctions in the hyperacute phase is the use of diffusion imaging, which shows reduced diffusion of water protons within minutes of the infarction. Diffusion imaging can demonstrate the location of acute infarction as early as 1 hour after clinical detection of the stroke in children, so it is reported that diffusion images should be obtained in children with an acute onset of unexplained neurologic deficits.¹⁰ In our case, diffusion MRI obtained within 6 hours indicated no infarction. We also obtained fluid-attenuated inversion-recovery sequences and magnetic resonance angiogra-

phy for differential diagnosis during the late phase. Early and late radiologic evaluation excluded ischemic stroke. As a result, the importance of this case is that the pediatrician must also consider migraine in the differential diagnosis of a child presenting with reversible neurologic symptoms even though she had no previous diagnosis of migraine.

Gül Serdaroğlu, MD

Sarenur Tütüncüoğlu, MD

Department of Pediatrics

Division of Child Neurology

Ege University Faculty of Medicine

Cem Çallı, MD

Department of Radiology

Ege University Faculty of Medicine

İzmir, Turkey

Berrak Sarioğlu, MD

Harun Korkmaz, MD

Department of Pediatrics

Division of Child Neurology

Ege University Faculty of Medicine

İzmir, Turkey

Received August 23, 2001. Accepted for publication Nov 1, 2001.

The first three authors contributed equally to this work. The others were mentors.

Address correspondence to Dr Gul Serdaroğlu, 1374 Sk. No: 26, C Blok, D: 15 .35210, Alsancak, İzmir, Turkey. Tel: +90 232 489 75 40; +90 542 417 10 56; fax: +90 232 342 69 90; e-mail: gul.s@turk.net.

References

1. Livne A, Lahat E: Familial hemiplegic migraine of childhood. *Harefuah* 1999;137:101-104, 175.
2. Barlow CF: *Headaches and Migraine in Childhood*, 1st ed. Philadelphia, JB Lippincott, 1984.
3. Geraud G: Rare and atypical forms of migraine. *Rev Neurol (Paris)* 2000; 156(Suppl 4):S42-S46.
4. Ophoff RA, van Eijk R, Sandkuijl LA, et al: Genetic heterogeneity of familial hemiplegic migraine. *Genomics* 1994;22:21-26.
5. Nyholt DR, Lea RA, Goadsby PJ, et al: Familial typical migraine: linkage to chromosome 19p13 and evidence for genetic heterogeneity. *Neurology* 1998;50:1428-1432.
6. Terwindt GM, Ophoff RA, van Eijk R, et al: Involvement of the CACNA1A gene containing region on 19p13 in migraine with and without aura. *Neurology* 2001;56:1028-1032.
7. Rajput V, Kramer ED: Adult onset familial hemiplegic migraine. *Headache* 1995;35:423-427.
8. Hayashi R, Tachikawa H, Watanabe R, et al: Familial hemiplegic migraine with irreversible brain damage. *Intern Med* 1998;37:166-168.
9. Ebinger F, Boor R, Gawehn J, Reitter B: Ischemic stroke and migraine in childhood: Coincidence or causal relation? *J Child Neurol* 1999;14: 451-455.
10. Sorensen AG, Buonanno FS, Gonzalez RG, et al: Hyperacute stroke: Evaluation with combined multisection diffusion-weighted and hemodynamically weighted echo-planar MR imaging. *Radiology* 1996;199: 391-401.