

Stroke following Chiropractic Manipulation

Report of 3 Cases and Review of the Literature

Joseph S. Jeret^a Mark Bluth^b

Departments of ^aNeurology and ^bRadiology, Mercy Medical Center, Rockville Centre, N.Y., USA

Key Words

Chiropractic manipulation · Internal carotid artery dissection · Stroke · Vertebral artery dissection

Abstract

We present 3 cases of stroke due to arterial dissection following chiropractic manipulation: (1) a 31-year-old woman with left vertebral dissection developed a large cerebellar infarct, (2) a 64-year-old man developed a left parietal infarct due to left carotid dissection and (3) a 51-year-old man developed right Horner's syndrome, fluctuating dysarthria, left facial droop, and left arm weakness due to right carotid dissection. Imaging studies and the literature are reviewed.

Copyright © 2002 S. Karger AG, Basel

Introduction

Stroke temporally related to cervical spine manipulation has been described. Cervical arterial dissection may occur after chiropractic manipulation and other forms of neck trauma [1–6]. Sometimes, the trauma is quite trivial [7, 8]. Due to encasement in bone, the vertebral arteries

are most frequently involved [9, 10]. On rare occasions, there may be bilateral vertebral dissection [11] or dissection of one carotid and one vertebral [12]. Spontaneous and traumatic cervical arterial dissections occur with equal frequency [13]. The annual incidence of spontaneous dissection per 100,000 is estimated at 2.5–3 for carotid dissection and 1–1.5 for vertebral dissection [14]. Chiropractic neck manipulation may be the most frequent cause of traumatic vertebral dissection [5]. A recent case-controlled study showed an association between vertebrobasilar stroke and spinal manipulation in young adults [15].

Although there are many published reports of posterior circulation stroke after cervical manipulation, reports of manipulation-induced carotid dissection are less common [9, 10, 13, 16–20]. We describe 2 additional cases of manipulation-induced carotid dissection and an additional case of vertebral dissection.

Case Reports

Case 1

A 31-year-old woman with no past medical history and taking only a low-estrogen contraceptive developed severe vertigo, neck pain, and nausea immediately after rapid rotatory chiropractic ma-

KARGER

Fax +41 61 306 12 34
E-Mail karger@karger.ch
www.karger.com

© 2002 S. Karger AG, Basel
1015–9770/02/0133–0210\$18.50/0

Accessible online at:
www.karger.com/journals/ced

Dr. Joseph S. Jeret
119 North Park Avenue (suite 301)
Rockville Centre, NY 11570 (USA)
Tel. +1 516 593 5800, Fax +1 516 593 4752
E-Mail BrainsRus2@aol.com

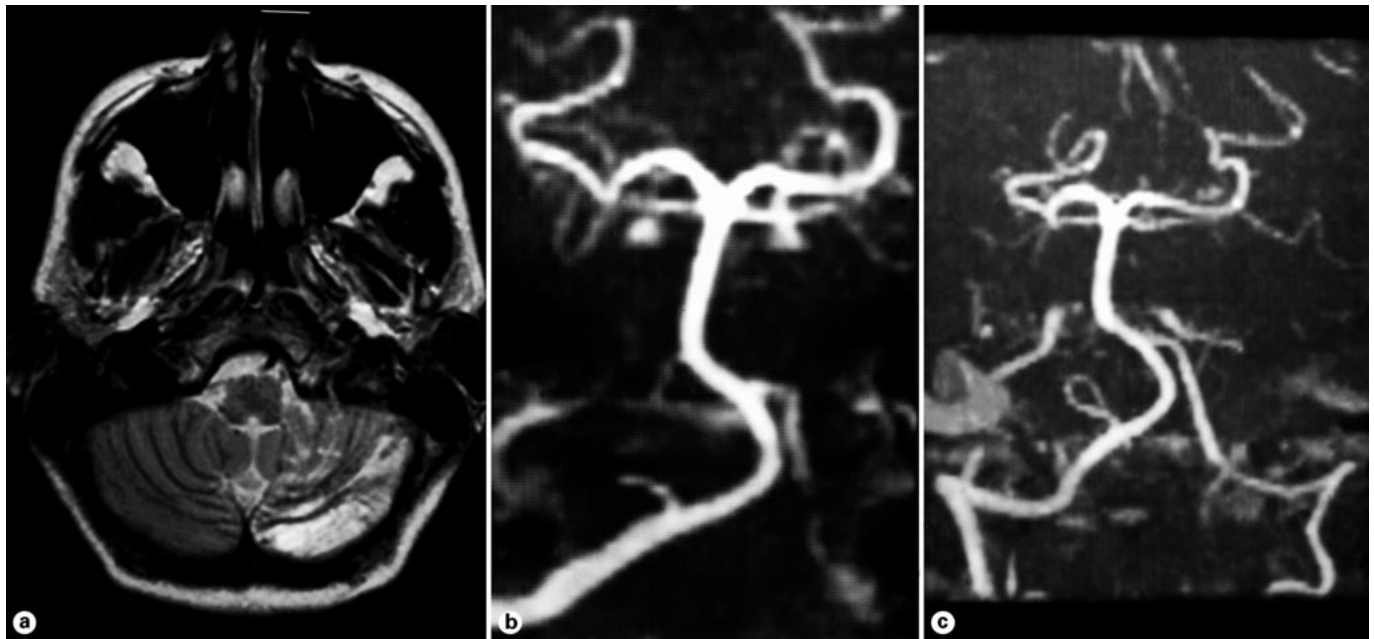


Fig. 1. **a** Posterior fossa intense T₂ signal conforming to left anterior inferior cerebellar and posterior inferior cerebellar arteries' territories consistent with acute infarction. **b** Maximum intensity projection from three-dimensional time-of-flight intracranial MRA showing segmental signal void in left vertebral artery consistent with arterial dissection. **c** Follow-up MRA shows restored flow in the left vertebral artery consistent with recanalization.

nipulation of her neck for mild, chronic, non-radicular neck pain. She was initially seen by one of us (J.S.J.) 2 days later. Her examination showed nuchal rigidity, mild dysarthria, and left-sided dysmetria. MRI confirmed the presence of extensive left cerebellar infarction (in the distributions of the posterior inferior cerebellar and anterior inferior cerebellar arteries) due to left vertebral dissection (fig. 1a, b). She was transferred to a tertiary care hospital, admitted to the neurological intensive care unit, placed on heparin at 1,000 units/h, and observed. She made a full recovery. On follow-up MRI 6 months later, the left anterior inferior cerebellar artery recanalized, a chronic left posterior inferior cerebellar artery infarct was present, and flow was restored in the left vertebral artery (fig. 1c). She had no significant deficit on examination. She was switched to aspirin therapy and has remained asymptomatic for 3 years.

Case 2

A 64-year-old man presented to the hospital 4 days after 'gentle' manipulation of his neck by his daughter, a chiropractor. He awoke at 2 a.m. feeling that his right arm was strange and that, in fact, it was not a part of his body. Examination showed a right upper quadrantanopsia, mild right arm > leg weakness, and extinction to double simultaneous stimulation on the right. MRI confirmed the presence of a left parietal stroke (fig. 2a). Carotid duplex sonography on hospital day 2 was negative. MRA of carotids on hospital day 3 showed complete left internal carotid artery (ICA) occlusion (fig. 2b). Subsequent Doppler examinations showed re-established flow through the left carotid. Intermittent carotid occlusion due to presumptive dissection was diagnosed and the patient was placed on warfarin.

Case 3

A 51-year-old man presented to the hospital 5 days after rotatory chiropractic manipulation of his neck. For the prior 2–3 days he had intermittent slurred speech, left facial droop, and mild left hand weakness. Examination by one of us (J.S.J.) demonstrated subtle dysarthria, left facial droop, and mild left distal arm weakness. He was immediately placed on heparin because of fluctuating neurologic deficit. MRI and MRA confirmed the presence of a right subcortical stroke and suggested right ICA occlusion versus slow flow (fig. 3). Catheter angiography confirmed the presence of right ICA dissection without occlusion; he was initiated on warfarin. When he abruptly developed a right Horner's syndrome and increased left hemiparesis 2 weeks later, right ICA occlusion was diagnosed and right external carotid to middle cerebral artery bypass was performed uneventfully. Within 1 month he had made a significant recovery. He has had no recurrence for 8 months on warfarin.

Discussion

Patients with vertebral dissection due to chiropractic manipulation (including our case 1) may have some symptoms almost immediately – typically nausea, vomiting, and headache. Although 82% present within 7 days, delay up to 31 days has been reported [21]. In clinical practice it is imperative to question the patient about traumas in the preceding months.

Fig. 2. **a** Transaxial fast fluid attenuation inversion recovery (FLAIR) sequence demonstrates intense signal abnormality in the left precentral gyrus consistent with acute infarction. **b** Maximum intensity projection from two-dimensional time-of-flight extracranial MRA showing left ICA origin occlusion.

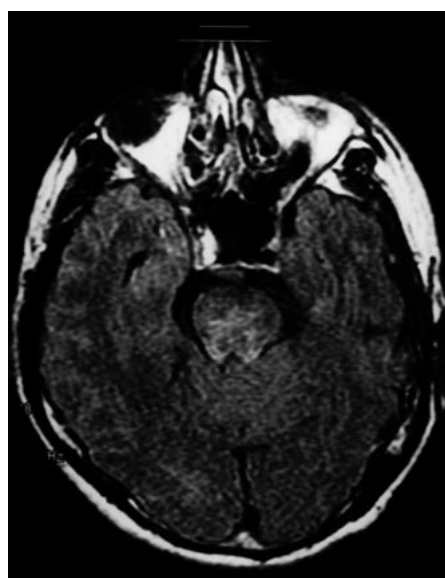
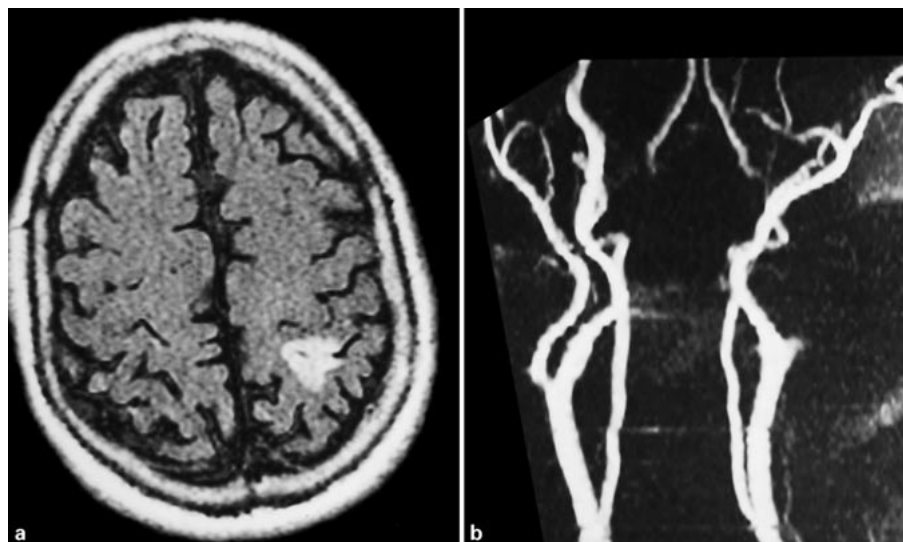


Fig. 3. Transaxial proton density sequence through cavernous sinus demonstrating absent flow void in the right ICA consistent with slow flow, no flow, or intimal hemorrhage.

It has been suggested that chiropractors with superior training may be less prone to cause arterial dissection [22]. However, carotid dissection is felt by some to be unrelated to the force of manipulation [23], thus suggesting that ‘the differentiation between spontaneous and traumatic dissections is artificial because of a continuum between the two forms’ [24]. Nonetheless, one large

review in the chiropractic literature suggested that virtually all cases of stroke are due to rotational manipulation of the upper cervical spine and recommends little or no rotation when treating this area [25].

It has been estimated that 1 in 20,000 spinal manipulations causes a stroke [14, 26]. Generalized connective tissue disorders are found in 25% of these patients [14]. Noninvasive modalities like MRI and MRA are adequate to diagnose arterial dissection [27] and should result in more frequent diagnosis. Since many cases of dissection – regardless of the etiology – remain undiagnosed, it is likely that many cases of chiropractic-induced dissections also go undiagnosed. This is particularly true since this subset of patients often has neck pain at baseline, and the clinician may be fooled by the delay between manipulation and onset of stroke. Greater awareness by neurologists, primary care physicians, patients, osteopaths, and chiropractors may help to ascertain the true incidence of this complication and aid in establishing safety guidelines for cervical spine manipulation. Until then, patients should be warned of the potentially fatal risk prior to treatment.

Acknowledgments

The authors thank Mrs. Carol Reid for her invaluable assistance in unearthing references from the medical and chiropractic literature and Eilleen Grilli (RN) for technical assistance with the reproduction of the images. This paper was presented in part at the 23rd Annual Meeting of the American Society of Neuroimaging (San Juan, Puerto Rico, January 2000).

References

- 1 Cook JW IV, Sanstead JK: Wallenberg's syndrome following self-induced manipulation. *Neurology* 1991;41:1695-1696.
- 2 Rothrock JF, Hesselink JR, Teacher TM: Vertebral artery occlusion and stroke from cervical self-manipulation. *Neurology* 1991;41:1696-1697.
- 3 Sherman DG, Hart RG, Easton JD: Abrupt change in head position and cerebral infarction. *Stroke* 1981;12:2-6.
- 4 Terrett AGJ, Kleynhans AM: Cerebrovascular complications of manipulation; in Haldeman S (ed): *Principles and Practice of Chiropractic*. Norwalk, Appleton & Lange, 1991, pp 579-598.
- 5 Vibert D, Rohr-Le Floch J, Gauthier G: Vertigo as manifestation of vertebral artery dissection after chiropractic manipulations. *ORL* 1993;55:140-142.
- 6 Zak SM, Carmody RF: Cerebellar infarction from chiropractic manipulation. *Ariz Med* 1984;41:333-337.
- 7 Mourad JJ, Girerd X, Safar M: Carotid-artery dissection after a prolonged telephone call (letter). *N Engl J Med* 1997;333:516.
- 8 Pryse-Phillips WP: Infarction of the medulla and cervical cord after fitness exercises. *Stroke* 1989;20:292-294.
- 9 Lee KP, Carlini WG, McCormick GF, Albers GW: Neurologic complications following chiropractic manipulation: A survey of California neurologists. *Neurology* 1995;45:1213-1215.
- 10 Hufnagel A, Hammers A, Schonle P-W, Bohm K-D, Leonhardt G: Stroke following chiropractic manipulation of the spine. *J Neurol* 1999; 246:683-688.
- 11 Soper JR, Parker GD, Hallinan JM: Vertebral artery dissection diagnosed with CT. *AJNR Am J Neuroradiol* 1995;16:952-954.
- 12 Rossetti AO, Combremont PC, Bogousslavsky J: Manipulations cervicales et dissection arterielle. *Schweiz Archiv Neurol Psychiatr* 2000; 151:247-252.
- 13 Biller J, Hingtgen WL, Adams HP, et al: Cervicocephalic arterial dissections: A ten year experience. *Arch Neurol* 1986;43:1234-1238.
- 14 Schievink WI: Spontaneous dissection of the carotid and vertebral arteries. *N Engl J Med* 2001;344:898-906.
- 15 Rothwell DM, Bondy SJ, Williams JI: Chiropractic manipulation and stroke. A population-based case-control study. *Stroke* 2001;32: 1054-1060.
- 16 Beatty RA: Dissecting hematoma of the internal carotid artery following chiropractic cervical manipulation. *J Trauma* 1977;17:248-249.
- 17 Peters M, Bohl J, Thomke F, et al: Dissection of the internal carotid artery after chiropractic manipulation of the neck. *Neurology* 1995;45: 2284-2286.
- 18 Parwar BL, Fawzi AA, Arnold AC, Schwartz SD: Horner's syndrome and dissection of the internal carotid artery after chiropractic manipulation of the neck. *Am J Ophthalmol* 2001; 131:523-524.
- 19 Braune H-J, Munk MHJ, Huffmann G: Hirninfarkt im Stromgebiet der Arteria cerebri media nach Chirotherapie der Halswirbelsäule. *Dtsch Med Wochenschr* 1991;116:1047-1050.
- 20 Rother J, Rautenberg W, Hennerici M: Traumatische Carotidisdissektion nach Chirotherapie. *Dtsch Med Wochenschr* 1991;116:1652-1653.
- 21 Biousse V, D'Anglejan-Chatillon J, Touboul JP, Amarenco P, Boussier MG: Time course of symptoms in extracranial carotid artery dissections. *Stroke* 1995;26:235-239.
- 22 Bohm J: Cervicocephalic artery dissections and chiropractic manipulations (letter). *Lancet* 1993;341:1214.
- 23 Hamann G, Felber S, Haass A, et al: Cervicocephalic artery dissections due to chiropractic manipulations (letter). *Lancet* 1993;341:764-765.
- 24 Leys D, Lucas C, Gobert M, Deklunder G, Pruvo JP: Cervical arterial dissections. *Eur Neurol* 1997;37:3-12.
- 25 Martiensen J, Nilsson N: Cerebrovascular accidents following upper cervical manipulation: The importance of age, gender and technique. *Am J Chiropractic Med* 1989;2:160-163.
- 26 Vickers A, Zollman C: The manipulative therapies: Osteopathy and chiropractic. *BMJ* 1999; 319:1176-1179.
- 27 Mascalchi M, Bianchi MC, Mangiafico S, et al: MRI and MRA angiography of vertebral artery dissection. *Neuroradiology* 1997;39:329-340.