

Dystypia: Isolated Typing Impairment without Aphasia, Apraxia or Visuospatial Impairment

Mika Otsuki^a Yoshiaki Soma^b Shoji Arihiro^a Yoshimasa Watanabe^a
Hiroshi Moriwaki^a Hiroaki Naritomi^a

^aCerebrovascular Division, Department of Internal Medicine, National Cardiovascular Center, Suita, and

^bSoma Neurology Clinic, Niigata, Japan

Key Words

Isolated typing impairment · Dystypia · Left frontal lesion · Frontal agraphia

Abstract

We report a 60-year-old right-handed Japanese man who showed an isolated persistent typing impairment without aphasia, agraphia, apraxia or any other neuropsychological deficit. We coined the term 'dystypia' for this peculiar neuropsychological manifestation. The symptom was caused by an infarction in the left frontal lobe involving the foot of the second frontal convolution and the frontal operculum. The patient's typing impairment was not attributable to a disturbance of the linguistic process, since he had no aphasia or agraphia. The impairment was not attributable to the impairment of the motor execution process either, since he had no apraxia. Thus, his typing impairment was deduced to be based on a disturbance of the intermediate process where the linguistic phonological information is converted into the corresponding performance. We hypothesized that there is a specific process for typing which branches from the motor programming process presented in neurolinguistic models. The foot of the left second frontal convolution and the operculum may play an important role in the manifestation of 'dystypia'.

Copyright © 2002 S. Karger AG, Basel

Introduction

Following the popularization of the word processor or personal computer, typing on a keyboard has become common for many people. According to the neuropsychological model of writing, there are three general processes for writing: the linguistic process, the transition process (graphemic buffer) and the motor execution process [1]. For typing, an additional specific process branching from the writing motor programming process is supposed to be necessary. It is empirically well established that patients with aphasia, agraphia or apraxia show impairment in typing probably because the linguistic or motor execution process is damaged. However, it still remains uncertain whether typing impairment can manifest itself alone without aphasia, agraphia or apraxia, following a focal lesion where the specific typing motor processes are initiated. Boyle and Canter [2] reported a patient who exhibited typing impairment. The patient, however, had multiple lesions and showed mild paraphasia in speech. We here report a patient who developed an isolated typing impairment, not accompanied by aphasia, agraphia, apraxia or any other neuropsychological deficit, following an infarction restricted to the left frontal convexity.

KARGER

Fax +41 61 306 12 34
E-Mail karger@karger.ch
www.karger.com

© 2002 S. Karger AG, Basel
0014-3022/02/0473-0136\$18.50/0

Accessible online at:
www.karger.com/journals/ene

Mika Otsuki
Cerebrovascular Division, Department of Internal Medicine
National Cardiovascular Center
5-7-1, Fujishirodai, Suita, Osaka 565-8565 (Japan)
Tel. +81 6 6833 5012, Fax +81 6 6872 7486, E-Mail miotsuki@hsp.ncvc.go.jp

Case Report

A 60-year-old, right-handed, university-educated business executive exhibited taciturnity at midnight of October 28, 1998, and was admitted to our hospital the next morning. The patient had been in good health until the admission, although he had hypertension, which had been well controlled during the last few years. On admission, neurological examinations revealed an alert and well-oriented man without abnormalities in the cranial nerves, motor system, sensory system and coordination.

Neuroradiological Examination

Computed tomography, performed on the day of admission, and magnetic resonance imaging (MRI), performed 35 days after onset, demonstrated an infarction in the left frontal lobe, which involved the foot of the second frontal convolution and frontal operculum expanding anteriorly to the margin of the ascending branch of the lateral sulcus and posteriorly to the foot of the precentral gyrus (fig. 1). Single photon emission computed tomography using ^{99m}Tc -hexamethylpropylene amine oxime 2 days after onset displayed flow reduction in the areas of infarction, indicating that there was no other lesion than the one revealed by MRI.

Neuropsychological Assessments

On the day of admission, the patient spoke sparsely, but his speech was well articulated without dysarthria or anarthria. He had difficulty in naming objects, failing in 2 of 5 instances, but this was not accompanied by paraphasia. He also showed difficulty in writing kana (syllabogram) but not in writing kanji (morphogram). His naming ability recovered completely over the following 2 days, and his writing difficulty improved over the following 10 days. The results of the assessments are summarized in table 1. The results of the Token Test and the Western Aphasia Battery [3] (Japanese version [4]) showed no aphasia or agraphia. Results of the revised Wechsler Adult Intelligence Scale and Raven Colored Progressive Matrices were within the normal range indicating that he had no impairment in general intelligence. The patient showed no memory impairment in his daily hospital life. Results of the revised Wechsler Memory Scale and Benton's Visual Retention Test were also within the normal range. He was, however, able to recall only 5 auditory number digits on the Digit Forward Task performed 20 days after onset. The re-examination 41 days after onset disclosed no improvements, indicating that the patient had a mild but persistent impairment in short-term memory (STM). His spatial STM was intact because his visual spatial memory span was 7 points 20 days after onset.

The patient had no abnormality in praxis, showing an excellent capability in imitating, pantomiming and using tools with either hand. He was able to point to objects accurately and rapidly with either hand following verbal commands, indicating no slowness in reaction. He could perform a fist-palm-alternating task swiftly. He showed no interhemispheric motor disconnection symptoms such as left-sided apraxia, alien hand sign or intermanual conflict. He showed no orofacial apraxia, visuospatial disturbance, unilateral spatial neglect or visual agnosia.

Thus, he had no aphasia, agraphia, agnosia, apraxia, general intelligence deterioration or memory impairment, except for mild auditory STM impairment.

Prior to the stroke, the patient was skilled at typing and preferred it to writing by hand in business and private communications. He did not adopt the blind-touch typing technique. Yet, the speed of his typ-

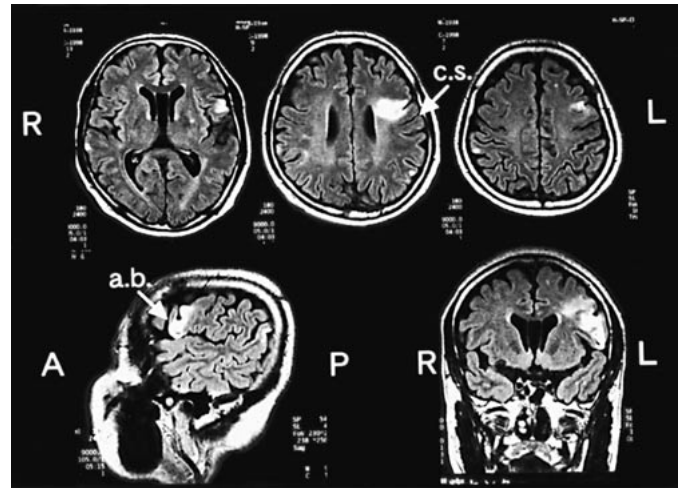


Fig. 1. Fluid-attenuated inversion recovery images of the brain MRI of the patient. Top: axial images. Bottom: sagittal image on the left, coronal image on the right. c.s. = Central sulcus; a.b. = ascending branch of the lateral sulcus.

ing was twice as fast as that of writing by hand, and accuracy was high as asserted by his family. He had been able to type about 800 Japanese characters (in kana and kanji mixed sentences) within 5 min. The next day after admission, the patient realized that he was having difficulty in typing, when he began to use his personal computer, although he had no difficulty in operating the keyboard. When the patient attempted to improve his accuracy, his typing speed became extraordinarily slow.

Here, we should briefly explain the Japanese writing system and typing methods.

There are two writing systems in the Japanese language: kanji (morphogram) and kana (syllabogram). The minimum unit of Japanese oral sounds is called mora, and there are 46 kana characters which represent all the mora. First, we should point out that Japanese kana writing does not demand the knowledge of so-called spelling because it is accomplished by just writing kana representing exactly the mora with just a few exceptions. Thus, there is no possibility to show any spelling impairment in kana writing if one could write kana characters letter by letter according to the mora, as reported in western patients.

The most popular way of typing Japanese is called 'alphabetical input', which was used by the patient. In this method, a western-style keyboard is used, and the kana character 'ka' is produced by typing 'k' followed by 'a'. The monitor then shows the kana. If Japanese is then expressed in the alphabet, 39 of 46 kana are described as pairs of two alphabetical letters, one a consonant and the other a vowel. Six other kana characters are described as single vowels, and the remaining kana character is described as a single consonant. To enter kanji characters, the same procedure is followed by an additional key-push to turn kana words into kanji. To type the kanji character read 'yama' (meaning mountain), 'y', 'a', 'm', 'a' are typed in order. There are also many homonyms in kanji, which are displayed for the typist to select.

Table 1. Results of neuropsychological assessments**a** Tests

Token Test [1 d.a.o.]	96%
WAB [10 d.a.o.]	
Spontaneous speech	
Information content (10)	9
Fluency (10)	9
Comprehension: auditory word recognition (60)	60
Repetition (100)	100
Naming: object naming (60)	60
Reading (10)	10
Writing (10)	9.7
Praxis (60)	60
Drawing (30)	30
Block design (9)	9
Calculation (24)	24
Raven's score (37)	31
WAIS-R [18 d.a.o.]: PIQ	
	113
WMS-R [16 d.a.o.]	
Verbal memory IS	95
Visual memory IS	106
General memory IS	98
Attention/concentration IS	85
Delayed recall IS	95
Benton's visual retention test [16 d.a.o.] (10)	7
Auditory digit span (forward)	
20 d.a.o.	5
41 d.a.o.	5
Visual memory span (forward)	
20 d.a.o.	7
41 d.a.o.	7

b Assessment of writing and typing [37 d.a.o.]

	Typing		Writing	
	m.f.s.	m.l.m.	m.f.s.	m.l.m.
Total time required, s	705		551	
Total errors (of 358 kana), n	34		16	
Time required, s	310	395	204	347
Errors (of 179 kana), n	22	12	11	5
Types of errors, n				
Phonological	19	10	7	2
Spatial	1	1	–	–
Others	2	1	4	3

d.a.o. = Days after onset (administration day); WAB = Western Aphasia Battery; WAIS-R = revised Wechsler Adult Intelligence Scale; PIQ = Performance Intelligence Quotient; WMS-R = revised Wechsler Memory Scale; IS = index score; m.f.s. = meaningful sentences (words); m.l.m. = meaningless mora sounds (nonwords). Figures in parentheses indicate optimal scores.

We statistically compared the number of errors in typing and writing, using a two-by-two contingency table (testing the null hypothesis). It revealed that the number of typing errors was significantly high ($\chi^2 = 6.966 > \chi^2(0.05) = 3.841$). Comparison of the performance between the words and the non-words revealed no significant difference [in typing, $\chi^2 = 3.250 > \chi^2(0.05) = 3.841$; in writing $\chi^2 = 2.355 > \chi^2(0.05) = 3.841$].

If the typist has an impairment in typing kana, an impairment in kanji is inevitable, since kanji typing can only be produced on the basis of correct kana typing.

Assessment of Typing and Writing

To assess the patient's ability of typing and writing, we dictated sentences, adapted from folk story (words) and meaningless mora sounds (nonwords), both of which consisted of 179 kana characters. The patient was required to accomplish two tasks: typing and writing the same materials ($179 \times 2 = 358$ kana). The order of the dictation of the sentences and the meaningless mora sounds as well as the order of typing and handwriting were counterbalanced (ABBA for example). We masked the monitor of the personal computer and instructed the patient not to be worried about the errors and continue typing until the end, in order to estimate his typing ability accurately. The times required for typing and writing as well as the number of errors and error patterns were analyzed.

The patient exhibited skillful and rapid digital movements in typing, although his speed slowed occasionally. He typed using the fin-

gers of both hands equally as we did not indicate which hand to use to assess his natural and spontaneous typing ability. His writing performance appeared normal. The total time required for typing was 705 s, whereas that for handwriting was 551 s. The numbers of errors were 34 in typing and 16 in writing, which was statistically significant (table 1), and his typing speed was revealed to be much slower than that of his premorbid performance (800 characters typed within 5 min). It is uncertain whether his writing speed had become slower or the accuracy lower, because there was no evidence of his premorbid writing ability; however, the patient felt no difference between his writing abilities before and after the stroke. He was able to produce the sentences (words) faster than the meaningless mora sounds (nonwords) in both typing and writing. Error numbers, however, were higher in the sentences than the meaningless mora sounds. There was no statistically significant difference in performance between the words and the nonwords both in typing and writing. It might indicate that the patient had a tendency to perform faster, but more carelessly, when producing the sentences in both typing and writing. We classified the errors into three main categories: spatial

error, phonological error and others. On the keyboard, each key has 3–6 neighbor keys, and *spatial error* is caused by pushing the wrong key adjacent to the target key, such as 's' instead of 'a'. *Phonological errors* include the mistyping of both consonants and vowels, consonants alone and vowels alone, which cannot be attributed to the spatial errors in typing. In writing, phonological errors infer writing a different kana from the target one. *Others* include all errors, which cannot be classified into the former two types, such as preservation and omission. The analysis of error patterns indicated that the majority of errors were phonological, representing paragrammia in particular in typing. The patient did not commit junction order errors in kana characters consisting of a pair of consonant and vowel, such as mistyping vowel-consonant, consonant-consonant or vowel-vowel instead of consonant-vowel; he always followed the junction order rule. Such a correct conjunction order and few spatial errors suggest that his phonological regulation ability in the linguistic process and the motor execution control ability according to the linguistic order were both maintained intact. He did not have any special rehabilitation and returned to his work 1 month after the onset. From the beginning of his return, he felt no deterioration in his business ability including writing; however, he felt a decline of his typing ability. The same dictation examinations of typing and writing performed 6 months after onset revealed no improvement of error percentages, required time and error patterns. The patient still complained of typing difficulty 1 year after onset.

Discussion

The patient exhibited an isolated persistent typing impairment without aphasia, agraphia, apraxia, visuospatial impairment, memory disturbance or general intelligence deterioration. It is not always useful to compare the error percentage in typing with writing, or the time required for dictation, since the premorbid ability of typing and writing varies largely in individuals. Our patient, however, had an excellent typing ability (typing 800 characters within 5 min), which had been much faster than handwriting prior to stroke. Taking 705 s to type 358 kana characters was regarded as a typing impairment in this patient. It seems extraordinarily slow if one typed 358 kana in 705 s for business use.

The patient showed transient kana writing impairment for the first 10 days after onset. Pure agraphia [1] is reported to be caused by left frontal lesions [5–15]. Most Japanese patients with pure agraphia due to a frontal lesion were reported to have kana-dominant or kana-specific writing impairment [8–10, 13,14]. They most commonly make kana errors such as paragrammia and rarely show ill-shaped kana characters. These findings are in accordance with those of our patient in the early days. Regarding the relationship between agraphia and typing impairment, however, there have been no descriptions about typing ability in all these reports of agraphic

patients. Agraphia may cause typing impairment; however, our patient showed persistent typing impairment after the recovery from transient writing impairment (just for 10 days), and typing impairment was much severer than that of writing impairment from the beginning of the stroke onset. Thus, we deduced that the typing impairment of our patient could not be attributable to agraphia and that it is a specific impairment. Our patient also showed mild auditory STM disturbance. Although we cannot deny the relevance of mild auditory STM disturbance to typing impairment because typing performance may require STM ability, not all patients with mild STM disturbance show typing impairment. Thus, we deduced that mild STM impairment could not necessarily play a main role in the typing impairment of our patient.

Although some models of writing and spelling have been presented in the neurolinguistic literature [1], we cannot indicate the level of impairment of our patient in the presented model of writing and spelling [1]. The typing difficulty in our patient was not based on an impairment of the linguistic process, since he had no aphasia or agraphia. And the spelling impairment cannot be due to Japanese writing characteristics. The fact that the patient showed few spatial errors such as mistyping neighboring keys and that he showed no impairment of praxis and excellent digital movements indicated that his typing impairment was not simply attributable to a general praxis disorder. Being able to keep the correct regulation of the phonological order suggests that his motor execution could follow the linguistic regulation, and it also indicates that his motor execution ability was intact.

We hypothesize that there is a process where the linguistic phonological information is converted into the corresponding performance, including motor programming and conditioning, to realize a specific motor execution such as typing while retaining the linguistic information. Therefore, we speculated that typing impairment could be specifically manifested alone due to an impairment of this intermediate process between the linguistic process and the acquired typing execution process. We deduce that there is a specific process for typing, which branches from the motor programming process, before proceeding to the writing process according to the neurolinguistic model of Roeltgen [1].

We consider that the foot of the left second frontal convolution and the operculum may play an important role in transforming phonological information into different modalities to achieve performance and that its damage may cause a specific impairment such as typing disturbance. The frontal lesions causing agraphia [5, 9, 11, 13–

15] were reported to be in the foot of the second convolution or the precentral gyrus, which is similar to that of our patient. The specificity of our patient's lesion was that it was located in the lower second frontal convolution and that it reached to the bottom of the operculum.

Acknowledgements

We wish to thank Dr. Y. Nakagawa, Ehime University, for valuable comments and discussions.

References

- 1 Roeltgen DP: Agraphia; in Heilman KM, Valenstein E (eds): *Clinical Neuropsychology*, ed 3. New York, Oxford University Press, 1993, pp 63–89.
- 2 Boyle M, Canter GJ: Neuropsychological analysis of a typewriting disturbance following cerebral damage. *Brain Lang* 1987;30:147–164.
- 3 Kertesz A: *The Western Aphasia Battery*. New York, Grune & Stratton, 1982.
- 4 Sugishita M: *The Western Aphasia Battery (Japanese edition)*. Tokyo, Igakushoin, 1986.
- 5 Exner S: *Untersuchungen über die Lokalisation der Funktionen in der Grosshirnrinde des Menschen*. Wien, Braumüller, 1881.
- 6 Gordinier HC: A case of brain tumor at the base of the second frontal convolution, with autopsy: The only positive localizing symptom was agraphia uncombined with any form of aphasia. *Am J Med Sci* 1899;117:526–535.
- 7 Aimard G, Devic M, Lebel M, Trouillas P, Boisson D: Agraphie pure (dynamique?) d'origine frontale: à propos d'une observation. *Rev Neurol* 1975;131:505–512.
- 8 Yashima Y, Ishige K, Nakanishi S, Kumashiro H: Speech arrest and 'pure' agraphia (Japanese with English abstract). *Brain Nerve* 1980;32:1039–1045.
- 9 Sato M, Yasui N, Suzuki A, Kawamura S, Sayama I, Kobayashi T: Agraphia from the frontal lesion: A case of moyamoya disease (Japanese with English abstract). *Brain Nerve* 1983;35:1145–1151.
- 10 Tsuzuki S, Indo T: 'Pure' agraphia following left frontotemporal lobe infarction (Japanese with English abstract). *Shinkeinaika* 1986;25:160–165.
- 11 Rapsak SZ, Artur SA, Rubens AB: Lexical agraphia from focal lesion of the left precentral gyrus. *Neurology* 1988;38:1119–1123.
- 12 Hodges J: Pure apraxic agraphia with recovery after drainage of a left frontal cyst. *Cortex* 1991;27:469–473.
- 13 Abe K, Yokoyama R, Torifuji S, Yanagihara T: A jargon agraphia and selective agraphia of kana resulting from an infarct in the left middle frontal gyrus (Japanese with English abstract). *Jpn J Neuropsychol* 1993;9:196–201.
- 14 Thogi H, Saitoh K, Takahashi S, Takahashi H, Utsugisawa K, Yonezawa H, Hatano K, Sasaki T: Agraphia and acalculia after a left prefrontal (F1, F2) infarction. *J Neurol Neurosurg Psychiatry* 1995;58:629–632.
- 15 Sakurai Y, Matsumura K, Iwatsubo T, Momose T: Frontal pure agraphia for kanji or kana. *Neurology* 1997;49:946–952.

Copyright: S. Karger AG, Basel 2002. Reproduced with the permission of S. Karger AG, Basel. Further reproduction or distribution (electronic or otherwise) is prohibited without permission from the copyright holder.

Copyright: S. Karger AG, Basel 2002. Reproduced with the permission of S. Karger AG, Basel. Further reproduction or distribution (electronic or otherwise) is prohibited without permission from the copyright holder.