

Primary brain abscess with *Nocardia farcinica* in an immunocompetent patient

Lisa Malincarne ^{a,*}, Massimo Marroni ^a, Claudio Farina ^b, Guido Camanni ^a,
Marina Valente ^a, Barbara Belfiori ^a, Stefano Fiorucci ^c, Piero Floridi ^d,
Angela Cardaccia ^a, Giuliano Stagni ^a

^a Department of Experimental Medicine and Biochemical Science, Section of Infectious Diseases, University of Perugia, Perugia, Italy

^b Microbiology Institute, Azienda Ospedaliera “Ospedali Riuniti di Bergamo” Bergamo, Italy

^c Neurosurgery, Azienda Ospedaliera, Perugia, Italy

^d Neuroradiology, Azienda Ospedaliera, Perugia, Italy

Received 31 October 2001; accepted 19 December 2001

Abstract

In this paper, we describe a case of an immunocompetent patient with cerebral nocardiosis. The onset was with loss of strength, paresthesia and focal epilepsy of the left arm. MRI showed on T2-weighted sequences a hyperintense central area of pus surrounded by a well-defined hypointense capsule and surrounding edema; on T1-weighted sequences a hypointense necrotic cavity with ring enhancement following administration of intravenous gadolinium. The patient underwent surgical excision of the abscess but culture from the specimen was negative. After 40 days of empirical antimicrobial therapy he developed neurological deterioration with focal epilepsy. A new MRI documented an enlargement of the hypointense lesion in the right frontal-parietal region. A second craniotomy with drainage of the abscess was performed; cultures yielded *Nocardia farcinica*. Therapy with trimethoprim/sulfamethoxazole, amikacin and meropenem was given for 35 days, and clinical and radiological improvement was observed. Home therapy was done with oral trimethoprim/sulfamethoxazole. Currently, 5 months from the second surgery, the patient can walk with support and no new episodes of epilepsy occurred. Side effects were absent from therapy. The MRI appearance of the brain lesion has improved, with a decrease in size, surrounding edema and ring enhancement. © 2002 Elsevier Science B.V. All rights reserved.

Keywords: Multiloculated brain abscess; *Nocardia*; Immunocompetent; Surgical drainage; Antimicrobial therapy

1. Introduction

Nocardia spp. cerebral abscesses are rare, accounting for approximately 1–2% of all cerebral abscesses [1] and may occur as an isolated central nervous system lesion without evidence of extracranial disease or as part of a ‘disseminated’ infection in association with pulmonary or cutaneous diseases [2,3]. Central nervous system involvement has been recognized in over 44% of all cases of systemic nocardiosis in one large survey [3]. Although cerebral nocardiosis is frequently seen in patients with defects in cell-mediated immunity, more than 50% of patients have no apparent predisposing

risk factor [4]. Insidious manifestations are often misinterpreted as a clue for neoplasia because of the paucity of clinical and laboratory signs of bacterial inflammation, and silent invasion and persistence make diagnosis and management more difficult [3,4]. Clinical manifestations of central nervous system nocardiosis usually result from local effects of granulomas or abscess in the brain and, less commonly, in the spinal cord or meninges [6–8]. The clinical syndromic approach is most accurate when combining the rapidity of clinical presentation coupled with the neurological symptomatology and with defect in host defenses. Prompt aggressive surgical treatment involving craniotomy and excision of these lesions has been advocated by many authors because these lesions have

* Corresponding author.

significantly higher morbidity and mortality rates than do most other cerebral abscesses.

Although the mortality rate for nocardial brain abscess has dropped almost by 50% since the advent of computed tomography (CT), it has remained virtually unchanged in immunocompromised patients and remains three times higher than that of other bacterial brain abscess (30% vs 10%) [5]. Presented here is a non immunocompromised patient with multiloculated brain abscesses.

2. Case report

A 62-year-old man, with hypertension, presented with a 5 days history of loss of strength and paresthesia in his left arm. Physical examination was unremarkable and the neurological evaluation showed hemiparesis in the left side. The white blood cell count was 14,000/ μ l with a differential of 75% neutrophils, 21% lymphocytes, 4% monocytes. Blood sugar level was normal, serologic test for HIV was negative and there was not evidence of deficit of CD4 cells, complement and immunoglobulins. Chest x-ray was clear and the abdominal ultrasound did not reveal any focus of infection. A contrast-enhanced CT scan of the brain revealed an enhancing hypodense lesion with surrounding edema and compression of the ventricular system in the right frontal-parietal region. A magnetic resonance imaging (MRI) showed: on T1-weighted sequences a hypointense necrotic cavity with ring enhancement following administration of intravenous gadolinium; on

T2-weighted sequences a hyperintense central area of pus surrounded by a well-defined hypointense capsule and surrounding edema. These findings suggested a neoplastic lesion or a brain abscess. Two days later he developed acute neurologic deterioration with focal epilepsy of the left arm. The neurosurgeons decided for diagnostic and therapeutic craniotomy. A pus containing lesion was found, decompression with drainage of pus and gross total excision of the abscess was performed but gram stain and routine aerobic culture were negative.

An empirical intra venous therapy was started with teicoplanin (400 mg/day), ceftazidime (4 g/day) and metronidazole (1.5 g/day), because the culture from the specimen was negative for bacteria, mycobacteria ad yeasts. Forty days later the patient developed a complete hemiplegia and hypoesthesia in the left side, neck stiffness, seizures and edema of the optic disk. A new MRI documented an enlargement of the hypointense lesion in the right frontal-parietal region, that was multiloculated, 5 cm of diameter, with large surrounding edema and enhancing rim (Fig. 1a and b). He underwent a second surgical drainage of the abscess. The microbiological examination by Gram stain from the specimen showed gram-positive, beaded, branching filaments, and acid-fast rods were seen with Kinyoun staining. Cultures yielded *Nocardia* spp. Therapy with trimethoprim/sulfamethoxazole (1280 T/6400 S mg/day), amikacin (1 g/day) and meropenem (6 g/day) was started immediately and continued for 35 days. We observed an initial neurological improvement after 2 weeks and at discharge from hospital the patient was

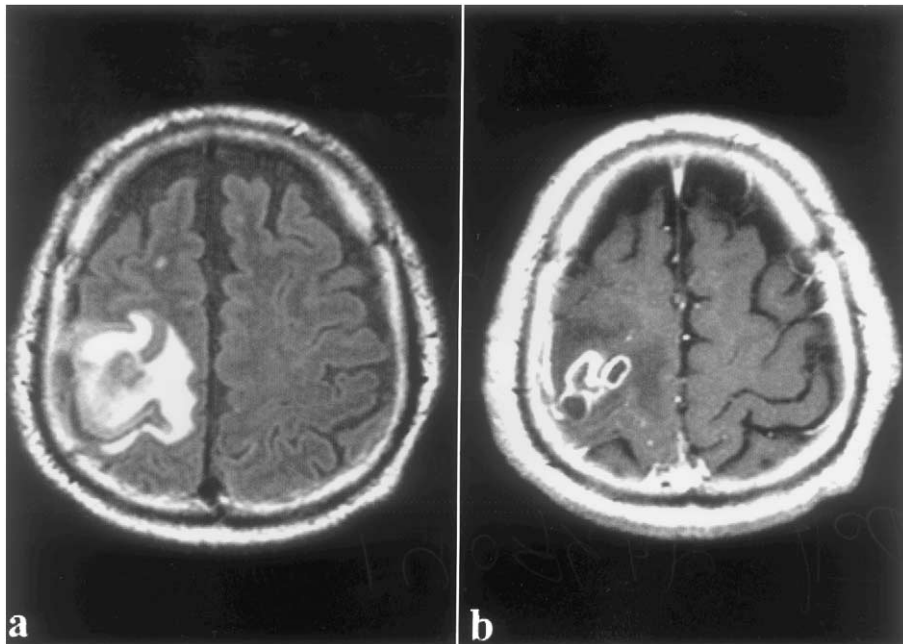


Fig. 1. (a) FLAIR T2 sequence, sub-cortical matter hyperintensity due to edema. (b) SE T1 post gadolinium sequence, multiple areas of parenchymali 'Ring Like' enhancement.

hemiparetic. Home therapy was done with oral trimethoprim/sulfamethoxazole (1280 T/6400 S mg/day) for 8 weeks and then reduced by 50%. Currently, 5 months from the second surgery, the patient can walk with support but, residual weakness of his left hand persists. No new episodes of epilepsy occurred. Side effects were absent from therapy. The MRI appearance of the brain lesion has improved, with a decrease in size, surrounding edema and ring enhancement.

Four months later *Nocardia* spp was identified as *Nocardia farcinica* susceptible to trimethoprim/sulfamethoxazole, amikacin, imipenem, ciprofloxacin, ceftriaxone but resistant to meropenem, tobramycin, gentamicin, erythromycin and tetracyclines.

3. Discussion

Before the advent of Human Immunodeficiency Virus infection, brain abscesses accounted for about 1 in 10 000 general hospital admission with 1500–2500 cases treated in the United States each year [9] and case-fatality rates ranging from 30 to 60% until the late 1970s, since when the overall mortality rate has decreased from 24% to zero [9–11]. Cerebral nocardiosis is associated with a high mortality and a significant incidence of relapse and the diagnosis may prove difficult especially in cases without the presence of extra-central nervous system involvement. Cranial CT, demonstrating a hypodense, enhancing lesion with surrounding edema, is fairly sensitive at detecting and localizing the lesion but is not diagnostic. In examination by MRI T2-weighted, multiple concentric rims were seen in abscess due to *Nocardia*. This could be a finding specific for infection. The rims may be due to organization of the necrotic debris and phagocytoses by macrophages in the capsule [12]. *Nocardia* abscesses tend to be multiloculated and poorly encapsulated due to the weak inflammatory response to the organism. Stereotactic cerebral biopsy [13,14] should be considered early in the diagnostic workup of an immunocompromised patient because of the high incidence of serious coexisting pathology and the more aggressive course than that traditionally ascribed to cerebral nocardiosis [3]. Microbiology laboratory should always be informed when nocardiosis is suspected inasmuch as the diagnosis may be missed by routine laboratory methods. Direct smears (Gram and Kinyoun stain) from specimens show gram-positive, beaded, branching filaments that are usually weakly acid-fast. *Nocardia* spp grows on most nonselective media used for culture of bacteria, fungi and mycobacteria but better in selective media such as BCYE agar. The successful management of nocardial brain abscess remains problematic. Clinical experience has shown that successful therapy requires the use of antimicrobial drugs in combination

with appropriate surgical drainage. Therapy with high-dose sulphadiazine or trimethoprim–sulphamethoxazole is appropriate for most patients but optimal antimicrobial regimens have not been established by controlled clinical trials. Even if imipenem plus amikacin remains the first choice therapy, antimicrobial susceptibility testing is recommended as a guide because the organism is relatively resistant to many antimicrobials [15]. The most effective drugs seem to be amikacin, imipenem and trimethoprim–sulphamethoxazole. Meropenem is a theoretically attractive alternative to imipenem in patients with cerebral nocardiosis because it has a similar pharmacokinetic profile, good cerebrospinal fluid penetration, and is associated with a lower incidence of seizure but its activity against *Nocardia* spp. must be confirmed [16]. We documented successful treatment of *Nocardia* brain abscess following combined approach with medical and surgical management. However, other cases have been reported with different outcome [17,18].

References

- [1] Mogilner A, Jallo GI, Zagzag D, Kelly PJ. *Nocardia* abscess of the choroid plexus: clinical and pathological case report. *Neurosurgery* 1998;43(4):949–52.
- [2] Filice GA, Simpson GL. Management of *Nocardia* infections. *Curr Clin Top Infect Dis* 1984;5:49–64.
- [3] Lerner PI. Nocardiosi. *Clin Infect Dis* 1996;22:891–905.
- [4] Beaman L, Beaman BL. *Nocardia* species: host-parasite relationships. *Clin Microbiol Rev* 1994;7:213–64.
- [5] Mamelak AN, Obana WG, Flaherty JF, Rosenblum ML. Nocardial brain abscess: treatment strategies and factors influencing outcome. *Neurosurgery* 1994;35:622–31.
- [6] Butler WR, Kilburn JO, Kubica GP. High-performance liquid chromatography analysis of mycolic acids as an aide in laboratory identification of *Rhodococcus* and *Nocardia* species. *J Clin Microbiol* 1987;25:2126–31.
- [7] Laurent F, Carlotti A, Boiron P, et al. Rybotyping: A tool for taxonomy and identification of the *Nocardia* asteroides complex species. *J Clin Microbiol* 1996;34:1079–82.
- [8] Georghiou PR, Blacklock ZM. Infection with *Nocardia* species in Queensland: A review of 102 clinical isolates. *Med J Aust* 1992;156:692–7.
- [9] Wispelwey B, Dacey RG Jr., Scheld WM. Brain abscess. In: Scheld WM, Whitley RJ, Durack DT, editors. *Infections of the Central Nervous System*, 2nd edition. Philadelphia: Lippincott-Raven, 1997:463–93.
- [10] Heilpern KL, Lorber B. Focal intracranial infections. *Infect Dis Clin North Am* 1996;10:879–98.
- [11] Kaplan K. Brain abscess. *Med Clin North Am* 1985;69:345–60.
- [12] Pyhtinen J, Paakko E, Jartti P. Cerebral abscess with multiple rims of MRI. *Neuroradiology* 1997;39(12):857–9.
- [13] Chacko AG, Chandy MJ. Diagnostic and staged stereotactic aspiration of multiple bihemispheric pyogenic brain abscesses. *Surg Neurol* 1997;48:278–83.
- [14] Barlas O, Sencer A, Erkan K, Eraksoy H, Sencer S, Bayindir C. Stereotactic surgery in the management of brain abscess. *Surg Neurol* 1999;52:404–11.
- [15] Farina C, Boiron P, Goglio A, Provost F. Human nocardiosis in northern Italy from 1982 to 1992. Northern Italy collaborative group on nocardiosis. *Scand J Infect Dis* 1995;27(1):23–7.

- [16] Weiseman LR, Wagstaf AJ, Brodgen RN. Meropenem. A review of its antibacterial activity, pharmacokinetic properties and clinical efficacy. *Drugs* 1995;50:73–101.
- [17] Fleetwood IG, Embil JM, Ross IB. *Nocardia asteroides* cerebral abscess in immunocompetent hosts: report of three cases and review of surgical recommendations. *Surg Neurol* 2000;53:605–10.
- [18] Durmaz R, Atasoy MA, Durmaz G, Adapinar B, Arslantas A, Aydinli A, et al. Multiple nocardial abscesses of cerebrum, cerebellum and spinal cord, causing quadriplegia. *Clin Neurol Neurosurg* 2001;103:59–62.