

Case report

Prolonged unilateral vasodilatation and brain edema in fulminant hepatic failure, associated with symptomatic seizure

Joji Inamasu ^{a,*}, Yoshiki Nakamura ^a, Shinichiro Yamamoto ^b, Namiko Sakamoto ^b,
Ryoichi Saito ^a, Takashi Horiguchi ^a, Kiyoshi Ichikizaki ^a

^a Department of Neurosurgery, National Tokyo Medical Center, Higashigaoka 2-5-1, Meguro-ku, Tokyo 152-8902, Japan

^b Department of Emergency Medicine, National Tokyo Medical Center, Tokyo, Japan

Received 31 October 2001; received in revised form 21 January 2002; accepted 21 January 2002

Abstract

We report prolonged unilateral vasodilatation and hemispheric brain edema in a 49-year-old man with fulminant hepatic failure (FHF). The patient presented with a tonic–clonic seizure caused by a hypertensive subcortical hemorrhage in the left parietal lobe. Serial computed tomography (CT) scans showed progressive darkening of the ipsilateral hemisphere, suggesting hemispheric cerebral infarction, but the patient did not show clinical signs of deterioration. Brain magnetic resonance angiography showed dilation of the large arteries of the left hemisphere. Evaluation of cerebral blood flow 7 days postictus with single photon emission CT revealed marked ipsilateral hyperperfusion. The darkening of the hemisphere was brain edema elicited by hyperperfusion. Brain edema was reversible, disappearing 14 days postictus. Hemispheric brain edema was caused by unilateral cerebral vasodilatation and resultant hyperperfusion. Although brain edema is a major complication in FHF patients and cerebral hyperperfusion is responsible for edema formation, CT findings of these patients almost invariably show a bilateral lesion. Unilateral vasodilatation and subsequent hemispheric hyperperfusion may be due to overproduction of vasodilators, already abundant in the brains of patients with severe hepatic failure, by seizure activity. © 2002 Elsevier Science B.V. All rights reserved.

Keywords: Brain edema; Cerebral blood flow; Fulminant hepatic failure; Hyperperfusion; Seizure; Vasodilatation

1. Introduction

Brain edema is a major complication in patients with fulminant hepatic failure (FHF), and cerebral hyperperfusion is considered to be one of the responsible mechanisms for brain edema formation: cerebral blood flow (CBF) studies in FHF patients who have computed tomography (CT) evidence of brain edema often demonstrate persistent hyperperfusion of the bilateral cerebral hemispheres [1–7]. However, unilateral hyperperfusion and brain edema rarely occur in such patients. We report prolonged unilateral vasodilatation, hyperperfusion and brain edema in a 49-year-old man with FHF who initially presented with convulsion. The clinical and radiological implications of this unique case are described, and possible cerebral hemodynamics in

FHF patients who present with symptomatic seizure are discussed.

2. Case report

A 49-year-old man with a prior medical history of alcoholic liver cirrhosis suffered a tonic–clonic seizure lasting 30 min, and was brought to our emergency department by ambulance. He had never experienced a seizure before. His consciousness was E1V1M4 evaluated by the Glasgow Coma Scale. The seizure disappeared shortly after a single intravenous injection of diazepam and his vital signs were stabilized. Neurological examinations showed hemiplegia of the right side. Laboratory data indicated that his liver function was severely damaged: platelet count was 31 000/ml, percent prothrombin time 36.8% (normal 70–140%), total bilirubin 13.5 mg/dl (normal < 1.0 mg/dl), and arterial ammonia 247 µg N/dl (normal < 50 µg N/dl). Hepatitis

* Corresponding author. Tel.: +81-3-3411-0111; fax: +81-3-3418-3380.

E-mail address: ginamasu@aol.com (J. Inamasu).

A, B, and C serologies were negative. A brain CT scan revealed a small subcortical hemorrhage in the left parietal lobe, which was thought to have caused the seizure (Fig. 1). He was treated conservatively with intravenous anticonvulsants and fluids rich in branched-chain amino acids to reduce elevated ammonia. One day after the seizure, both right-sided hemiplegia and his consciousness improved slightly. However, a CT scan showed diffuse darkening of the left cerebral hemisphere together with effacement of the cortical sulci (Fig. 2A). Serial CT scan 2 days after the seizure showed that the low density had become more intense (Fig. 2B), although the patient's hemiparesis disappeared and his consciousness improved to E2V3M5. Lumbar puncture yielded no evidence of meningitis or encephalitis. Hemispheric brain edema rather than cere-

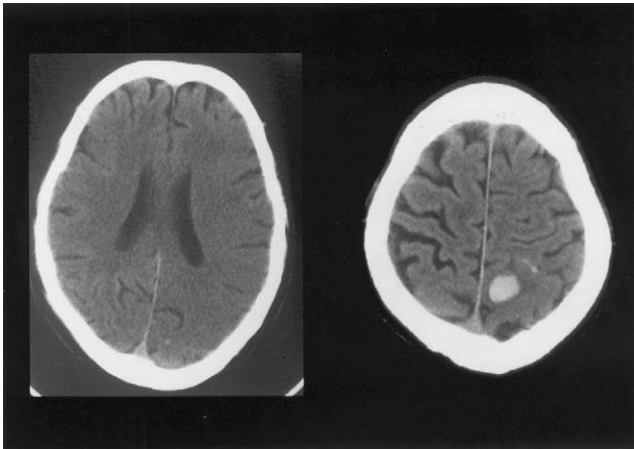


Fig. 1. CT scan on the day of the seizure. A section in the level of the body of the lateral ventricles seems normal (left). A small subcortical hemorrhage in the left parietal lobe was revealed in a section of the upper level (right).

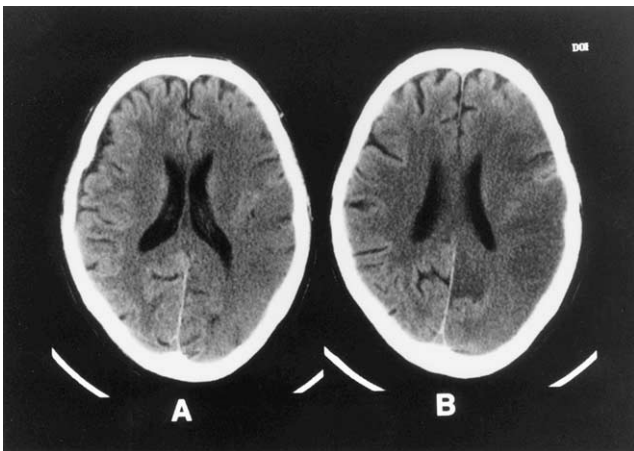


Fig. 2. CT scan 1 day after the seizure showing a hemispheric brain edema, with effacement of the cortical sulci (A). CT on 2 days after the seizure showed that the hemispheric low-density becomes more intense (B).

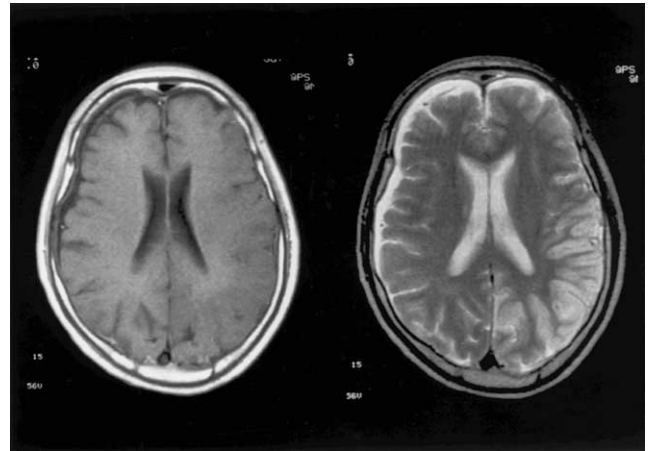


Fig. 3. MRI 4 days after the seizure (T1-weighted image: left; T2-weighted image: right), showing a diffuse cortical edema without involvement of the white matter.

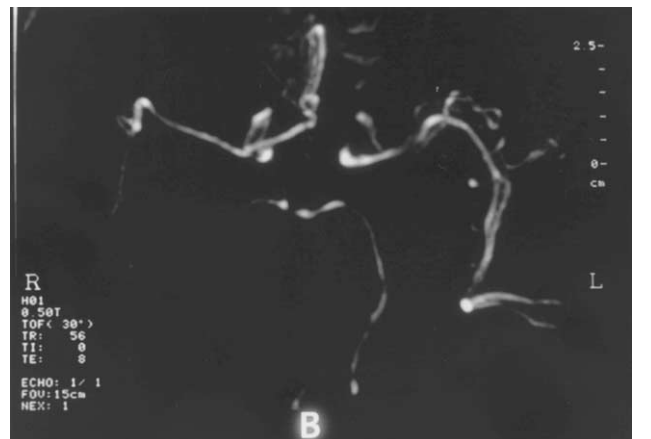
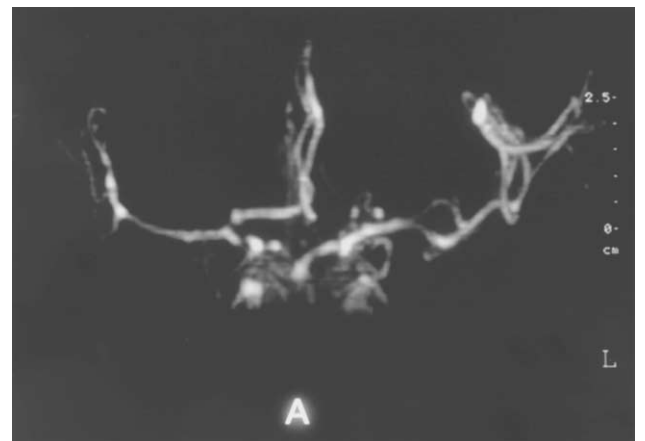


Fig. 4. Cerebral MRA (A) anteroposterior view; (B) view seen from feet to head) showing a marked vasodilation of large cerebral arteries of the left hemisphere. Note that in (B), the left posterior cerebral artery is dilated, as well as the left anterior and middle arteries seen in (A).

bral infarction was considered, and the patient underwent magnetic resonance imaging (MRI) 4 days after the seizure, which revealed diffuse cortical edema with

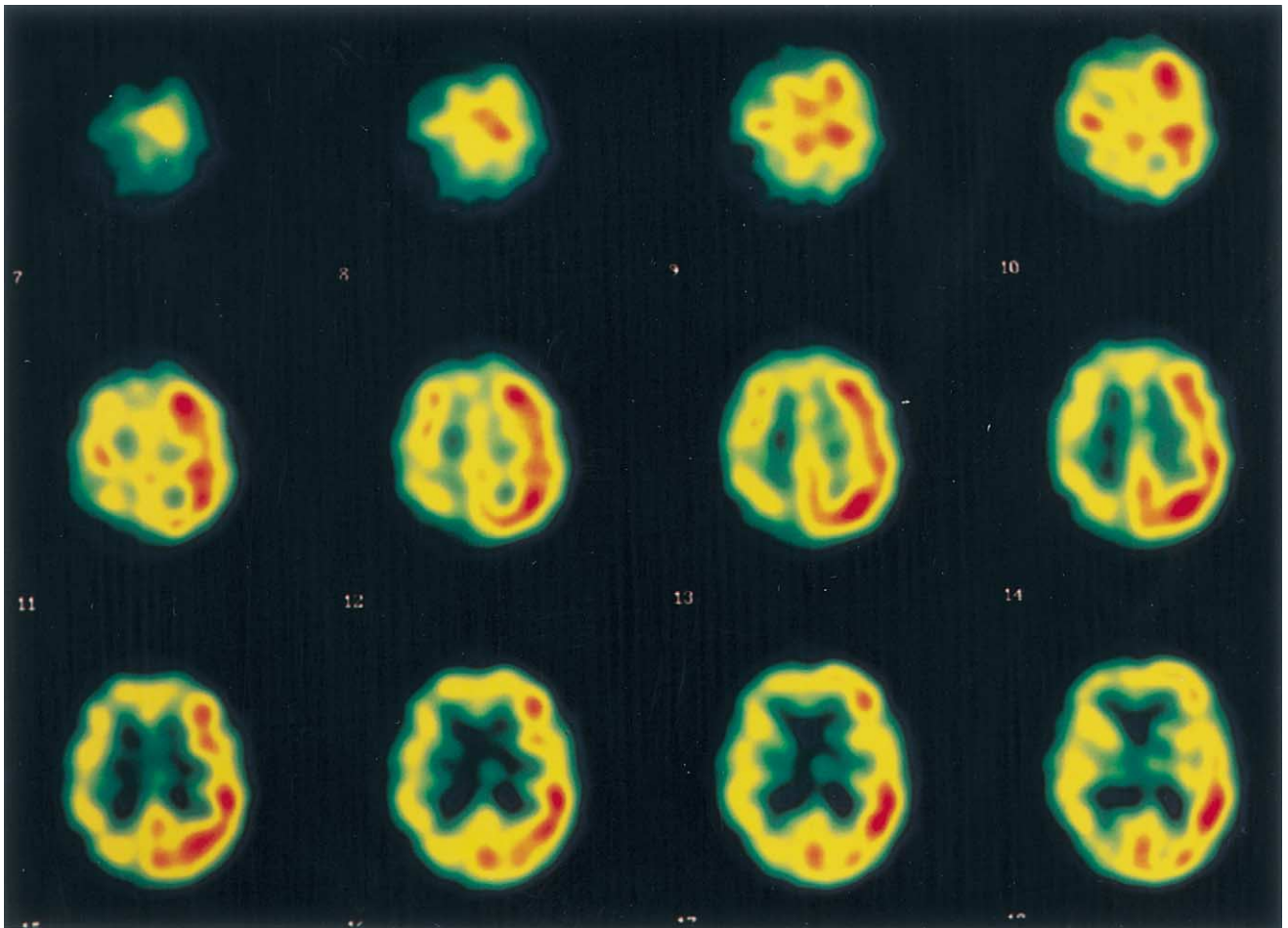


Fig. 5. ^{99m}Tc -ECD SPECT 7 days after the seizure showing hyperperfusion of the left cerebral hemisphere, compared with the right side.

out involvement of the white matter (Fig. 3). Cerebral MR angiography (MRA) was conducted at the same time to rule out arterial occlusion and to find the source of the subcortical hemorrhage, which paradoxically revealed markedly dilated left anterior, middle and posterior cerebral arteries compared with those of the right side (Fig. 4). Information on the patency of cerebral veins and sinuses was not directly obtained because conventional cerebral angiography could not be done due to severe thrombocytopenia. However, we assumed that venous occlusion was unlikely because there was an identifiable flow-void sign of cerebral veins and sinuses on MRI in a T2-weighted image. No vascular anomaly as a possible cause of the subcortical hemorrhage was detected by MRA. To evaluate cerebral hemodynamics of the patient, CBF was evaluated with ^{99m}Tc -ethyl cysteine dimer (^{99m}Tc -ECD) single photon emission CT (SPECT) 7 days after the seizure, which revealed hyperperfusion of the left cerebral hemisphere compared with the right side (Fig. 5). On the same day, electroencephalogram failed to show any seizure activities in either cerebral hemisphere. The patient had sensory aphasia but no weakness, and his consciousness

improved to E4V3M6 14 days after the seizure. A CT scan showed that brain edema had resolved (Fig. 6). With supportive treatment, laboratory data showed marked improvement including a platelet count of

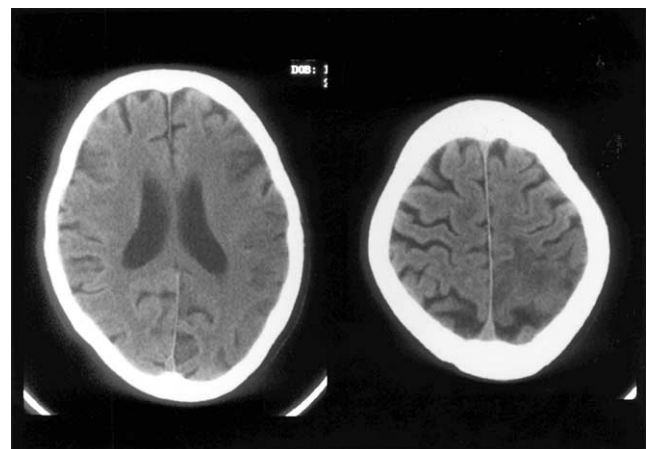


Fig. 6. CT scan 14 days after the seizure showing that the hemispheric edema had resolved. Note a small low-density area where the subcortical hemorrhage was located (right).

236 000/ml, percent prothrombin time of 52.9%, total bilirubin of 5.5 mg/dl, and arterial ammonia of 53 μ g N/dl. The patient, with only mild sensory aphasia, was referred to rehabilitation 20 days after admission.

3. Discussion

Serial CT findings in the present case showed progressive hemispheric low density, which was initially thought to be hemispheric cerebral infarction but proved to be brain edema. Brain edema is one of the serious complications of FHF [1–7]. CBF studies in FHF patients who presented with clinical signs of brain edema often demonstrate persistent hyperperfusion of the bilateral cerebral hemispheres [5,6]. The cause of hyperperfusion in FHF remains to be elucidated, but has been attributed to cerebral vasodilatation caused by elevated ammonia, nitric oxide, cytokines, or lactate [3,4,6]. Recently, the role of glutamate-nitric oxide in cerebral vasodilatation in FHF patients has also been reported: elevated parenchymal glutamate due to decreased activity of the glutamate transporter, GLT-1, in FHF patients activates neuronal nitric oxide synthase (n-NOS), which in turn acts as a potent vasodilator [3,8]. The present case is unique in that unilateral vasodilatation of the cerebral arteries was visualized with the use of MRA (Fig. 4). Although vasodilatation has been speculated as the cause of hyperperfusion in FHF, its radiological demonstration has rarely been undertaken due to difficulty in performing cerebral angiography in FHF patients who frequently are associated with severe thrombocytopenia.

Regarding the reason why prolonged unilateral vasodilatation and hyperperfusion occurred in the present case, we speculate that vasodilators already elevated in the presence of FHF was further increased by seizure activity in the lesioned hemisphere, leading to prolonged, unilateral vasodilatation. Postictal brain CT scans in patients with seizure not infrequently show brain edema [9,10]. Brain edema after seizure has two components, cytotoxic and vasogenic edema [11]. Cytotoxic edema, elicited by hypoxia, produces noxious substances that disrupt the integrity of the blood–brain barrier and subsequently cause vasogenic edema. Ictal hyperperfusion occurs due to increased metabolic demand in and around the epileptogenic focus, and is caused by a transient breakdown of the cerebral autoregulation and vasodilatation [12,13]. The vasodilatation is caused by the action of locally produced

vasodilators, such as nitric oxide and lactate [11]. Although the increase of CBF is usually temporary and the period of hyperperfusion is limited during seizure activity [13], excessive accumulation and/or impaired clearance of such vasodilators may cause prolonged unilateral vasodilatation and hyperperfusion, as seen in the present case. Serial measurement of parenchymal vasodilators with microdialysis technique could verify this hypothesis.

In conclusion, rare prolonged vasodilatation and hyperperfusion presenting as hemispheric brain edema in a FHF patient after symptomatic seizure was reported. Evaluation of CBF with SPECT, and of cerebral vasculature with MRA, was useful in accurately diagnosing unique serial CT changes in the present case.

References

- [1] Wijidicks EFM, Plevak DJ, Rakela J, Wiesner RH. Clinical and radiographic features of cerebral edema in fulminant hepatic failure. *Mayo Clin Proc* 1995;70:119–24.
- [2] Donovan JP, Schaefer DF, Shaw BW, Sorrel MF. Cerebral edema and increased intracranial pressure in chronic liver disease. *Lancet* 1998;351:719–21.
- [3] Blei AT, Larsen FS. Pathophysiology of cerebral edema in fulminant hepatic failure. *J Hepatol* 1999;31:771–6.
- [4] Blei AT. Medical therapy of brain edema in fulminant hepatic failure. *Hepatology* 2000;32:666–9.
- [5] Wendon JA, Harrison PM, Keays R, Williams R. Cerebral blood flow and metabolism in fulminant liver failure. *Hepatology* 1994;19:1407–13.
- [6] Aggarwal S, Kramer D, Yonas H, et al. Cerebral hemodynamic and metabolic changes in fulminant hepatic failure: a retrospective study. *Hepatology* 1994;19:80–7.
- [7] Dempsey RJ, Kindt GW. Experimental acute hepatic encephalopathy: relationship of pathological cerebral dilation to increased intracranial pressure. *Neurosurgery* 1982;10:737–41.
- [8] Butterworth RF. Hepatic encephalopathy and brain edema in acute hepatic failure: does glutamate play a role? *Hepatology* 1997;25:1032–4.
- [9] Goulatia RK, Verma A, Mishra NK, Ahuja GK. Disappearing CT lesions in epilepsy. *Epilepsia* 1987;28:523–7.
- [10] Yaffe K, Ferriero D, Barkovich AJ, Rowley H. Reversible MRI abnormalities following seizures. *Neurology* 1995;45:104–8.
- [11] Tan WK, Williams CE, Doring MJ, et al. Accumulation of cytotoxins during the development of seizures and edema after hypoxic-ischemic injury in late gestation fetal sheep. *Pediatr Res* 1996;39:791–7.
- [12] Avery RA, Spencer SS, Spanaki MV, Corsi M, Seibyl JP, Zubal G. Effect of injection time on postictal SPET perfusion changes in medically refractory epilepsy. *Eur J Nuc Med* 1999;26:830–6.
- [13] Runge U, Kirsch G, Petersen B, et al. Ictal and interictal ECD-SPECT for focus localization in epilepsy. *Acta Neurol Scand* 1997;96:271–6.