

CASE REPORT

A case of severe hypertension caused by ACTH-independent macronodular adrenal hyperplasia

R. Nocente*, L. De Marinis**, A. Mancini**, A. Bianchi**, R. Bellantone***, L. Lauriola****, M. Costanzo*, C. De Crea***, G. Gasbarrini*, and N. Gentiloni Silveri*

*Institute of Internal Medicine; **Institute of Endocrinology, ***Institute of General Surgery; ****Institute of Pathology; Catholic University of Rome, Italy

ABSTRACT. This report describes a rare case of ACTH-independent macronodular adrenal hyperplasia (AIMAH) arisen with symptomatic severe hypertension and hypokaliemia. A 55-year-old man was admitted to hospital with a clinical picture characterized by several episodes of transient ischemic attacks (TIA) and right hemiplegia, related to severe arterial hypertension. Laboratory tests showed urinary levels of catecholamines, metanephrines and vanillylmandelic acid (VMA) in normal range; high urinary free cortisol excretion, elevated serum cortisol with loss of the circadian rhythm and low ACTH plasma levels. ACTH failed to respond to CRH administration. Serum cortisol levels were not modified after high doses of dexamethasone. MRI showed bilateral macronodular hyperplasia of adrenal glands, whereas pituitary-

MRI did not show tumoral lesions. Therefore, ACTH-independent macronodular hyperplasia was suspected. Though obese, the patient had no typical Cushing habit, and symptomatic hypertension with hypokaliemia was the only clinical evidence for this rare kind of Cushing's syndrome. After obtaining a satisfactory control of blood pressure, the patient was successfully submitted to laparoscopic bilateral adrenalectomy and underwent complete clinical remission. The histology showed adrenal macronodular hyperplasia. During the twenty-four month follow-up, the patient had no further transient ischemic attacks or need of glucocorticoid replacement therapy and withdrew the antihypertensive drugs.

(J. Endocrinol. Invest. 25: 254-258, 2002)

©2002, Editrice Kurtis

INTRODUCTION

Cushing's syndrome is traditionally classified in ACTH-dependent and ACTH-independent disorders. In the first case, the bilateral adrenal hyperplasia and hyperfunction are related to the ACTH stimulation, whereas the ACTH-independent syndrome, in the majority of patients, is caused by unilateral adrenocortical neoplasm (adrenal adenoma or carcinoma) (1).

Only less than 10% of the cases of ACTH-independent Cushing's syndrome are secondary to bilateral adrenal hyperplasia, and their pathophysiologies are different. Primary pigmented nodular adreno-

cortical disease (PPNAD) or micronodular adrenal dysplasia can be familial, associated with other tumors (myxomas, schwannomas, pigmented cutaneous lesions, and peripheral endocrine tumors) and linked to unknown genes or to mutations (2-4). ACTH-independent macronodular adrenal hyperplasia (AIMAH) is a rare case of Cushing's syndrome (CS) and the incidence is estimated to represent about 1% of CS: it is characterized by cortisol hypersecretion, due to multiple bilateral adrenocortical macronodules of benign hyperplasia; both adrenal glands are enlarged in size, without pituitary neoplasms or other tumoral lesions (1, 5-8). Today AIMAH is recognized as a distinct subtype of Cushing's syndrome because of the unique clinical, endocrinological, histological and immunohistochemical features, but the pathogenesis of this disease is still unclear. Here, we report a rare case of AIMAH, presented clinically through obesity, ar-

Key-words: Hypertension, hypokaliemia, Cushing's syndrome, AIMAH.

Correspondence: Dr. Laura De Marinis, Via Cassia 901, 00189 Roma, Italy.

E-mail: laurademarinis@yahoo.it

Accepted July 15, 2001.

terial hypertension and TIA, and successfully treated with surgical therapy (9-12).

CASE REPORT

A 55 year-old man, obese and heavy smoker, was admitted to the internal medicine department because of several episodes of transient ischemic attacks (TIA), characterized by hypertensive peaks and transient right hemiplegia. For the last two years he had been affected by arterial hypertension, treated successfully with Nicardipine (20 mg/day). There was no family history of CS or other endocrine diseases. On physical examination, he was 171 cm tall and weighed 89.5 kg (BMI=31.4 kg/m²). He did not show rounded face, striae or ecchymosis and skin pigmentation was normal. In the month previous to hospitalization, blood pressure increased (mean value: 180/120 mmHg; pulse rate 74/min) and required a progressively strong treatment based on enalapril, clonidine and labetalol during hospitalization. Blood tests reported hypokaliemia (potassium=2.3 mEq/l; n.r.=3.6-5 mEq/l) and cholesterol was elevated (271 mg/dl; n.r.=130-200 mg/dl). Fasting glucose was 125 mg/dl and OGTT showed intolerance to carbohydrates. Both ECG and echocardiography showed severe hypertrophy of the left ventricle, while myocardial contractility was conserved (ejection rate=60%). Cranial CT documented the presence of previous multiple lacunar infarcts.

During hypertensive episodes urinary levels of catecholamines, metanephrines and vanillylmandelic acid (VMA) were in the normal range. Both plasma aldosterone (26 pg/ml) and renin (3.3 pg/ml) were in the low range (n.r. plasma aldosterone=20-125; n.r. plasma renin=1.5-20) and basal deoxycorticosterone (DOC) was 23 ng/dl (n.r.=3.5-11.5 ng/dl). Urinary free cortisol was 218 µg/24h (n.r.=20-90), and the circadian cortisol profile, evaluated by four samples was altered: 08:00 h:219; 12:00 h:228; 18:00 h:227; 00:00 h:218 (n.r.=80-220 ng/ml). Serum cortisol was not suppressed both by low-dose (1 mg) and high-dose (8 mg) overnight dexamethasone administration and ACTH was low (mean value 6.5 pg/ml; n.r.=10-55 pg/ml). ACTH failed to respond to CRH administration. Endocrinological assays included the measurement of the following steroids: DHEA-S was 140 ng/ml (n.r.=1000-3500), $\Delta 4$ 0.41 ng/ml (n.r.=0.30-2.60 ng/ml), T 3.99 ng/ml (n.r.=3.5-10 ng/ml), 17-OH progesterone 0.90 ng/ml (n.r.=0.30-2.5 ng/ml). Cranial and hypothalamus-hypophysis magnetic resonance imaging (MRI) reported absence of pituitary tumoral lesions and confirmed the evidence of lacunar infarcts. Both abdominal CT and MRI scans revealed bilateral enlargement of the adrenal glands

with huge multiple nodules (Fig. 1). ¹³¹I-6 β -iodomethylnorcholesterol scintigraphy showed a remarkable bilateral uptake by the adrenal glands. In addition to the antihypertensive treatment started in the hospital (clonidine 900 mg/day, labetalol 600 mg/daily, enalapril 40 mg/day), ketoconazole therapy at the dose of 400 mg/day obtained a sufficient control of blood pressure; one month later, the patient was submitted to bilateral laparoscopic adrenalectomy. The post-operative course was uneventful and hydrocortisone replacement was required at progressively lower dosage during the follow-up; carbohydrate metabolism, blood pressure and serum potassium normalized. Thus, TIA did not occur again and now, 24 months after adrenalectomy, the patient is only treated with hydrocortisone replacement therapy (20 mg/day), without antihypertensive drugs.

Histopathological examination and assay methods

The removed adrenal glands were enlarged, macronodular and weighted 80 and 95 g respectively, containing yellow nodules of various sizes. The tissues were fixed in buffered formalin embedded in paraffin. Sections were stained with Hematoxylin-eosin. The histological examination revealed a monotonous proliferation of large clear cells with small and uniform nuclei and an unvacuolated cytoplasm, arranged in cords or nets. Occasionally, small compact cells were mixed with the major proliferation of clear cells. Small remnants of normal cortical and medullary adrenal tissue were occasionally found (Fig. 2).

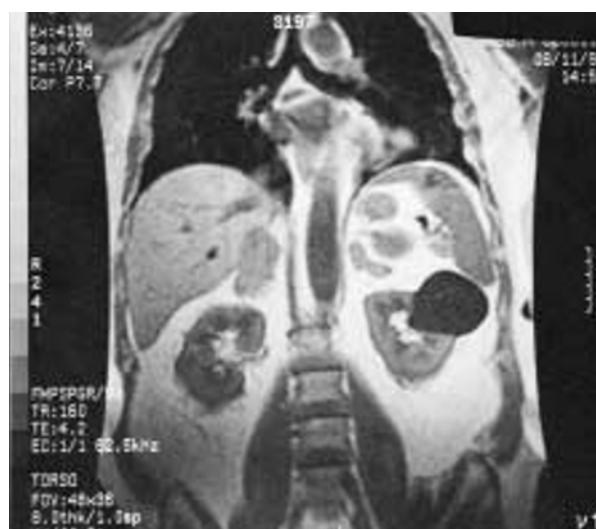

Fig.1 - MRI reporting bilateral enlargement of the adrenal glands with irregular nodular aspect.

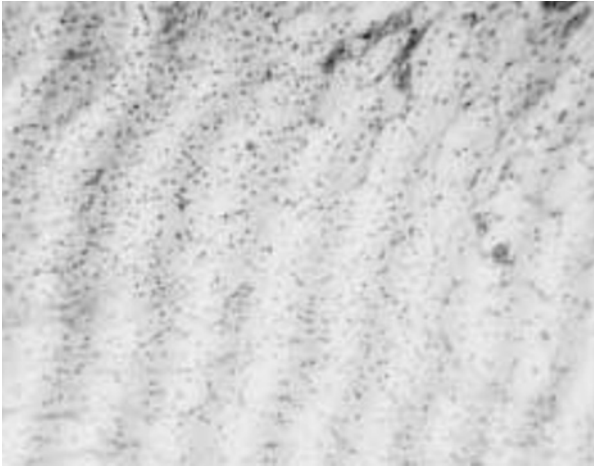


Fig. 2 - Adrenal histology showing hyperplasia and multiple nodules composed of large clear cells and small compact cells.

Plasma ACTH and renin were measured by IRMA assay using commercial kits (Nichols Institute Diagnostics, San Juan Capistrano, CA, U.S.A.). Catecholamines, VMA and metanephrines were measured after HPLC (Bio Rad, Hercules, CA, U.S.A.). Plasma DOC was measured using RIA after extraction and chromatography (Nichols Institute Diagnostics, San Juan Capistrano, CA, U.S.A.). Aldosterone, 17-OH progesterone and $\Delta 4$ by RIA (Diagnostic Systems Laboratories Inc., Webster, TX, U.S.A.). Serum and urinary cortisol, DHEA-S and T were measured by commercial RIA. Intra and inter-assay variations were below 10% for every sample.

DISCUSSION

ACTH-independent bilateral AIMAH is an infrequent case of CS and the incidence is estimated to represent about 1% of CS. In literature, AIMAH has been described with various terms, including massive macronodular adrenocortical disease (MMAD), autonomous macronodular adrenal hyperplasia (AMAH), ACTH-independent massive bilateral adrenal disease (AIMBAD), "giant" or "huge" macronodular adrenal disease. Only one case has been reported in an infant (13), but in several other cases and series of patients the clinical syndrome becomes evident during the 5th-6th decade and is characterized by similar gender distribution when compared with Cushing's disease or unilateral adrenal neoplasms, which are more prevalent in women (2-4, 14).

In our patient, the clinical and pathological findings are mostly consistent with the typical features of AIMAH as described previously; the persistent low

ACTH levels, unresponsive to CRH administration; the mild elevation of serum cortisol without hormonal diurnal rhythm and insuppressible by high-dose dexamethasone administration; the reduced DHEA-S levels demonstrated that cortisol hypersecretion was ACTH-independent. Histopathological examination confirmed the features described in literature (3, 5, 7): unlike the pigmented nodules of PPNAD and the ACTH-dependent hyperplasia (15), both glands are composed of yellow nodules, similar to normal adrenal tissue, with a high combined adrenal gland weight (175 g), although in a large series of patients the difficulty of setting a cut-off (below which AIMAH could be safely excluded) has been observed (4, 14). The microscopic analysis of the glands showed a large heterogeneity in AIMAH; nevertheless, as described in our case, two predominant cell types are present: large and small cells, both with clear cytoplasm. Immunohistochemical analysis and *in situ* hybridization studies demonstrated that the steroidogenic enzymes P450scc, P450c21 and P450c11 were present in both cellular types, whereas P450c17 and 3 β HSD were localized in the small and large cells respectively (5). Morioka *et al.* (16) evaluated the activities of the cytochrome P450c21, P450c17 and P450c11 and demonstrated that all of them were reduced, especially P450c17. These last data suggest that in AIMAH cortisol production could be inefficient and Cushing's syndrome may be related to the marked increase in the number of cells or bulk of adrenal hyperplasia. However, the peculiarity of our case was hypertension and severe vascular disease in a patients with AIMAH, without a typical cushingoid phenotype. Glucocorticoid excess is associated with hypertension in at least 70-75% of patients with CS, independently of the subtype (pituitary or adrenal) and the duration, and cardiovascular damage is quite frequent in hypertensive subjects, but is sometimes also present in normotensive subjects. The mortality of patients with CS, usually caused by cardiovascular disease, is 4 times that of the general population when matched for age and sex (17, 18). In humans, the hypertensive effects reproduced by iv or oral cortisol, or studied in CS demonstrated that: oral cortisol increases blood pressure in a dose-dependent fashion; the circadian blood pressure variations are absent or reversed; cortisol-induced hypertension is accompanied by significant sodium retention and volume expansion; administration of the type I mineralocorticoid receptor antagonist spironolactone does not prevent the onset of cortisol-induced hypertension. Thus, sodium retention is not the primary mechanism of cortisol-induced hypertension; direct and indirect measures of sympathetic activity are unchanged or suppressed during cortisol adminis-

tration or CS, suggesting that cortisol-induced hypertension is not mediated by increased sympathetic tone. Although these potential mechanisms of cortisol action may be relevant in a number of clinical contexts (including CS, apparent mineralocorticoid excess, hypertension, liquorice abuse, chronic renal failure) and many actions on brain, heart and blood vessels, kidney, and body fluid compartments have been described, precisely how cortisol elevates blood pressure is still unclear. Candidate mechanisms currently examined include inhibition of the vasodilator nitric oxide system and increases in vasoconstrictor erythropoietin concentration (19, 20). To our knowledge, the AIMAH cases described previously in the literature do not report such severe hypertension with hypokaliemia. However, a rare case of AIMAH associated with hypertension, excessive secretion of mineralocorticoids and hypokaliemia was reported by Hayashi *et al.* (21). Another patient with bilateral adrenal incidentalomas was studied by Yamada *et al.* (22) and was diagnosed as pre-clinical CS due to AIMAH confirmed histologically: despite the undetectable renin activity, serum mineralocorticoids levels were not suppressed and it was suggested that hyperplastic adrenal glands could produce both gluco- and mineralocorticoids concomitantly. Finally, the absence of classic Cushing's signs and symptoms of our patient is rare in AIMAH, but has been described before and in a few cases the onset of disease was characterized only by clinic history of hypertension or adrenal enlargement found incidentally by ultrasound or CT (4, 23-26).

Hypertension and hypokaliemia, but without increase in plasma aldosterone concentrations are also features of the glucocorticoid-resistance (GR). In fact, in these patients the most common characteristic is hypercortisolism without clinical picture of glucocorticoid excess. Nevertheless, since the original description of Vingerhoeds *et al.* (27), about 30 patients, later on identified, showed a typical syndrome characterized by decreased sensitivity to cortisol with secondary activation of the hypothalamo-pituitary-adrenal axis which resulted in: increased ACTH and cortisol secretion, normal circadian rhythm at elevated levels, relative resistance of adrenal cortisol to dexamethasone, no signs or symptoms of CS and, in most cases, ACTH-dependent overproduction of adrenal androgens and mineralocorticoids (28, 29).

In conclusion, despite the pathogenesis of this rare disorder remains unclear, AIMAH must be considered a separate, unique and legitimate subtype of primary adrenocortical CS with distinct histopathological and immunohistochemical features. Although laboratory analysis and endocrinological findings are often typi-

cal of CS, the clinical picture of AIMAH could be poor and hypertension or adrenal incidentalomas are the onset signs or symptoms of this disorder. The wide spectrum of clinical picture of AIMAH as well as the marked delay in establishing the diagnosis in some patients may be attributable to their impaired and variable steroidogenic pathway. Moreover, recent studies have indicated that abnormal or ectopic expression and function of adrenal receptors for various hormones may regulate cortisol production in ACTH-independent hypercortisolism. The bilateral adrenocortical hyperplasia may be secondary to an increased responsiveness to gastric inhibitory polypeptide (GIP), to vasopressin, to beta-adrenergic, to hCG/LH, or serotonin 5-HT-4 receptor agonists (4, 30-33). Therefore, our case showed that in the presence of a severe hypertension with hypokaliemia and absence of, or doubtful, CS signs and symptoms, patients should undergo screening for AIMAH by adrenal CT or MRI findings (34) and repeated ACTH plasma levels. According to the literature (35-37) our study also confirms that ketoconazole may be useful as adjuvant therapy for the palliative control of hypertension in CS. However, further cases of AIMAH should be carefully investigated to elucidate the physiopathologic mechanism of this disorder.

REFERENCES

1. Newell-Price J., Trainer P., Besser M., *et al.* The diagnosis and differential diagnosis of Cushing's syndrome and Pseudo-Cushing's states. *Endocr. Rev.* 1998, 19: 647-672.
2. Lacroix A., Ndiaye N., Tremblay J., *et al.* Ectopic and abnormal hormone receptors in adrenal Cushing's syndrome. *Endocr. Rev.* 2001, 22: 75-110.
3. Stratakis C.A., Kirschner L.S. Clinical and genetic analysis of primary bilateral adrenal diseases (micro- and macronodular disease) leading to Cushing syndrome. *Horm. Metab. Res.* 1998, 30: 456-463.
4. Lieberman S.A., Eccleshall T.R., Feldman D. ACTH-independent massive bilateral adrenal disease (AIMBAD): a subtype of Cushing's syndrome with major diagnostic and therapeutic implications. *Eur. J. Endocrinol.* 1994, 131: 67-73.
5. Wada N., Kubo M., Kijima H., *et al.* Adrenocorticotropin-independent bilateral macronodular adrenocortical hyperplasia: immunohistochemical studies of steroidogenic enzymes and post-operative course in two men. *Eur. J. Endocrinol.* 1996, 134: 583-587.
6. Sasanno H., Suzuki T., Nagura H. ACTH-independent macronodular adrenocortical hyperplasia: Immunohistochemical and in situ hybridization studies of steroidogenic enzymes. *Mod. Pathol.* 1994, 7: 215-219.
7. Terzolo M., Boccuzzi A., Ali A., *et al.* Cushing's syndrome due to ACTH-independent bilateral adrenocortical macronodular hyperplasia. *J. Endocrinol. Invest.* 1997, 20: 270-275.

8. Ross R.J.M., Trainer P.J. Endocrine investigation: Cushing's syndrome. *Clin. Endocrinol. (Oxf.)* 1998, 49: 153-155.
9. Brunt L.M., Doherty G.M., Norton J.A., et al. Laparoscopic adrenalectomy compared to open adrenalectomy for benign adrenal neoplasms. *J. Am. Coll. Surg.* 1996, 183: 1-10.
10. Gagner M. Laparoscopic adrenalectomy *Surg. Clin. North Am.* 1996, 76: 3.
11. Yoshimura H., Ishimaru M., Endoh Y.S., et al. Comparison of clinical outcomes of laparoscopic and conventional open adrenalectomy. *J. Endourol.* 1998, 12: 555-559.
12. Gagner M., Pomp A., Heniford B.T., et al. Laparoscopic adrenalectomy: lessons learned from 100 consecutive procedures. *Ann. Surg.* 1997, 226: 238-246.
13. Boston B.A., Mandel S., LaFranchi S., et al. Activating mutation in the stimulatory guanine nucleotide-binding protein in an infant with Cushing's syndrome and nodular adrenal hyperplasia. *J. Clin. Endocrinol. Metab.* 1994, 79: 890-893.
14. Swain J.M., Grant C.S., Schlinkert R.T., et al. Corticotropin-independent macronodular adrenal hyperplasia: a clinicopathologic correlation. *Arch. Surg.* 1998, 133: 541-545; discussion 545-546.
15. Smals A.G., Pieters G.F., van Haelst U.J., et al. Macronodular adrenocortical hyperplasia in long-standing Cushing's disease. *J. Clin. Endocrinol. Metab.* 1984, 58: 25-31.
16. Morioka M., Ohashi Y., Watanabe H., et al. ACTH-independent macronodular adrenocortical hyperplasia (AIMAH): report of two cases and the analysis of steroidogenic activity in adrenal nodules. *Endocr. J.* 1997, 44: 65-72.
17. Mantero F., Boscaro M. Glucocorticoid-dependent hypertension. *J. Steroid. Biochem. Mol. Biol.* 1992, 43: 409-413.
18. Sugihara N., Shimizu M., Kita Y., et al. Cardiac characteristics and postoperative courses in Cushing's syndrome. *Am. J. Cardiol.* 1992, 69: 1475-1480.
19. Whitworth J.A., Mangos G.J., Kelly J.J. Cushing, cortisol, and cardiovascular disease. *Hypertension* 2000, 36: 912-916.
20. Whitworth J.A., Kelly J.J., Brown M.A. et al. Glucocorticoids and hypertension in man. *Clin. Exp. Hypertens.* 1997, 19: 871-884.
21. Hayashi Y., Takeda Y., Kaneko K., et al. A case of Cushing's syndrome due to ACTH-independent bilateral macronodular hyperplasia associated with excessive secretion of mineralocorticoids. *Endocr. J.* 1998, 45: 485-491.
22. Yamada Y., Sakaguchi K., Inoue T., et al. Pre-clinical Cushing's syndrome due to adrenocorticotropin-independent bilateral adrenocortical macronodular hyperplasia with concurrent excess of gluco- and mineralocorticoids. *Intern. Med.* 1997, 36: 628-632.
23. Izumi T., Sasagawa I., Suzuki H., et al. Adrenocorticotropin-independent bilateral macronodular adrenocortical hyperplasia presenting as pre-Cushing's syndrome. *Urol. Int.* 1997, 58: 262-265.
24. Miyajima A., Nakashima J., Tachibana M., et al. ACTH-independent bilateral macronodular adrenocortical hyperplasia caused Cushing's syndrome. *Urol. Int.* 1997, 58: 259-261.
25. Nemoto Y., Aoki A., Katayama Y., et al. Non-cushingoid Cushing's syndrome due to adrenocorticotropin hormone-independent bilateral adrenocortical macronodular hyperplasia. *Intern. Med.* 1995, 34: 446-450.
26. Irie J., Kawai K., Shigematsu K., et al. Adrenocorticotropin hormone-independent bilateral macronodular adrenocortical hyperplasia associated with Cushing's syndrome. *Pathol. Int.* 1995, 45: 240-246.
27. Vingerhoeds A.C., Thijssen J.H., Schwarz F. Spontaneous hypercortisolism without Cushing's syndrome. *J. Clin. Endocrinol. Metab.* 1976, 43: 1128-1133.
28. Lamberts S.W., Koper J.W., Biemond P., et al. Cortisol receptor resistance: the variability of its clinical presentation and response to treatment. *J. Clin. Endocrinol. Metab.* 1992, 74: 313-321.
29. Huizenga N.A., de Lange P., Koper J.W., et al. Five patients with biochemical and/or clinical generalized glucocorticoid resistance without alterations in the glucocorticoid receptor gene. *J. Clin. Endocrinol. Metab.* 2000, 85: 2076-2081.
30. N'diaye N., Tremblay J., Hamet P., et al. Adrenocortical over-expression of gastric inhibitory polypeptide receptors underlies food-dependent Cushing's syndrome. *J. Clin. Endocrinol. Metab.* 1998, 83: 2781-2785.
31. Horiba N., Suda T., Aiba M., et al. Lysine vasopressin stimulation of cortisol secretion in patients with macronodular adrenocorticotropin-independent adrenal hyperplasia. *J. Clin. Endocrinol. Metab.* 1995, 80: 2336-2341.
32. Iida K., Kaji H., Matsumoto H. et al. Adrenocorticotrophin-independent macronodular adrenal hyperplasia in a patient with lysine vasopressin responsiveness but insensitivity to gastric inhibitory polypeptide. *Clin. Endocrinol. (Oxf.)* 1997, 47: 739-745.
33. Lacroix A., Tremblay J., Rousseau G., et al. Propranolol therapy for ectopic beta-adrenergic receptors in adrenal Cushing's syndrome. *N. Engl. J. Med.* 1997, 337: 429-434.
34. Doppman J.L., Chrousos G.P., Papanicolaou D.A., et al. Adrenocorticotropin-independent macronodular adrenal hyperplasia: An uncommon cause of primary adrenal hypercortisolism. *Radiology* 2000, 216: 797-802.
35. Neto L.S., Filho A.G., Bustorff-Silva J.M., et al. Pre-operative control of arterial hypertension using ketoconazole in pediatric patients with adrenocortical tumors. *J. Pediatr. Endocrinol. Metab.* 2000, 13: 201-204.
36. Strohm M., Reincke M., Theiss M., et al. Bilateral massive macronodular adrenal gland hyperplasia. A rare cause of Cushing's syndrome. *Dtsch. Med. Wochenschr.* 1994, 119: 180-184.
37. Fallo F., Paoletta A., Tona F., et al. Response of hypertension to conventional antihypertensive treatment and/or steroidogenesis inhibitors in Cushing's syndrome. *J. Intern. Med.* 1993, 234: 595-598.