

De Novo Cerebral Arteriovenous Malformation: Case Report

Ketan R. Bulsara, M.D., Michael J. Alexander, M.D.,
Alan T. Villavicencio, M.D., Carmelo Graffagnino, M.D.

Divisions of Neurosurgery (KRB, MJA, ATV) and Neurology (CG), Duke University Medical Center, Durham, North Carolina

OBJECTIVE AND IMPORTANCE: Arteriovenous malformations (AVMs) are generally thought to have a congenital cause. This is the first report of an angiographically proven de novo cerebral AVM in an adult patient without previous vascular abnormality.

CLINICAL PRESENTATION: A 26-year-old African-American woman developed multiple cranial nerve deficits and ataxia over the course of a few days after a streptococcal throat infection. T2-weighted magnetic resonance imaging scans revealed a hyperintense signal in the midbrain with extension into the diencephalon. A cerebral angiogram performed at that time to exclude vasculitis revealed normal cerebral vasculature. The patient was treated with corticosteroids, and symptoms resolved. Subsequently, at the age of 32, this patient presented with a severe headache and emesis, but with no focal neurological deficit.

INTERVENTION: The patient's cranial computed tomographic and magnetic resonance imaging scans revealed a right posterior temporal intraparenchymal hemorrhage, and cerebral angiography revealed a new 3- by 2-cm AVM. The patient underwent microsurgical resection of the AVM and associated hematoma. Postoperative angiography revealed no evidence of residual AVM.

CONCLUSION: This study details the case of a woman who developed a de novo cerebral AVM during a 6-year period. This report challenges the conventional belief that all AVMs have a congenital cause.

(Neurosurgery 50:1137–1141, 2002)

Key words: Acquired arteriovenous malformation, Angiogenesis, Cerebral arteriovenous malformation

Intracranial arteriovenous malformations (AVMs), by definition, anatomically lack a capillary bed but demonstrate an arterial nidus, distinguishing them from pure arteriovenous fistulae (20). AVMs, however, may incorporate high-flow arteriovenous shunting through one or more direct fistulae. The annual risk of hemorrhage in cerebral AVMs is 2 to 4% (31), but it can be as high as 18% with previous hemorrhage (19). The accepted congenital cause of AVMs has been questioned (26, 27). Although it is conceivable that some

AVMs have an underlying developmental derangement, many correlations suggest that this may not be true for all of them (17, 21, 27). To our knowledge, this is the first report of an angiographically proven de novo intracranial AVM in an adult patient without previous vascular abnormality.

CASE REPORT

A 26-year-old African-American woman developed intermittent monocular vision loss and progressive ataxia

several days after developing a severe streptococcal throat infection. The patient used amphetamines chronically for weight reduction. Two weeks after her initial presentation, she developed diplopia, ptosis, blurred vision, slurred speech, and difficulty walking. The patient was hospitalized with an acute delirium and multifocal neurological deficits. Most of the deficits, except the ataxia, cleared spontaneously.

When she presented to our institution, she was alert and oriented. Visual fields were full, and visual acuity was 20/20 bilaterally. Results of the funduscopic examination were unremarkable. There was left beating nystagmus in the primary gaze position; however, extraocular movements were full. All other cranial nerves were intact. There was a left pronator drift with 4/5 strength on her right side. Occasional myoclonic jerks were noted. A sensory examination revealed nothing abnormal. The patient displayed mild evidence of limb dysmetria and severe gait ataxia. T2-weighted magnetic resonance imaging scans revealed a hyperintense signal in the midbrain (Fig. 1A) that extended to the diencephalon and left temporal lobe; however, no evidence of hemorrhage or of right temporal cortical or subcortical lesions was observed (Fig. 1B).

Analysis of cerebrospinal fluid obtained via lumbar puncture revealed a pressure of 14.5 cm H₂O with a glucose level of 53 mg/dl, protein level of 45 mg/dl, 38 nucleated cells/mm³ (13% granulocytes and 78% lymphocytes), and 88 red blood cells/mm³. Gram's stain and other infectious disease assays disclosed nothing abnormal. Weak oligoclonal bands were detected. A three-vessel cerebral angiogram revealed normal cerebral vasculature (Fig. 2, A and B). A brain positron emission tomographic scan revealed hypometabolism in the brainstem and diencephalon suggestive of an inflammatory or demyelinating lesion. The patient was treated with methylprednisolone (1.0 g/d) for 5 days, then tapered via orally administered corticosteroids. Over the course of

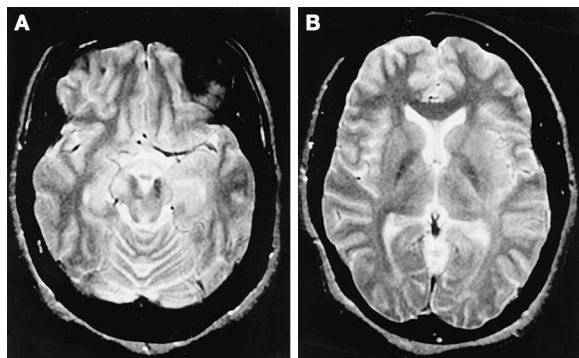


FIGURE 1. Axial T2-weighted magnetic resonance imaging scans, obtained at the initial presentation of the patient, demonstrating hyperintense signal in the brainstem and diencephalon (A). There is no evidence of a right posterior temporal vascular lesion (B).

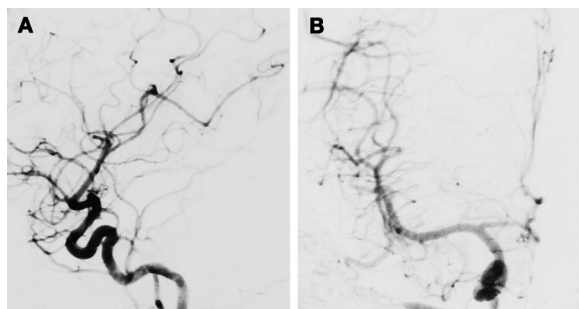


FIGURE 2. Lateral (A) and anteroposterior (B) cerebral angiograms of the right carotid artery, obtained at the initial presentation of the patient, revealing no evidence of vasculitis, aneurysm, or vascular malformation.

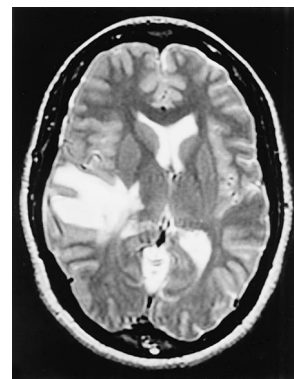


FIGURE 3. Axial magnetic resonance imaging scan of the brain, obtained approximately 6 years after the initial presentation, demonstrating a new right posterior temporal intraparenchymal hemorrhage.

several weeks, the majority of her symptoms resolved, and thereafter, she remained neurologically well.

Six years later, at the age of 32, the patient presented to the emergency room with what she characterized as the worst headache of her life; it was associated with nausea and vomiting. No associated focal neurological deficit was present.

The patient's cranial computed tomographic and subsequent magnetic resonance imaging scans (Fig. 3) revealed a right posterior temporal intraparenchymal hemorrhage. Cerebral angiography revealed a new 3- by 2-cm right posterior temporal AVM fed exclusively by the right middle cerebral artery; its primary drainage was via the vein of Labbé (Fig. 4, A and B). There was no evidence of deep venous drainage. The patient was taken to the operating room, where she underwent a right temporal craniotomy. Three-dimensional image guidance was used to localize the AVM, which did not present directly to the pial surface. The AVM was resected via standard microsurgical techniques. Postoperative angiograms revealed no residual AVM (Fig. 5, A and B), and the patient displayed no postoperative neurological deficits.

DISCUSSION

To our knowledge, this is the first report of an angiographically proven de novo intracranial AVM in an adult patient who did not have a previous neurovascular abnormality. It challenges the widespread belief that all AVMs have a congenital cause. Traditionally, AVMs are thought to arise between Weeks 4 and 8 of embryonic life (8). The primary pathological lesion consists of direct connections between arterial inflow and venous outflow without an intervening capillary bed. These malformations are most common in the distribution of the middle cerebral artery (8).

Unlike other congenital vascular malformations, such as vein of Galen malformations (3, 33), no cerebral AVMs have been detected in utero (27). This challenges the idea that all AVMs may arise from embryonic aberrations at the stage of vessel formation (23). Furthermore, no evidence exists to support the belief that AVMs arise during the late fetal period or immediate postpartum life (21, 27).

It is clear that not all vascular malformations have a congenital cause. Dural AVMs are acquired after sinus thrombosis (2, 10, 13, 16, 22) or spontaneously

(32). The senior author (MJA) previously described a de novo cerebral cavernous malformation that developed after radiation for a pituitary tumor (1). Likewise, de novo cavernous malformations of the spinal cord have been reported after spinal axis radiation (18).

The literature involving de novo cerebral AVMs is more sparse. Schmit et al. (26) reported an angiographically proven acquired cerebral AVM in a child with moyamoya disease occurring after cerebral infarction. Rodriguez-Arias et al. (24) reported recurrence of a cerebral AVM in a child in a different location after radiosurgery. More recently, local venous hypertension associated with a dural arteriovenous fistula was reported to be associated with a de novo cerebellar AVM (6).

An interesting associated question is whether AVMs with angiographically verified complete resection recur, or whether an undiagnosed residual AVM exists. Some reports have noted angiographic complete resection of cerebral AVMs with subsequent recurrence, particularly in children (7, 15). This calls into question whether a milieu of local cytokines promotes AVM development or growth.

Growing support argues that spinal AVMs can arise after trauma, inflammation, infection, or various compressive lesions (11). These processes stimulate angiogenesis (5). Potent angiogenic factors that are abundant in ischemic brain

FIGURE 4. Lateral (A) and anteroposterior (B) cerebral angiograms of the right internal carotid artery, obtained at the time of the second presentation, revealing a new AVM fed by the middle cerebral artery with superficial venous drainage.

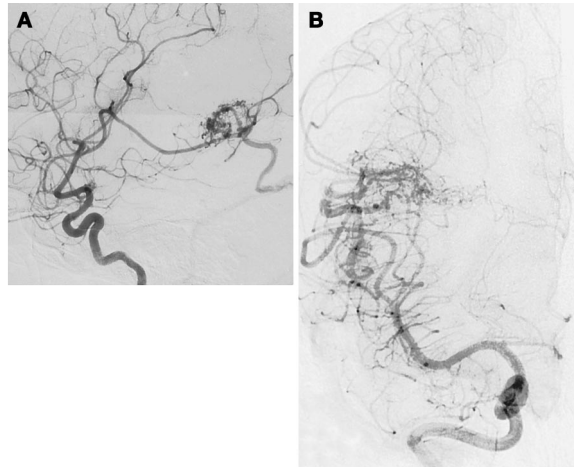
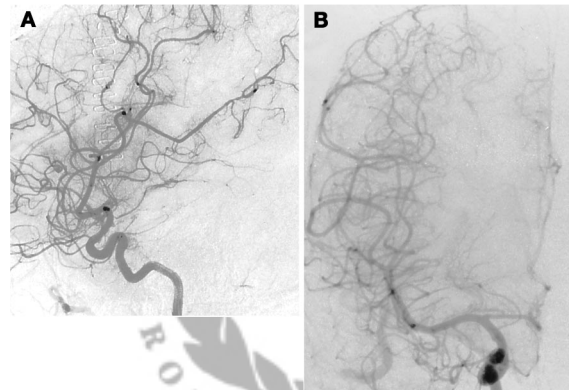


FIGURE 5. Postoperative (A) lateral and anteroposterior (B) cerebral angiograms of the right internal carotid artery revealing no residual AVM.



regions are vascular endothelial growth factor and basic fibroblast growth factor (4, 28). It has been proposed that overstimulated angiogenesis may lead to the development of AVMs (26, 28).

Our understanding of the genetics, pathogenesis, and evolution of AVMs is just beginning to develop. Germ-line mutations with or without environmental factors affecting common angiogenic pathways may underlie the pathophysiology of intracranial AVMs. Promising candidate proteins range from the endothelial angiopoietin receptor Tie-2 (9, 30), transforming growth factor β (12), nitric oxide synthase (14), vascular endothelial growth factor (28, 29), and fibroblast growth factor (25).

Sure et al. (28) have demonstrated immunohistochemical staining for proliferating cell nuclear antigen, MIB-1, vascular endothelial growth factor, and its receptor FLK-1 in the endothelium of AVMs. This implies neoangiogenesis and endothelial proliferation. Furthermore, increased neoangiogenesis has

been observed in partially treated AVMs (29). The relative role of the environment in the development of these lesions is not known, but as in the patient we describe here, environmental factors may play a significant role in their development.

Whatever the initial mechanism, the increasing hemodynamic stress in the affected vessels may cause further vascular remodeling and secondary vascular changes. This may lead to AVM maturation. Understanding the underlying cause of AVMs may provide critical insights into potential therapeutic management.

CONCLUSIONS

The pathogenesis of cerebral AVMs is not fully understood, but the accepted congenital cause of these lesions has recently been questioned. To our knowledge, this is the first demonstration of an angiographically proven de novo cerebral AVM in a patient angiographi-

cally documented not to have a previous cerebrovascular abnormality. It provides further evidence that not all cerebral AVMs have a congenital cause.

Received, July 3, 2001.

Accepted, August 27, 2001.

Reprint requests: Michael J. Alexander, M.D., Division of Neurosurgery, Duke University Medical Center, 4505 Busse Building, Duke South, Durham, NC 27710.

Email: michael.alexander@duke.edu

REFERENCES

- Alexander MJ, DeSalles AA, Tomiyasu U: Multiple radiation-induced intracranial lesions after treatment for pituitary adenoma: Case report. *J Neurosurg* 88:111-115, 1998.
- Awad IA, Little JR, Akarawi WP, Ahl J: Intracranial dural arteriovenous malformations: Factors predisposing to an aggressive neurological course. *J Neurosurg* 72:839-850, 1990.
- Campi A, Scotti G, Filippi M, Gerevini S, Strigini F, Lasjaunias P: Antenatal diagnosis of vein of Galen aneurysmal malformation: MR study of fetal brain and postnatal follow-up. *Neuroradiology* 38:87-90, 1996.
- Chen HH, Chien CH, Liu HM: Correlation between angiogenesis and basic fibroblast growth factor expression in experimental brain infarct. *Stroke* 25:1651-1657, 1994.
- Folkman J, Klagsbrun M: Angiogenic factors. *Science* 235:442-447, 1987.
- Friedman JA, Pollock BE, Nichols DA: Development of a cerebral arteriovenous malformation in an adult documented by serial angiography. Presented at the AANS Meeting, Toronto, April 21-26, 2001, p 71 (abstr).
- Gabriel EM, Sampson JH, Wilkins RH: Recurrence of a cerebral arteriovenous malformation after surgical excision: Case report. *J Neurosurg* 84:879-882, 1996.
- Garretson HD: Intracranial arteriovenous malformations, in Wilkins RH, Rengachary SS (eds): *Neurosurgery*. New York, McGraw-Hill, 1996, pp 2433-2442.
- Hatva E, Jääskeläinen J, Hirvonen H, Alitalo K, Haltia M: Tie endothelial cell-specific receptor tyrosine kinase is upregulated in the vasculature of arteriovenous malformations. *J Neuropathol Exp Neurol* 55:1124-1133, 1996.
- Herman JM, Spetzler RF, Bederson JB, Kurbat JM, Zabramski JM: Genesis of a dural arteriovenous malformation in a rat model. *J Neurosurg* 83:539-545, 1995.
- Hida K, Iwasaki Y, Isu T, Akino M, Abe H, Tashiro K, Yoshida K, Miyasaka K, Takei H, Abe S: Spinal dural AVM: Report of three cases [in Japanese]. *No Shinkei Geka* 14:361-366, 1986.
- Hirschi KK, Rohovsky SA, D'Amore PA: PDGF, TGF- β , and heterotypic cell-cell interactions mediate endothelial cell-induced recruitment of 10T1/2 cells and their differentiation to a smooth muscle fate. *J Cell Biol* 141:805-814, 1998.

13. Houser OW, Campbell JK, Campbell RJ, Sundt TM Jr: Arteriovenous malformation affecting the transverse dural venous sinus: An acquired lesion. *Mayo Clin Proc* 54:651-661, 1979.
14. Joshi S, Young WL, Pile-Spellman J, Fogarty-Mack P, Sciacca RR, Hacin-Bey L, Duong H, Vulliamoz Y, Ostapkovich N, Jackson T: Intrarterial nitrovasodilators do not increase cerebral blood flow in angiographically normal territories of arteriovenous malformation patients. *Stroke* 28:1115-1122, 1997.
15. Kader A, Goodrich JT, Sonstein WJ, Stein BM, Carmel PW, Michelsen WJ: Recurrent cerebral arteriovenous malformations after negative postoperative angiograms. *J Neurosurg* 85:14-18, 1996.
16. Lawton MT, Jacobowitz R, Spetzler RF: Redefined role of angiogenesis in the pathogenesis of dural arteriovenous malformations. *J Neurosurg* 87:267-274, 1997.
17. Lazar RM, Connaire K, Marshall RS, Pile-Spellman J, Hacin-Bey L, Solomon RA, Sisti MB, Young WL, Mohr JP: Developmental deficits in adult patients with arteriovenous malformations. *Arch Neurol* 56:103-106, 1999.
18. Maraire JN, Abdulrauf SI, Berger S, Knisely J, Awad IA: De novo development of a cavernous malformation of the spinal cord following spinal axis radiation: Case report. *J Neurosurg* 90:234-238, 1999.
19. Mast H, Young WL, Koennecke HC, Sciacca RR, Osipov A, Pile-Spellman J, Hacin-Bey L, Duong H, Stein BM, Mohr JP: Risk of spontaneous haemorrhage after diagnosis of cerebral arteriovenous malformation. *Lancet* 350:1065-1068, 1997.
20. Mohr JP, Stein BM, Pile-Spellman J: Arteriovenous malformations, in Barnett JM, Mohr JP, Stein BM, Yatsu FM (eds): *Stroke, Pathophysiology, Diagnosis and Management*. Philadelphia, Churchill Livingstone, 1998, pp 725-750.
21. Nelson MD Jr, Gonzalez-Gomez I, Gilles FH: Dyke Award: The search for human telencephalic ventriculofugal arteries. *AJNR Am J Neuroradiol* 12:215-222, 1991.
22. Ozawa T, Miyasaka Y, Tanaka R, Kurata A, Fujii K: Dural-pial arteriovenous malformation after sinus thrombosis. *Stroke* 29:1721-1724, 1998.
23. Padget DH: The cranial venous system in man in reference to development, adult configuration, and relation to the arteries. *Am J Anat* 98:307-355, 1956.
24. Rodriguez-Arias C, Martinez R, Rey G, Bravo G: Recurrence in a different location of a cerebral arteriovenous malformation in a child after radiosurgery. *Childs Nerv Syst* 16:363-365, 2000.
25. Rothbart D, Awad IA, Lee J, Kim J, Harbaugh R, Criscuolo GR: Expression of angiogenic factors and structural proteins in central nervous system vascular malformations. *Neurosurgery* 38:915-925, 1996.
26. Schmit BP, Burrows PE, Kuban K, Goumnerova L, Scott RM: Acquired cerebral arteriovenous malformation in a child with moyamoya disease. *J Neurosurg* 84:677-680, 1996.
27. Stapf C, Mohr JP: New concepts in adult brain arteriovenous malformations. *Curr Opin Neurol* 13:63-67, 2000.
28. Sure U, Butz N, Schlegel J, Siegel AM, Wakat JP, Mennel HD, Bien S, Bertalanffy H: Endothelial proliferation, neoangiogenesis, and potential de novo generation of cerebrovascular malformations. *J Neurosurg* 94:972-977, 2001.
29. Sure U, Butz N, Siegel AM, Mennel HD, Bien S, Bertalanffy H: Treatment-induced neoangiogenesis in cerebral arteriovenous malformations. *Clin Neurol Neurosurg* 103:29-32, 2001.
30. Vikkula M, Boon LM, Carraway KL III, Calvert JT, Diamonti AJ, Goumnerov B, Pasyk KA, Marchuk DA, Warman ML, Cantley LC, Mulliken JB, Olsen BR: Vascular dysmorphogenesis caused by an activating mutation in the receptor tyrosine kinase TIE2. *Cell* 87:1181-1190, 1996.
31. Wilkins RH: Natural history of intracranial vascular malformations: A review. *Neurosurgery* 16:421-430, 1985.
32. Yoshino O, Matsui H, Hirano N, Tsuji H: Acquired dural arteriovenous malformations of the lumbar spine: Case report. *Neurosurgery* 42:1387-1389, 1998.
33. Yuval Y, Lerner A, Lipitz S, Rotstein Z, Hegesh J, Achiron R: Prenatal diagnosis of vein of Galen aneurysmal malformation: Report of two cases with proposal for prognostic indices. *Prenat Diagn* 17:972-977, 1997.

COMMENTS

Bulsara et al. describe an interesting case that seems to demonstrate de novo formation of a cerebral arteriovenous malformation (AVM). Over the years, numerous examples have been set forth to demonstrate de novo formation of a variety of different types of vascular malformations. This is an interesting topic because such cases potentially provide insight into the pathogenesis of these various lesions. I found the angiograms presented as *Figure 4* to be most interesting. The anteroposterior view in particular demonstrates the loose and delicate nidus pattern that I typically associate with AVMs in children. It seems that the classic adult AVM generally has a much more dense or compact nidus. This distinction between childhood and adult AVMs has been made by many clinicians over the years, and I would currently characterize it as part of the conventional wisdom regarding AVMs. Significantly, the current example bears a strong resemblance to what we might consider a juvenile AVM, although here, it appears in an adult. Given this observation, I am particularly disappointed that we have so little information regarding the intraoperative appearance of the AVM—and in particular, we are provided no information regarding

the histological examination of the malformation.

I must question the assertion of Bulsara et al. that the original angiogram is completely normal. If one looks closely at their *Figure 4A*, observing the lateral projection that demonstrates the malformation and then mentally superimposing the malformation onto their *Figure 2A*, the initial lateral projection, one can observe a faint silhouette of the lesion on the original study. I can observe no such faint silhouette on the anteroposterior projections. I suspect that this is because the malformation is essentially tubular. The lesion is so faint on the original films that only when viewing it down its long axis can one appreciate the faint blush.

If the lesion was present 6 years earlier but was simply extremely faint on radiographic scans, what does this mean? I suspect that all AVMs undergo remodeling over the years. Although numerous stimuli for such remodeling probably exist, I would suspect that hemodynamic forces are dominant, and among these, I would conjecture that shear force at the level of the endothelial wall is the most critical. It seems reasonable to think that this type of dynamic remodeling over time is what turns the delicate, loose juvenile AVM into a more dense, compact AVM in adults. It is conceivable that some early lesions move in the opposite direction and actually regress over time. Obviously, this remodeling does not occur by magic; it is most likely the result of local release of angiogenic factors. A fundamental question is whether such a dynamic remodeling process can occur within a totally normal vascular bed, or whether some congenital abnormality of the infrastructure must be present to promote such remodeling. I submit that, in the current case, we have angiographic evidence, although subtle, that an abnormality did exist before the patient's presentation at age 32.

Robert E. Breeze
Denver, Colorado

In this fascinating case report, Bulsara et al. describe a case of de novo formation of a small right temporal AVM in a woman who had had a documented ce-

rebral angiogram that displayed nothing abnormal 6 years earlier. This finding obviously challenges the prevalent existing theories that pial AVMs arise from an abnormality in embryological cerebrovascular development, and it raises the possibility that at least some pial AVMs arise later in life, perhaps as a consequence of environmental or genetic factors in a manner analogous to dural AVMs or cavernous hemangiomas.

Robert Replogle
Duke S. Samson
Dallas, Texas

Bulsara et al. provide excellent detail and analysis in a novel observation. This patient clearly experienced an episode of meningoencephalitis, which fortunately was investigated angiographically. Six years later, she bled from a de novo AVM. If one studies the original arteriogram carefully, on the lateral projection at the precise site that the new AVM developed, one sees a slight increase in vascularity. There is certainly no shunting, but in retrospect, there is possibly an apparent angiographic abnormality. The authors' discussion and review of the literature are insightful and provocative. I am aware of two children in my own practice whose

postoperative angiograms revealed nothing abnormal but who bled several years later from a new AVM. In both of these cases, the new AVM was in the general area of the original lesion. Nevertheless, the potential for focal hyperangiogenesis driven by any number of potential mechanisms could conceivably create AVMs in adults. I suspect that this case report will prompt all neurosurgeons to follow their posttreatment AVM patients a little more carefully.

H. Hunt Batjer
Chicago, Illinois

This seminal case report will likely be cited for years to come. Although de novo genesis of cavernous malformations and dural AVMs has been well documented, there has been no equally convincing documentation in a cerebral AVM. Yet the progression of these lesions and occasional spontaneous resolution have been reported, suggesting dynamic angiogenesis within these lesions. Recurrence of AVMs after documented and verified excision has also been reported. With this careful case report by Bulsara et al., we now have convincing evidence of de novo genesis of a typical cerebral AVM in an adult patient

who did not harbor such a lesion a few years earlier.

The appearance of the cerebral AVM in this patient is characteristic of a diffuse, lacy nidus, reminiscent of AVMs in children. Perhaps the AVM nidus becomes more compact as it matures and as progressive ischemia and gliosis replace the brain tissue intervening between the vascular channels. Because this lesion was not embolized preoperatively, it would be helpful to examine it histologically in some detail, in comparison to the more conventional AVM abnormality. Also, the resolution of the various imaging modalities does not preclude the possibility of a preexisting occult vascular anomaly, which then evolved into full-blown AVM. The likelihood of activated angiogenesis in association with the patient's previous illness leads to other speculations regarding contributing factors that may have triggered this unusual event. As a result of this case report and other carefully documented observations, new hypotheses will be formulated regarding the pathogenesis of cerebral AVMs.

Issam A. Awad
Denver, Colorado

Special Note on Color Figures

To all authors who submit manuscripts to *NEUROSURGERY* that include color figures: Please be aware of the following policy of *NEUROSURGERY*, which is also printed in the Information for Contributors:

Figures that are submitted in color are automatically published in color, and authors will be responsible for the costs (typically \$1200-2000 per article) of any color reproductions. Authors who subsequently want their color figures published in black and white will be billed for the color processing costs (typically \$300-500 per article). Authors are responsible for costs incurred to retouch or correct submitted illustrations.

Special Note on Pathology Figures—With all histopathology, and in particular immunohistochemistry illustrations, color is preferred.

Thank you for your cooperation in helping us maintain the high scientific quality of *NEUROSURGERY*.