

BRIEF REPORT

Chih-Chong Lin · Chun-Chung Lui · You-Lin Tain

Thalamic stroke secondary to straight sinus thrombosis in a nephrotic child

Received: 25 June 2001 / Revised: 6 September 2001 / Accepted: 12 October 2001

Abstract A 7-year-old Chinese boy with steroid-resistant nephrotic syndrome developed thalamic stroke secondary to straight sinus thrombosis. He was hospitalized due to status epilepticus and coma. The child recovered after treatment by low-molecular-weight heparin (LMWH) and warfarin. This case highlights the importance of magnetic resonance imaging with venography in the early diagnosis of cerebral sinus thrombosis (CST) in nephrotic children and the effectiveness of anticoagulation therapy in improving the neurological outcome.

Keywords Nephrotic syndrome · Cerebral sinus thrombosis · Thalamic stroke · Magnetic resonance imaging with venography · Low-molecular-weight heparin

Introduction

Cerebral sinus thrombosis (CST) is a rare complication in children with nephrotic syndrome (NS) [1]. To our knowledge, only three cases have been published to date [2–4]. We present our successful experience in treating a nephrotic child complicated with thalamic stroke secondary to straight sinus thrombosis by low-molecular-weight heparin (LMWH).

C.-C. Lin · C.-C. Lui · Y.-L. Tain (✉)
Department of Pediatrics, Division of Pediatric Nephrology,
Chang Gung Memorial Hospital at Kaohsiung, 123 Ta-Pei Road,
Niao-Sung Hsiang, Kaohsiung Hsien, Taiwan, Republic of China
e-mail: tainyl@seed.net.tw
Tel.: +886-7-7317123, Fax: +886-7-7338009

C.-C. Lui
Department of Diagnostic Radiology,
Division of Pediatric Nephrology,
Chang Gung Memorial Hospital at Kaohsiung,
Taiwan, Republic of China

Case report

A 7-year-old Chinese boy, with a 2-year history of steroid-resistant nephrotic syndrome (SRNS), presented with coma and status epilepticus after a bout of severe headache. In 1998 he was sent to our hospital for generalized edema for the first time. Routine prednisolone treatment was given. As it failed to induce remission, the diagnosis of SRNS was made. We suggested a renal biopsy, but the family refused. He required several hospitalizations for severe edema, and received one course of oral cyclosporin for 4 months. He was discharged just 1 day before this admission. During the previous hospital stay, a 5-day albumin plus furosemide daily infusion ameliorated his edema, and the daily urine output was up to 1.5 l/m² BSA/day. He was thus discharged and oral prednisolone was continued. This time, he was sent to our hospital due to generalized tonic-clonic convulsion. On arrival, body temperature was 38.8°C, heart rate 217 beats/min, respiratory rate 25/min with occasional apnea, and blood pressure 186/148 mmHg. Body weight was 40 kg. The pupils were isocoric with intact light reflex. Fundoscopic examination showed mild papilledema. Motor examination revealed he was not responsive to pain. Neither pitting edema nor decreased skin turgor was noted on physical examination. Admission laboratory tests were all unremarkable with the exception of albumin 1.8 g%, total cholesterol 291 mg/dl, triglyceride 223 mg/dl and a daily protein loss of 340 mg/kg/day. Septic workups revealed negative results.

On admission, mechanical ventilation and phenobarbital (10 mg/kg) were initiated. Infusion of albumin (0.5 g/kg) with furosemide (1 mg/kg) was given daily for 1 week. Oral prednisolone (1 mg/kg/day) was continued. Brain computed tomography (CT) was performed. No intracranial hemorrhage, space-occupying lesion or sulci effacement was found.

On the third hospital day, the endotracheal tube was removed. However, he made slow progress in conscious status and motor function. On the fifth hospital day, magnetic resonance imaging (MRI) with MR venography (MRV) was obtained to rule out CST. The MRI revealed hyperintensity in thalamus bilaterally, hippocampus bilaterally and right occipital area on T2-weighted and diffusion-weighted image (not shown) and the MRV disclosed a filling defect in straight sinus (Fig. 1a). The coagulation studies showed a prothrombin time (PT) of 11.4/9.2 s, an activated partial thrombin time of 39.7/30.8 s, a protein C of 135% of the control and a protein S of 125% of the control.

LMWH (nadroparin, Sanofi-Winthrop, France) at the dose of 90 U/kg/day subcutaneously was applied for CST on the fifth hospital day and was continued for 2 weeks. On the 15th hospital day the follow-up MRI with MRV revealed a patent straight sinus (Fig. 1b). On the 16th hospital day unremarkable EEG was obtained. Warfarin was prescribed at the initial dose of 0.125 mg/kg/day and was titrated by monitoring PT levels for the next 3 months. He was dis-

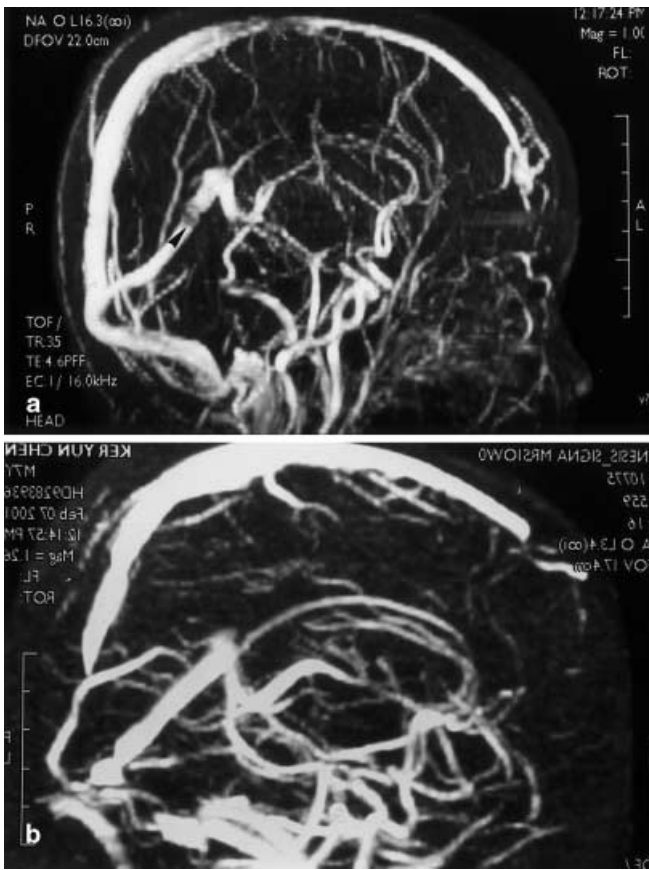


Fig. 1 **a** Brain 2D time-of-flight magnetic resonance venography (MRV) shows a filling defect (arrowhead) in the straight sinus on the fifth hospital day. **b** Brain MRV shows a patent straight sinus on the 15th hospital day

charged on the 30th hospital day and the residual neurological problems included flat affect and mutism.

Three months later, he was well except for regressive self-care abilities and speech problems. He made slow progress, transiting from mutism, echolalia to simple sentences. Long-term rehabilitation was required. The dosage of prednisolone was tapered after clinical improvement.

Discussion

The incidence of thromboembolic complications in children with NS is 2% [1]. The most commonly affected vessels are deep leg veins, followed by inferior vena cava, renal vein and pulmonary vessels. Cerebral vessels are rarely involved [2–4].

The predisposing factors for CST and thalamic stroke are infection, coagulation disorders, severe dehydration, nephrotic syndrome and space-occupying lesions [5]. Brain CT was entirely normal in 10–20% of cases with CST. MRI with MRV is more sensitive and has largely replaced angiography and brain CT in detecting CST [5, 6]. In this case, the brain CT was unremarkable. He underwent MRI with MRV due to the high suspicion of CST. MRI with MRV revealed widespread hyperinten-

sive areas, and a filling defect in the straight sinus (Fig. 1a). The areas of increased intensity involving cortex and suggesting edema or infarct could partially explain the status epilepticus. Due to lack of collateral circulations of the deep cerebral sinus, thrombosis of the straight sinus led to drainage failure of the tributaries of internal cerebral veins, including the thalamostriate veins. Venous ischemia of thalamus ensued. Neuropathologically, paramedian thalamic infarcts may be associated with mutism [7]. In our case, the venous infarction might partially explain the clinical manifestations [8]. To our knowledge, this is the first case in a nephrotic child where altered mental status could be attributed to thalamic stroke.

The patient suffered straight sinus thrombosis during relapse. In response to massive proteinuria, hepatic synthesis of coagulation inhibitors increases, and the plasma levels of these proteins are the sum of loss and gain. The coagulant inhibitors can be divided into two groups, protein C and its activator protein S on the one hand and antithrombin on the other. The consensus was that during relapse abrupt urinary loss of antithrombin leads to decreased antithrombin level. Decreased antithrombin level may be a major factor in the hypercoagulability status and attributed to venous thrombosis. During relapse of NS, an increase in the concentrations of protein C ($148 \pm 59\%$) and protein S ($109 \pm 41\%$) were reported in steroid-resistant nephrotic children [9]; in contrast, a deficiency of protein C and protein S was reported in cases of CST [5]. As we missed his antithrombin level in the initial coagulation study, we could not ascertain its actual role in this patient. In this case, the levels of protein C and protein S were mildly elevated (135% for protein C, 125% for protein S). The profile of protein C and protein S is similar to that of SRNS in relapse rather than to that of the general population with CST. Further studies are necessary to determine whether higher or lower levels of protein C and protein S are related to the risk of CST in NS.

When compared with unfractional heparin, LMWH has a more predictable anticoagulant response [10]. A higher anti-Xa to anti-IIa ratio is one of the identified primary determinants of the antithrombotic efficacy of LMWH. Successful treatment of CST in nephrotic children with enoxaparin was recently reported [4]. This patient was treated by nadroparin, which had a comparable anti-Xa to anti-IIa ratio to enoxaparin [10, 11]. The safety of LMWH in the treatment of CST in nephrotic children has been reported [12]. In addition to the conventional treatment modalities such as prevention of hypovolemia and antithrombin replacement, LMWH followed by warfarin undoubtedly plays a major role in the treatment of nephrotic children with CST.

There was no definite correlation between disease severity and outcome in CST [6]. It is suggested that for better prognosis early diagnosis and treatment is necessary. The boy sat up without support on day 9 and walked with support on day 12. He giggled when tickled on day 20. He made great progress after treatment with

LMWH and warfarin. Besides, prevention is better than treatment. This patient contracted CST in relapse, and it was close to a course of 5-day albumin plus furosemide daily infusions. Therefore, during the relapse of NS, prudent use of diuretics, avoidance of infections and maintenance of albumin level are all useful preventive measures. This case provides us with an experience that MRI with MRV is the imaging modality of choice in nephrotic children when intracranial lesion is highly suspected, and that effective anticoagulation therapy might improve the neurological outcome. Nevertheless, large-scale randomized clinical trials are necessary before the routine use of LMWH in nephrotic children with CST is recommended.

Acknowledgements The authors thank Miss Shaw-Hwei Huang for pharmacological advice and Miss Yi-Jing Chen for secretarial assistance.

References

1. Lilova MI, Velkovski IG, Topalov IB (2000) Thromboembolic complications in children with nephrotic syndrome in Bulgaria (1974–1996). *Pediatr Nephrol* 15:74–78
2. Lau SO, Bock GH, Edson JR, Michael AF (1980) Sagittal sinus thrombosis in the nephrotic syndrome. *J Pediatr* 97:948–950
3. Divekar AA, Ali US, Ronghe MD, Singh AR, Dalvi RB (1996) Superior sagittal sinus thrombosis in a child with nephrotic syndrome. *Pediatr Nephrol* 10:206–207
4. De Saint-Martin A, Terzic J, Christmann D, Knab MC, Peter MO, Fischbach M (1997) Superior sagittal sinus thrombosis and nephrotic syndrome: favorable outcome with low-molecular-weight heparin. *Arch Pediatr* 4:849–852
5. Allroggen H, Abbott RJ (2000) Cerebral venous sinus thrombosis. *Postgrad Med J* 76:12–15
6. Ameri A, Bousser MG (1992) Cerebral venous thrombosis. *Neurol Clin* 10:87–111
7. Castaigne P, Lhermitte F, Buge A, Escourolle R, Hauw JJ, Lyon-Caen O (1981) Paramedian thalamic and midbrain infarcts: clinical and neuropathological study. *Ann Neurol* 10:127–148
8. Kothare SV, Ebb DH, Rosenberger PB, Buonanno F, Schaefer PW, Krishnamoorthy KS (1998) Acute confusion and mutism as a presentation of thalamic strokes secondary to deep cerebral venous thrombosis. *J Child Neurol* 13:300–303
9. Andre E, Voisin P, Andre JL, Briquel ME, Stoltz JF, Martinet N, Alexandre P (1994) Hemorheological and hemostatic parameters in children with nephrotic syndrome undergoing steroid therapy. *Nephron* 68:184–191
10. Weitz JI (1997) Low-molecular-weight heparin. *N Engl J Med* 337:688–698
11. Duplaga BA, Rivers CW, Nutescu E (2001) Dosing and monitoring of low-molecular-weight heparins in special populations. *Pharmacotherapy* 21:218–234
12. Dix D, Andrew M, Marzinotto V, Charpentier K, Bridge S, Monagle P, De Veber G, Leaker M, Chan KC, Massicotte MP (2000) The use of low-molecular-weight heparin in pediatric patients: a prospective cohort study. *J Pediatr* 136:439–445