

Case report

A case of acquired stuttering resulting from left parietal infarction

Turgut N, Utku U, Balci K. A case of acquired stuttering resulting from left parietal infarction.

Acta Neurol Scand 2002; 105: 408–410. © Blackwell Munksgaard 2002.

Objective – Acquired stuttering is uncommon, and is reported anecdotally after head injury and cerebrovascular diseases. Although this entity is described to occur in lesions of dominant hemisphere, it is rarely shown to occur in non-dominant hemispheric and subcortical lesions, too. Therefore we described a case with this rare syndrome and we discussed the possible mechanisms, lesion locations and medical treatment of stuttering according to previous reports. **Case report** – A 61-year-old right-handed man with sudden onset of right hemiparesia and stuttering without aphasia is reported. There was a circumscribed cortical infarction in the left parietal cortex on computerized tomography (CT) and magnetic resonance imaging (MRI) showed a recent infarct. Single photon emission computed tomography (SPECT) images evidenced perfusion abnormalities in the same region. He never stuttered before and has no family history of stuttering. He has been maintained on antiaggregant and paroxetine treatment. **Conclusion** – A rare presentation of stroke associated with stuttering is reported and the treatment of stuttering with paroxetine is discussed.

N. Turgut, U. Utku, K. Balci

Neurology Department, Medical Faculty, Trakya University, Edirne, Turkey

Key words: stroke; stuttering; therapy; paroxetine; neuroimaging

Ufuk Utku, Neurology Department, Medical Faculty, Trakya University, 22030 Edirne, Turkey

Tel.: +90 284 235 76 41

Fax: +90 284 235 76 52

e-mail: ufuk.utku@superonline.com

Presented in abstract form at the 9th European Stroke Conference, Vienna, Austria, 24–27 May 2000.

Accepted for publication October 12, 2001

Neurogenic (or acquired) stuttering is uncommon and is different in some aspects from the stuttering of developmental origin (1). Most reported cases of acquired stuttering are described as a result of stroke, head injury, degenerative and metabolic brain damage (1–3). The mechanisms and location of lesions in stuttering are poorly understood: stroke cases with stuttering have been described after dominant hemispheric lesions, and more rarely after lesions affecting the non-dominant hemispheric and various subcortical structures (2–7).

A rare case of stuttering secondary to parietal cortical infarction in the left cerebral hemisphere is reported and the treatment of stuttering with paroxetine is discussed.

Case report

A 61-year-old right-handed, hypertensive man was admitted to our hospital because of acute onset of right-sided weakness and speech disturbance since 2 days. On examination, there was a

mild hemiparesis and sensory loss in the face and upper limb on the right side. The patient exhibited severe stuttering characterized by multiple clonic monosyllabic repetitions and blocks (Table 1). Speech disturbance appeared mainly in initial syllables with repeated reading and adaptation effect was not noted. Dysarthria was not found. A more detailed investigation of the patient's speech was performed using the Gülhane Aphasia Test (GAT) and the Turkish version of the Boston Diagnostic Aphasia Examination (BDAE) (8). GAT is the modified form of the Mayo Clinic Aphasia Test and the BDAE, and is in use for clinical evaluation of language disorders throughout Turkey (9, 10). The patient's language modalities such as auditory and reading comprehension, naming on visual confrontation, repetition and writing were normal. He had no difficulty in obeying verbal commands. All in all, the patient exhibited stuttering with no aphasia. Severe stuttering extended to reading as well. The medical history revealed no episodes of stuttering

Table 1 Examples of the normal pronunciation and the patient's actual response

Target word	Patient's actual response
Geliyorum – I'm coming	Ge-ge-geliyorum
Sen – You	S-s-s-sen
Rapor – Report	Ra-ra-rapor

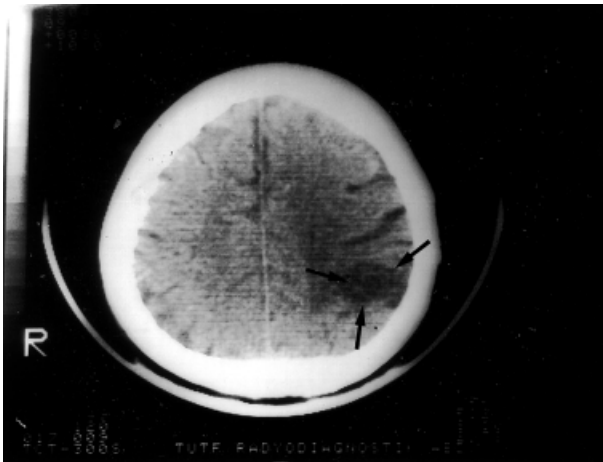

Figure 1. CT scan demonstrating hypodensity in the left parietal cortex, consistent with subacute infarction.

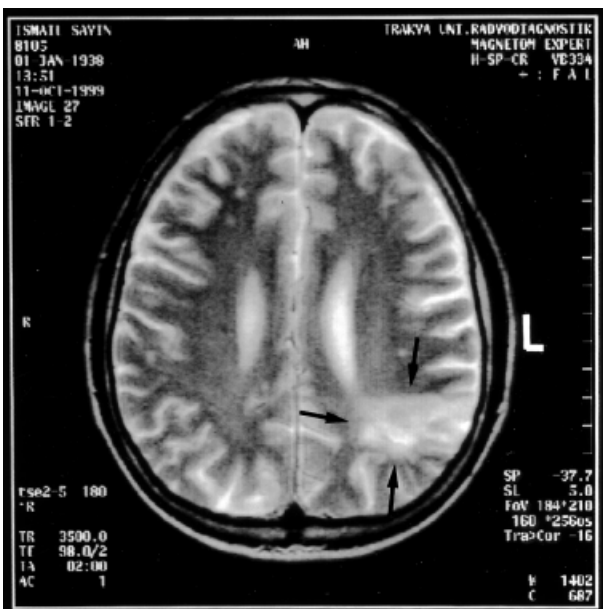


Figure 2. T2 weighted MRI showing left parietal cortical infarction.

either in the patient, or in his family. Computerized tomography (CT) scans obtained on the second day after the onset revealed an area of hypodensity in the left parietal cortex consistent with a subacute infarction (Fig. 1). Magnetic resonance imaging (MRI) scans taken on the

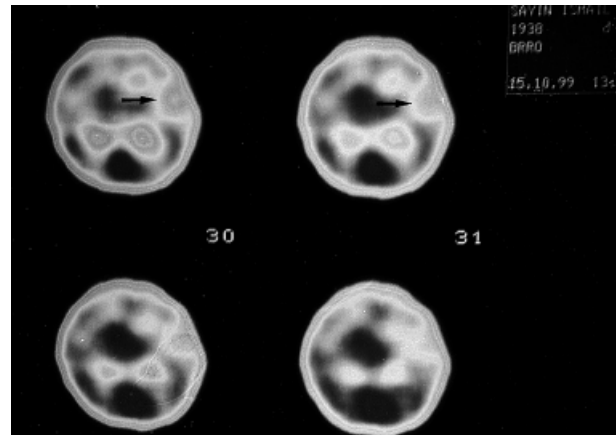


Figure 3. SPECT images revealing perfusion abnormalities in the left parietal area.

third day after the onset revealed a circumscribed cortical area of infarction in a similar location (Fig. 2). 99m Technetium hexamethylpropylene amine oxime (99mTc HMPAO) single photon emission computed tomography (SPECT) results were remarkable for perfusion abnormalities in the left parietal area (Fig. 3). Electrocardiogram (ECG) and echocardiogram were normal and extracranial Doppler ultrasonography (USG) revealed atherosclerotic plaques in the left internal carotid artery.

The patient was treated with antiaggregant therapy. After 1 week, no improvement was noted, and paroxetine (20 mg/day) was added. Within days, the patient's stuttering began to improve and at the end of 1 month, the stuttering was totally resolved.

Discussion

The acquired form of stuttering is different from the developmental form of stuttering (1). For example, in the acquired cases, stuttering can occur in monosyllabic as well as in longer words. It has no adaptation effect and is rarely associated with facial grimacing (3).

Acquired stuttering has been described more commonly in dominant parietal lobe lesions, as was seen in our patient. It has also been reported in lesions of the non-dominant hemisphere, thalamus, midbrain, pons, corona radiata and putamen (2–7). In those cases, stuttering was sometimes associated with a mild aphasia (1, 5). Although, our patient had a left parietal infarction, he had no aphasia. It is known that supplementary motor area (SMA) is important for coordinating and planning complex sequences of movement and this area receives information from the posterior parietal cortex (11). Therefore, the lesions of SMA or its connections with cerebral cortex and basal ganglia including

the extrapyramidal system are possible causes of stuttering (7, 12).

Interestingly, our case was improved after paroxetine treatment. Although a wide variety of medication has been used in the treatment of stuttering, only haloperidol treatment is reported to be effective (13). Schreiber et al. (14) showed that paroxetine (a phenyl-piperidine derivate, potent and selective serotonin reuptake blocker) was effective in three cases of acquired stuttering. It has been suggested that an interaction between serotonergic and dopaminergic systems exists in the forebrain and paroxetine may have a serotonin mediated indirect antidopaminergic effect in these patients.

To summarize, our case with stroke-induced stuttering is remarkable for his positive response to paroxetine treatment. However, the possible confounding of spontaneous recovery cannot be excluded and further studies are needed to examine the role of paroxetine in the treatment of this rare disorder.

References

1. GRANT AC, BIOUSSE V, COOK AA, NEWMAN NJ. Stroke-associated stuttering. *Arch Neurol* 1999;**56**:624–7.
2. SOROKER N, BAR-ISRAEL Y, SCHECHTER I, SOLZI P. Stuttering as a manifestation of right-hemispheric subcortical stroke. *Eur Neurol* 1990;**30**:268–70.
3. HELM NA, BUTLER RB, BENSON DF. Acquired stuttering. *Neurology* 1978;**28**:1159–65.
4. ROSENBEK J, MESSERT B, COLLINS M, WERTZ RT. Stuttering following brain damage. *Brain Lang* 1978;**6**:82–96.
5. CIABARRA AM, ELKIND MS, ROBERTS JK, MARSHALL RS. Subcortical infarction resulting in acquired stuttering. *J Neurol Neurosurg Psychiatry* 2000;**69**:546–9.
6. KONO I, HIRANO T, UEDA Y, NAKAJIMA K. A case of acquired stuttering resulting from striatocapsular infarction. *Rinsho Shinkeigaku* 1998; **38**:758–61.
7. ABE K, YOKOYAMA R, YORIFUJI S. Repetitive speech disorder resulting from infarcts in the paramedian thalamus and midbrain. *J Neurol Neurosurg Psychiatry* 1993; **56**:1024–6.
8. GOODGLASS H, KAPLAN E. Boston diagnostic aphasia examination. Philadelphia, PA: Lea & Febiger, 1972.
9. TANRIDAG O, ÖNGEL Ç. Transcortical motor aphasia due to a right hemisphere lesion in a right-handed man. *Aphasiology* 1989;**3**:717–21.
10. ÖZEREN A, SARICA Y, EFE R. Thalamic aphasia syndrome. *Acta Neurol Belg* 1994;**94**:205–8.
11. GHEZ C. The control of movement. In: KANDEL ER et al., eds. *Principles of neural science*. New York: Elsevier Science Publishing Co., 1991;539.
12. SAKAI T, MIYAMURA M, KUZUHARA S. Palilalia and acquired stuttering in a case of Parkinson's disease. *Rinsho Shinkeigaku* 1992; **32**:859–63.
13. BRADY JP. The pharmacology of stuttering: a critical review. *Am J Psychiatry* 1991;**148**:1309–16.
14. SCHREIBER S, PICK CG. Paroxetine for secondary stuttering: further interaction of serotonin and dopamine. *J Nerv Ment Dis* 1997; **185**:465–7.