



Note

Is autotopoagnosia real? EC says yes. A case study

C. Guariglia^{a,b,*}, L. Piccardi^a, M.C. Puglisi Allegra^a, M. Traballes^b^a Dipartimento di Psicologia, Università di Roma, "La Sapienza", Via dei Marsi, 78-00185 Rome, Italy^b IRCCS Fondazione Santa Lucia, Rome, Italy

Received 2 March 2001; received in revised form 17 December 2001; accepted 11 January 2002

Abstract

We report a case of pure autotopagnosia (AT) following a left subcortical vascular accident. The absence of any language disorder, general mental deterioration or other cognitive impairments in this patient allowed an in-depth study of AT. Several tests of body representation and object and animal representation, as well as tests assessing semantic skills were administered to verify current interpretations of AT. Results showed a clear-cut dissociation between defective performances in body representation tests and normal performances on tests involving other kinds of stimuli.

The patient's performances were particularly defective on tests relying on visuo-spatial body representation, but her semantic and linguistic knowledge seemed to be spared. This dissociation between different aspects of body representation supports Sirigu et al.'s hypothesis that multiple, partially independent systems are involved in body knowledge. In agreement with this hypothesis, in the present patient AT seems to be due to a deficit in a system that processes the structural properties and relative position of single body parts.

The present results, reporting the first observation of a subject not affected by any cognitive impairment other than AT, strongly support the existence of a system specifically devoted to body representation. © 2002 Elsevier Science Ltd. All rights reserved.

Keywords: Body representation; Body knowledge; Left hemisphere damage; Semantic deficit

1. Introduction

Autotopagnosia (AT) is the inability to localize body parts either on one's own body, on the examiner's body or in a picture. It is generally associated with a lesion of the left parietal lobe, often with a neoplastic etiology [7]. The most frequent errors are pointing to a contiguous body part or to one semantically related to the target [27]. A deficit is often observed in naming and in describing the functions of body parts [13,24,30] or in determining their spatial relationships [6].

Despite the clinical notoriety of AT, it is still not clear whether it is a specific disorder of a specific system devoted to body representation (i.e. body schema) or whether it is the consequence of other cognitive deficits. In fact, AT patients are frequently affected by other cognitive disorders, especially aphasia. The nature and severity of this latter disorder has influenced the interpretation of AT, so that it has been attributed either to a linguistic impairment [22,24,16,13,25] or to the inability to analyze a whole into its parts [9,11,23,30].

However, in the last 20 years some studies of single cases have been reported that attempted to determine whether a body schema defect or other cognitive deficits are respon-

sible for AT. Ogden [18] reported AT in a non-aphasic patient (JPB) with a left parietal lobe lesion, who also showed constructional apraxia, extra-personal and personal neglect, right-left confusion, finger agnosia and dressing apraxia. Ogden interpreted this case as due to loss of the ability to generate the body image. The mental imagery deficit was specific for body representation since, despite his inability to localize human body parts, JPB was still able to indicate single parts of animals and objects.

Semenza [26] described a similar case in a mild aphasic patient. Her localization deficit was body specific and she performed object part localization tests flawlessly.

Two more cases of AT were recently reported [8] with a dissociation between good naming, recognition and use of body parts and severe inability to localize the same parts on verbal command. In one patient (a left-handed man), the lesion was confined to the right parietal cortex and in the other one, to the left parietal cortex. Denes [8] argued that in these cases AT was due to the impairment of a specific neural circuit in the language dominant hemisphere that encodes both one's own and others' body position.

Also Buxbaum and Coslett [2] reported AT in a patient (GL) who showed lesions in the left frontal, temporal, parietal and occipital and in the right parietal lobes following a head injury. Transcortical motor aphasia and apraxia also

* Corresponding author. Tel.: +39-6-4991-7527; fax: +39-6-4451-667.
E-mail address: cecilia.guariglia@uniroma1.it (C. Guariglia).

affected GL, who required supervision and assistance in daily life activities involving his own body, such as grooming and dressing. A series of well designed experiments led Buxbaum and Coslett [2] to state that in this case AT was due to a deficit in a specific representation system that processes the structural descriptions of human bodies.

Some AT patients without linguistic defects are affected by dementia (i.e. [28]). In these cases, the presence of a general cognitive decline makes it difficult to assert that AT is due to the impairment of a specific system that represents the body as it appears, and the spatial relationship between its parts, even when it is a rather isolated deficit.

In the present paper, we report a new case of AT in EC, a patient who did not show any other cognitive impairment. Since no other case has been described up until now that shows such pure AT, we decided to further investigate this body schema impairment. In particular, we set out to determine whether AT is due to a more general impairment or to a specific deficit of a system specifically devoted to processing body representation and to verify present models of body representation.

Two different models propose that body representation is processed by multiple systems. Paillard [20] hypothesized that two different mechanisms process the “what” and “where” aspects of body representation. According to Paillard [20], a deficit in one of the two systems will impair the ability to perceptually identify body features in body images or to localize body parts, regardless of the task.

Instead, Sirigu et al. [28] hypothesized that four different systems, which may be selectively impaired by brain damage, process different aspects of body representation:

- (a) a semantic and lexical representation, involved in naming body parts and in recognizing their specific functional relations;
- (b) a category-specific, visuo-spatial representation, processing structural properties and position of single parts as well as their boundaries;
- (c) an emergent body-reference system, processing a dynamic, actual body image based on vestibular, somatosensory and visual inputs and
- (d) motor representation system.

EC’s performances on different body-involving tasks will help us understand whether body knowledge is processed by multiple representations.

2. Case report

EC, a 78-year-old, right-handed woman [19] with 3 years of schooling, suffered a left hemisphere stroke on 21 June 1999 and was admitted to the IRCCS Fondazione Santa Lucia on 31 January 2000.

CT scan (Fig. 1) showed a small lesion in the left white matter, involving the corona radiata. The neurological exami-

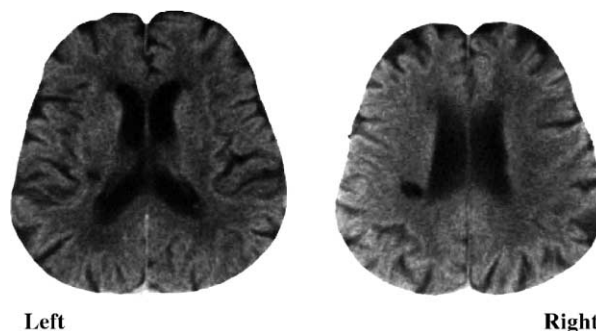


Fig. 1. EC’s CT scan evidences a small subcortical lesion confined to the left corona radiata.

nation revealed slight right-side hemiparesis, normal visual field and absence of somatosensory deficits.

EC was alert, cooperative and well oriented in space and time. A thorough neuropsychological examination including verbal and non verbal reasoning, apraxia, agnosia and visuo-spatial processing tests [29], as well as oral expression, auditory–verbal comprehension, reading and writing [3,10] failed to detect any cognitive impairment (see Table 1).

Despite the preservation of almost all of her cognitive skills and her intact ability to reach her own body parts in everyday life activities (i.e. dressing, washing, and putting on make-up, EC failed a test of body schema [27] in which she was unable to localize body parts on both verbal and non-verbal commands.

3. Test of AT

The localization of 18 body parts following verbal and non-verbal commands is required on this test. EC had to point to body parts on her own body, in a picture and on a multiple-choice response sheet following an oral, visual or tactile (the part to be indicated is touched while the patient is blindfolded) request [27].

EC failed on 18% of the items. This is a low, but significant percentage of errors since in their original paper Semenza and Goodglass [27] stated that performances of brain damaged patients not affected by body schema deficits were at ceiling. Furthermore, in a recent study a control group of elderly individuals not affected by any neurological impairment performed the test without error [21]. Following Semenza and Goodglass’s procedure, errors were grouped into three categories: conceptual (i.e. knee substituted for elbow); contiguous (i.e. knee substituted for thigh); random (i.e. knee substituted for nose). Contiguity errors were more frequent (72%) than conceptual (14%) and random (14%) errors. Errors were equally distributed over all conditions, except for the one in which the examiner pointed to parts of his own body and the patient, seated next to him, pointed to the same parts on her own body; in this condition she made no errors.

Table 1
EC's performances on neuropsychological tests assessing different cognitive domains (no performance was under cut-off)

Test	Score
Temporal orientation ^a	100/100
Spatial orientation ^a	100/100
Raven coloured PM ^b	27/36 (cut-off: 18)
Verbal judgements ^a	45/75 (cut-off: 33)
Digit span ^a	5 (cut-off: 3.75)
Episodic memory ^a	15 (cut-off: 8)
Verbal fluency (semantic) ^a	16 (cut-off: 9.5)
Bucco-facial apraxia ^a	20/20
Ideomotor apraxia ^c	72/72
Utilization apraxia ^c	90/90
Constructional apraxia ^a	10/14 (cut-off: 8)
Language examination [3]	
Oral expression	
Picture description	90%
Picture naming	100%
Action naming	100%
Oral comprehension	
Words	100%
Semantically related words	100%
Sentences	100%
Repetition	
Words	100%
Non-words	100%
Sentences	100%
Writing	
Word copying	100%
Word dictation	87.5%
Non-words dictation	90%
Sentence dictation	60%
Object naming	87.5%
Action naming	90%
Picture description	50%
Reading aloud	
Words	100%
Non-words	100%
Sentences	85%
Reading comprehension	
Words	100%
Sentences	90%
Token test	32 (cut-off: 29)

The neuropsychological assessment included only tests standardized for use with Italian-speaking patients.

^a [29].

^b [1].

^c [3].

4. Naming and pointing to parts of living and non-living objects

To rule out the possibility that a general deficit in pointing to parts of a whole, which may become evident when patients have to point to parts of animals or objects [9,11], is responsible for AT, a specific test was developed. Administration and scoring modalities were similar to those of the test of AT. This test requires localizing single parts on line drawings and toys, representing living (i.e. elephant,

horse, duck, rooster) and non-living (i.e. house, wagon, bicycle, car) stimuli following a verbal command or after a part has been shown on a drawing. Also, it requires pointing to the single part named or pointed to by the examiner on a multiple-choice sheet. On each sheet, four parts of the same stimulus (i.e. elephant) were depicted, one representing the target (i.e. an ear), one a contiguous part (i.e. a neck), one a conceptually related part (i.e. an eye) and one a part that was neither contiguous nor conceptually related (i.e. an anterior limb). EC was accurate (100% correct responses) and quick on all of these tasks and, at variance with previously reported patients [16], she made no errors in pointing to somatic elements in animal pictures.

5. Test of body schema

This test was developed for use with children [5]. However, it has already been used in studying body schema impairments in a brain damaged patient [15]. Test items include single tiles, each representing a part of the human body or the head. Two different views (frontal and lateral) are used in four sub-tests: frontal body, frontal head, lateral body, lateral head. For each sub-test, subjects are supplied with a test table on which the position of the head (for the body) or the contour of the face (for the head) is depicted. Using these references, subjects perform two different tasks:

- A. *Evocation*: Examiner gives a tile to the subject. After naming the part, the subject puts the tile on the table. Tile position is recorded on an answer sheet by overlapping the table with a transparent grid. Before presenting a new tile, the previous one is removed. This task specifically assesses the ability to generate mental images of the human body.
- B. *Construction*: All tiles necessary for constructing one of the four views are available to the subject. After the subject has completed the task, the examiner reports each tile position on the answer sheet.

In both lateral views, three tiles are presented for each item (lateral right, lateral left and frontal representation). The subject must choose the correct one.

EC's performance both on frontal and lateral views was very poor, corresponding to that of a 4–6-year-old child. She did not make any errors in naming single parts, but chose wrong parts for the lateral views. She also showed a severe deficit in all of the evocation tasks, which make more demands on the mental representation of the body than the construction tasks. In constructions, when she could check her production and therefore correct her errors, EC produced pictures similar to those of cubist artists (see Fig. 2).

In fact, when asked if she had finished and if she wanted to change anything, she always stated that her performance was complete and accurate, demonstrating she was unable to judge the oddity of her work.

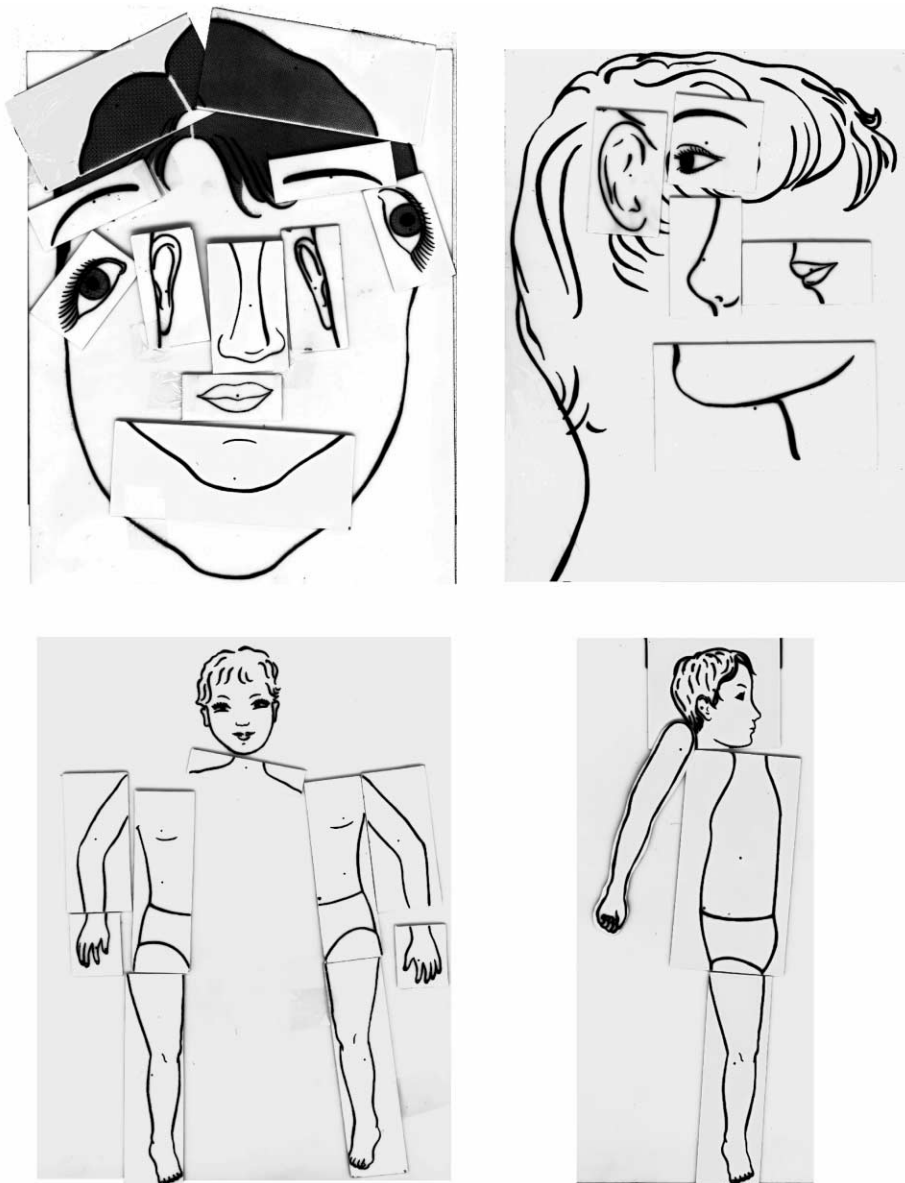


Fig. 2. EC's performances on Daurat-Hmeljiak et al.'s body schema test (1978): frontal (left) and lateral (right) view construction of the body (bottom) and the face (top).

6. Car test

This test was the same as the body representation test [5] with regard to presentation and response modalities, but used a no-body object. It was chosen because it has a clearly defined right and left-side. It included the evocation and construction of frontal and lateral views of a car; in lateral tasks, the subject chose the correct part from frontal, right and left lateral view tiles. On this test, EC's performance was amazingly correct. She made no errors in the lateral view and two errors in the frontal view construction, installing the wing mirrors in a vertical position, like those of a bus. This error was not surprising since EC never drove but frequently took the bus. In any case, her performance on this test did

not differ from those of five control subjects with no history or sign of neurological impairment, who sometimes made more serious errors than EC (for example, they reversed the headlights in the frontal view).

7. Category and modality-specific deficit?

AT has been considered a selective, category-specific deficit [14,30,31]. To verify this hypothesis, EC was administered a questionnaire [17] assessing semantic knowledge related to several living and non living categories, including body parts. The questionnaire investigates patients' knowledge of category membership of the target, its physical

appearance and functional properties (e.g. for the frog: is it an animal, a vegetable or an object? Is it an animal with four legs, a bird or an insect? Does it have a tail, horns or webbed feet? Is it bigger than a fox? Does it jump, run or walk? Does it live in a pond, on the beach or near rocks?). EC's performances were normal (score = 462/480 cut-off ≤ 447) and only one of her few errors regarded the body part category: when asked if an arm is longer than a leg, she answered: "Depending on the person" and soon after: "Perhaps the arm".

In order to further assess the patient's semantic knowledge of body parts, we asked EC to name 30 body parts following a verbal description obtained from a primary school dictionary (for example, for the thigh: part of lower limb situated between groin and knee). EC performed at ceiling on this task, but frequently commented: "I know what it is, but I'm unable to touch it" or, "I'm not sure I can point to it". Finally, at variance with previous patients [11], EC's verbal description of 29 body part positions was perfect.

Overall, these performances demonstrate that EC had intact semantic knowledge of body parts and of their localizations.

8. Mental imagery assessment

EC failed consistently whenever the task required generating a body visual image. She not only failed in the evocation tasks [5], but was also unable to correctly draw a human figure from memory. Her performance was slow and uncertain and as a result she produced a very stick-like figure (similar to the drawings of very small children). Therefore, it is possible that her AT derives from the derangement of a non specific visual mental imagery system [9,18].

EC was submitted to an imagery test [12] that included the following: color-object fluency task, mental color comparison test, brightness-saturation decision test and mental weight comparison test. EC's performance was flawless.

Also, she was at ceiling in generating mental images of living and non-living objects that she correctly drew from memory.

9. Discussion

Given the absolute absence of other cognitive impairments, EC provided a unique opportunity to settle some doubts about the nature of AT. These primarily concern the attribution of the deficit in locating body parts to the impairment of a system specifically devoted to processing body schema, or to the impairment of other cognitive systems involved in representing and localizing different categories of objects.

In fact, EC's AT could not be ascribed to the presence of a general impairment such as cognitive decay, since she had

no sign of mental deterioration. Nor could it be attributed to linguistic breakdowns, since she did not show any sign of even slight aphasic disorders in an extensive evaluation. Furthermore, no other neuropsychological deficit was detected in cognitive processes by formal examination with standard tests (i.e. reaching or visuo-spatial tests) that might affect localizing performances.

Also, in this patient AT could not be attributed to an impairment in analyzing a whole into its parts [9,11,23], because of her ceiling performances in pointing and singling out parts of both living and non-living objects.

Given these results, EC represents the first case in which AT is not associated with any other neuropsychological deficit and, therefore, the first case in which AT can be attributed, without any doubt, to the impairment of a system specifically devoted to representing body schema. This interpretation is supported by the results of the experimental testing EC was submitted to. In fact, she failed on the entire series of tests that required processing a body representation (positioning body parts, constructing a face or body from single parts and singling out parts from a complete picture), but never failed in analogous tests using living and non-living objects.

Since EC's deficit in localizing body parts is not associated with a deficit in naming or verbally describing semantic and functional attributes or the relative position of body parts, it is reasonable to interpret this deficit in terms of a multiple body representation model. Two models are currently available. According to the first model [20], two different body systems exist: a "where system" that processes the localization of body parts in a body schema and a "what system" that processes the perceptual identification of body features into a body image. In this view, EC's deficits should be attributed to selective damage of the "where system". In fact, her behavior is very similar to that of deafferented patients with defects of the where system, who were able to describe, but not point to, the body part where they were touched [4].

Or, EC's deficit might be explained by referring to Sirigu et al.'s [28] model. According to this model, body knowledge is processed by four different systems, each of which may be selectively damaged. Thus, EC's deficit should be attributed to a failure of the category-specific, visuo-spatial representation system. In fact, a failure of the semantic-lexical system would result in the inability to name and verbally describe functional and spatial properties of single features. On the other hand, damage to the emergent body-reference or to the motor representation systems would result in difficulty in using body representation in daily life activities.

Instead, selective damage to the category-specific, visuo-spatial representation system should not affect the possibility of naming, categorizing and verbally describing body parts, which EC is actually able to do. In fact, it should be underlined that while she correctly described the spatial position of single body parts, EC often commented "but I am not able

to touch it". Indeed, it should not affect daily life activities in which the reference to a body representation is needed. Instead, damage to the category-specific, visuo-spatial representation should result in poorer performances on the body schema test [5], since this system provides the visuo-spatial knowledge of both one's own and others' bodies. It should also affect the inability to point to single parts of one's own body, resulting mostly in contiguity errors (72%) on Semenza and Goodglass's test [27]. Performances on the latter test were less defective than might be expected. It is possible that EC developed a sort of compensatory strategy due to the absence of other cognitive impairments and the distance from onset. This strategy could be especially useful for body parts (for example, the hands) that are visually more defined and can be localized by referring only to visual information, as if they were parts of an object.

In conclusion, the present case supports the existence of a specific system for body representation, which is functionally independent from the systems involved in the representation of non-body objects. It also supports the hypothesis [20,4,28] that different systems process different aspects of body representation.

Concerning the anatomical correlates of such systems, patient EC, with specific damage in visuo-spatial representation, showed a very small subcortical lesion involving the corona radiata. It can be supposed that the lesion interrupted the connections between cortical areas involved in processing visuo-spatial body representation. However, other cases, and perhaps functional neuroimaging studies, are needed to clearly define body schema anatomical correlates.

Acknowledgements

Authors are grateful to EC for her kind collaboration. This research was supported by grants from Università di Roma "La Sapienza", CNR and Ministero della Sanità.

References

- [1] Basso A, Capitani E, Laiacona M. Raven's coloured progressive matrices: normative values on 305 adult normal controls. *Functional Neurology* 1987;2:189–94.
- [2] Buxbaum LJ, Coslett HB. Specialized structural descriptions for human body parts: evidence from autotopagnosia. *Cognitive Neuropsychology* 2001;18:289–306.
- [3] Ciurli P, Marangolo P, Basso A. *Esame del Linguaggio. Part 2. Organizzazioni Speciali*, Firenze, 1996.
- [4] Cole J, Paillard J. Living without touch and peripheral information about body position and movement: studies with deafferented subjects. In: Bermudez JL, Marcel A, Eilan N, editors. *The body and the self*. Cambridge: MIT Press, 1995. p. 245–66.
- [5] Daurat-Hmeljiak C, Stambak M, Berges J. Il test dello schema corporeo. Una prova di conoscenza e costruzione dell'immagine del corpo. *Organizzazioni Speciali*, Firenze, 1978.
- [6] Denes G. Disorders of body awareness and body knowledge. In: Boller F, Grafman J, editors. *Handbook of neuropsychology*, Vol. 2. Amsterdam: Elsevier, 1989. p. 207–27.
- [7] Denes G. Disorders of body awareness and body knowledge. In: Denes G, Pizzamiglio L, editors. *Handbook of clinical and experimental neuropsychology*. Hove: Psychology Press, 1999: 497–506.
- [8] Denes G, Cappelletti JY, Zilli T, Dalla Porta F, Gallana F. A category-specific deficit of spatial representation: the case of autotopagnosia. *Neuropsychologia* 2000;38:345–50.
- [9] De Renzi E, Faglioni P. L'autotopagnosia. *Archivio di Psicologia. Neurologia e Psichiatria* 1963;24:1–34.
- [10] De Renzi E, Faglioni P. Normative data and screening power of a shortened version of Token test. *Cortex* 1978;14:41–9.
- [11] De Renzi E, Scotti G. Autotopagnosia: fiction or reality? Report of a case. *Archives of Neurology* 1970;23:221–7.
- [12] De Vreese LP. Two systems for colour-naming defects: verbal disconnection versus colour imagery disorder. *Neuropsychologia* 1991;29:1–18.
- [13] Gainotti G, Caltagirone C, Carecchi A, Ibba A. Studio sperimentale dell'autotopagnosia. *Rivista di Patologia Nervosa e Mentale* 1976;97:97–114.
- [14] Goodglass H, Klein B, Carey P, Jones K. Specific semantic word categories in aphasia. *Cortex* 1966;2:74–89.
- [15] Guariglia C, Antonucci G. Personal and extra-personal space: a case of neglect dissociation. *Neuropsychologia* 1992;30:1001–9.
- [16] Hecaen H, Ajuriaguerra J. *Méconnaissances et hallucinations corporelles*. Masson, Paris, 1952.
- [17] Laiacona M, Barbarotto R, Trivelli C, Capitani E. Dissociazioni semantiche intercategoriale: descrizione di una batteria standardizzata e dati normativi. *Archivio Italiano di Psicologia. Neurologia e Psichiatria* 1993;54:209–48.
- [18] Ogden JA. Autotopagnosia: occurrence in a patient without nominal aphasia and with an intact ability to point to part of animals and objects. *Brain* 1985;108:1009–22.
- [19] Oldfield RC. The assessment and analysis of handedness: the Edinburgh inventory. *Neuropsychologia* 1971;9:97–113.
- [20] Paillard J. Le corps situé et le corps identifié: une approche psychophysiological de la notion de schema corporel. *Revue medicale de la Suisse Romande* 1980;100:129–41.
- [21] Piccardi L, Guariglia C, Puglisi Allegra MC, Committeri G. Alterazioni dello schema corporeo in pazienti cerebrolesi. *AIP, Alghero*, 2000.
- [22] Poock K, Orgass B. The concept of the body schema: a critical review and some experimental results. *Cortex* 1971;5:254–77.
- [23] Poncet M, Pelissier JF, Sebahoun M, Nasser CJ. A propos d'un cas d'autotopagnosie secondaire à une lésion pariéto-occipitale de l'hémisphère majeur. *Encéphale* 1971;60:1–14.
- [24] Sauguet J, Benton AL, Hécaen H. Disturbances of the body schema in relation to language impairment and hemispheric locus of lesion. *Journal of Neurology, Neurosurgery and Psychiatry* 1971;34:496–501.
- [25] Selecki BR, Herron JT. Disturbances of the verbal body image: a particular syndrome of sensory aphasia. *Journal of Nervous and Mental Disease* 1965;141:42–52.
- [26] Semenza C. Impairment in localization of body parts following brain damage. *Cortex* 1988;24:443–9.
- [27] Semenza C, Goodglass H. Localization of body parts in brain injured patients. *Neuropsychologia* 1985;23:161–75.
- [28] Sirigu A, Grafman J, Bressler K, Sunderland T. Multiple representations contribute to body knowledge processing: evidence from a case of autotopagnosia. *Brain* 1991;114:629–42.
- [29] Spinnler H, Tognoni G. Standardizzazione e taratura italiana di test neuropsicologici. *Italian Journal of Neurological Sciences* 1987;8(suppl):1–120.
- [30] Suzuki K, Yamadori A, Fujii T. Category-specific comprehension deficit restricted to body parts. *Neurocase* 1997;3:193–200.
- [31] Yamadori A, Albert ML. Word category aphasia. *Cortex* 1973;9:112–25.