

Surgical Transvenous Embolization of a Carotid-Cavernous Dural Fistula with Cortical Drainage via a Petrosal Vein: Two Technical Case Reports

Tsuyoshi Hara, M.D., Jun-ichiro Hamada, M.D.,
Yutaka Kai, M.D., Yukitaka Ushio, M.D.

Department of Neurosurgery, Kumamoto University School of Medicine, Kumamoto, Japan

OBJECTIVE AND IMPORTANCE: We present two interesting cases involving carotid-cavernous dural fistulae draining only or predominantly into the petrosal vein after previous incomplete, complicated, endovascular treatments. Transvenous embolization with Guglielmi detachable coils, via the petrosal vein, during surgical exposure completely obliterated the fistulae.

CLINICAL PRESENTATION: A 64-year-old man manifesting left ocular symptoms after incomplete embolization of a left carotid-cavernous dural fistula and a 56-year-old woman manifesting left hemiparesis after complicated embolization of a right carotid-cavernous dural fistula were referred to our hospital. A percutaneous transvenous approach was attempted in both cases, but the catheter could not reach the fistula site. A combined open surgical and endovascular approach was then used.

INTERVENTION: The hemispheric branch of the petrosal vein was exposed via a retromastoid craniectomy. The catheter was then directly introduced into the hemispheric branch, followed by navigation into the fistula site. The fistula was completely embolized with Guglielmi detachable coils.

CONCLUSION: The technique of surgical transvenous embolization via a petrosal vein is a valuable alternative for the treatment of carotid-cavernous dural fistulae that drain only or predominantly into the petrosal vein, when the percutaneous transvenous route is not accessible.

(Neurosurgery 50:1380–1384, 2002)

Key words: Cavernous sinus, Dural arteriovenous fistula, Endovascular, Surgery

For carotid-cavernous dural fistulae, transvenous embolization is the most frequently performed treatment. The goal is to reach the cavernous sinus and occlude it with coils. The procedure can usually be performed via an inferior petrosal sinus or a superior ophthalmic vein. However, there are patients for whom the percutaneous approach to these fistulae, via the femoral vein or a surgically exposed superior ophthalmic

vein, is not feasible. The intractability of these lesions and their tendency to recur, especially after previous endovascular treatments, exhausts the available routes and tends to present difficulties with access to the cavernous sinus. We describe two patients with carotid-cavernous dural fistulae for whom drainage occurred only or predominantly into the petrosal vein after previous incomplete, complicated, endovas-

cular treatments, and we discuss a surgical, transvenous, embolization technique that may be useful in similar cases.

CASE REPORTS

Patient 1

A 64-year-old man was referred to our hospital after incomplete transarterial embolization of a dural arteriovenous fistula of the left cavernous sinus at another hospital. At admission, 3 weeks after the initial treatment, he manifested moderate exophthalmus and chemosis of his left eye. Four-vessel cerebral angiography revealed a recurrent and more prominent arteriovenous shunt of the left cavernous sinus. The fistula was fed by branches of the intercavernous and external carotid arteries. The venous phase of the cerebral angiograms revealed no petrosal sinuses; the fistula drained predominantly through the cerebellar veins, via the left petrosal vein, and slightly through a very small left ophthalmic vein (Fig. 1). A percutaneous transvenous approach was attempted, but the catheter reached only to the midportion of the inferior petrosal sinus.

Therefore, the patient underwent a suboccipital craniectomy. A combined surgical and endovascular approach to the cavernous sinus was used (see be-

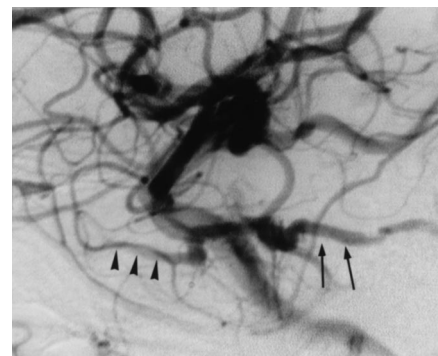


FIGURE 1. Patient 1. Left internal carotid artery angiogram, lateral view, demonstrating the carotid-cavernous fistula draining slightly into the superior orbital vein (arrowheads) but mainly into the petrosal vein (arrows).

low). The postoperative course was uneventful and, as noted in the follow-up examination, the patient's symptoms resolved completely. Follow-up angiograms obtained 6 months later revealed no evidence of recurrence of the fistula (Fig. 2).

Patient 2

A 56-year-old woman presented with a history of redness in her right eye, proptosis, double vision, and a progressive decrease in visual acuity. She underwent initial evaluation at another hospital, and four-vessel cerebral angiography revealed a dural arteriovenous fistula of the right cavernous sinus. The fistula was fed by branches of the intercavernous and external carotid arteries. The fistula drained predominantly through the superior orbital vein, sphenoparietal sinus, and inferior petrosal sinus. The patient underwent transarterial and transvenous embolizations via the superior orbital vein and the sphenoparietal sinus; however, those procedures proved to be incomplete and complicated. Although the patient's ocular symptoms had almost completely resolved, mild left-sided hemiparesis was noted 3 days after the transvenous embolization. The patient was referred to our clinic for further treatment because of progressive exacerbation of her hemiparesis during a 2-week preadmission period. The neurological examination performed at the time of admission revealed moderate left hemiparesis, with mild ocular symptoms. Computed tomographic scans and magnetic resonance imaging scans demonstrated a venous infarction

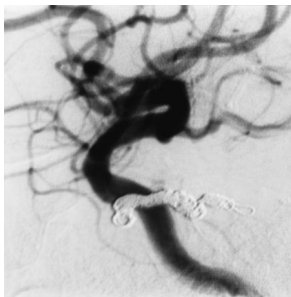


FIGURE 2. Patient 1. Follow-up angiogram obtained 6 months later, revealing no evidence of recurrence of the fistula.

in the right thalamus and midbrain (Fig. 3). Four-vessel cerebral angiography revealed a residual arteriovenous shunt of the right cavernous sinus. The fistula was fed by branches of the intercavernous and external carotid arteries. The venous phase of the cerebral angiograms did not demonstrate the superior ophthalmic vein or the petrosal sinuses. The fistula drained only through the cerebellar veins, including a lateral mesencephalic vein connected to the basal vein via the right petrosal vein (Fig. 4). Although a percutaneous transvenous approach was attempted, the catheter could not reach the fistula site because of thrombosis of the inferior petrosal sinus.

The patient underwent a suboccipital craniectomy. In this case also, a combined surgical and endovascular approach to the cavernous sinus was used (see below). The postoperative course was uneventful, and the follow-up examination revealed that the patient's ocular symptoms and venous congestion had almost completely resolved. The patient was subsequently transferred to another hospital for rehabilitation. Follow-up angiograms obtained 3 months later revealed no evidence of recurrence of the fistula (Fig. 5).

SURGICAL APPROACH

After routine induction of general endotracheal anesthesia, the patient was placed in a lateral position. With the use of a linear retromastoid scalp incision, a circular craniectomy was performed, ex-

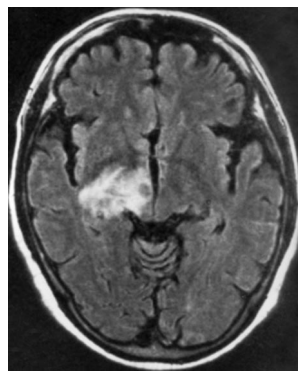


FIGURE 3. Patient 2. Axial magnetic resonance imaging scan, demonstrating venous infarction in the right thalamus and midbrain.

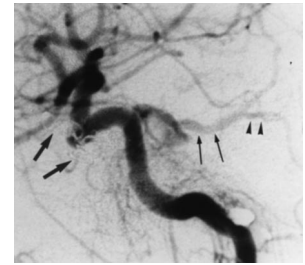


FIGURE 4. Patient 2. Left internal carotid artery angiogram, lateral view, demonstrating the carotid-cavernous fistula draining only into the petrosal vein (small arrows), with retrograde emptying into the cerebellar vein (arrowheads). Large arrows, previously placed coils.

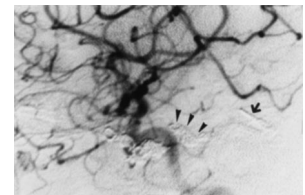


FIGURE 5. Patient 2. Follow-up angiogram obtained 3 months later, revealing no evidence of recurrence of the fistula. The additional coils (arrowheads) and a clip (arrow) on the petrosal vein just proximal to its branching site can be observed.

tending up to the inferior edge of the transverse sinus and laterally exposing the medial edge of the sigmoid sinus. The dura was incised in a cruciate manner. As the cerebrospinal fluid drained from the subarachnoid space, only minimal gentle retraction was required to proceed along the superolateral margin of the cerebellum. The junction of the tentorium and the petrous bone was exposed. As we proceeded anteriorly along the superolateral margin of the cerebellum, the distal part of the red arterialized petrosal vein came into view (Fig. 6). As long a branch as possible of this vein draining the superior surface of the cerebellar hemisphere was gently dissected away from the cerebellar cortex, just proximal to its tributary branches. A temporary clip was positioned on the petrosal vein, and another temporary clip was placed on the dissected hemispheric branch of the petrosal vein, just proximal to its

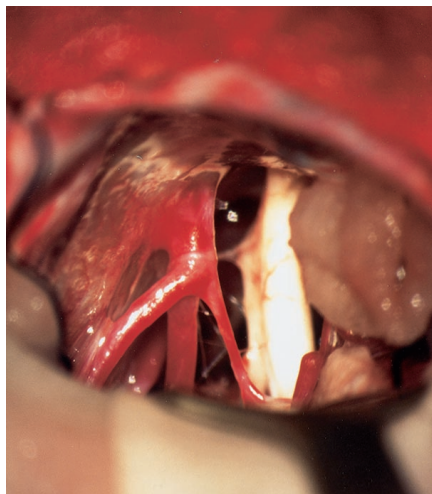


FIGURE 6. Patient 2. Intraoperative photograph, showing the red arterialized and trifurcated petrosal vein. The trigeminal nerve can be observed.

branching site. The hemispheric branch was then sectioned just proximal to the clip. A microcatheter was directly introduced into the hemispheric branch at the site of section (Fig. 7). A guidewire was then introduced and directed anteriorly toward the cavernous sinus. We

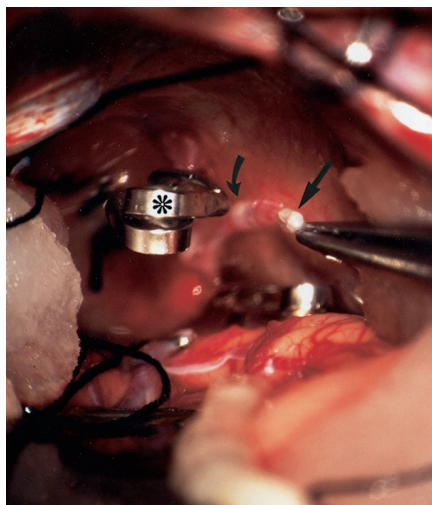


FIGURE 7. Patient 2. Intraoperative photograph, demonstrating direct introduction of a microcatheter into a branch of the petrosal vein draining the superior surface of the cerebellar hemisphere, at the site of section (*straight arrow*). The temporary clip on the petrosal vein (*asterisk*) and the tip of the microcatheter (*curved arrow*) should be noted.

encountered some difficulty in maneuvering the guidewire into the cavity of the cavernous sinus, because of the sharp angle between the petrosal vein and the superior petrosal sinus. Widening of this angle via slight ventral inclination of the petrosal vein allowed smooth navigation of the guidewire into the affected cavity of the cavernous sinus. A catheter was then pushed over the guidewire into the cavernous sinus and was used to place Guglielmi detachable coils at the origin of the fistula. This part of the operation was performed by using both a surgical microscope and intraoperative angiography. The latter technique confirmed complete obliteration of the fistula.

DISCUSSION

Although the exact pathophysiological features of carotid-cavernous dural fistulae are unknown, endovascular treatment is the standard therapy; occlusion of the venous side of the fistula, via a transvenous approach, is currently the predominant form of treatment (11). Depending on the type of venous drainage and the anatomic relationships, various venous routes are available for navigation of a microcatheter into the cavernous sinus. These routes include the petrosal sinuses (2–4, 6, 8, 13), the superior ophthalmic vein (5, 9, 10, 12), the sylvian vein (7), and the pterygoid plexus (6).

If transvenous occlusion is to be performed, then the most dangerous veins observed should be occluded first, with confirmation that the actual fistulous site has been occluded. Care must be taken not to occlude the inferior petrosal sinus before cortical draining veins have been occluded. If there is a cortical vein draining the sinus, then occlusion must be performed first on the side of the cavernous sinus at the origin of that vessel. Occlusion of venous outflow could result in redirection of the flow into the remaining pathways, thus aggravating cerebral cortical venous hypertension. These patients are at risk of intracerebral hemorrhage and should also receive emergency therapy (1).

For our Patient 1, the fistula drained predominantly into the petrosal vein. For Patient 2, the fistula drained only

into the petrosal vein. Although successful catheterization of a nonobserved inferior petrosal sinus (a major access route) has been achieved by several authors (2, 4, 8) and an approach via the contralateral cavernous sinus may be successful in some cases, these techniques did not yield access to the fistula site for our patients. The remaining option was direct surgical exposure of the petrosal vein.

To avoid the risks associated with a direct surgical approach to the cavernous sinus (especially potential injury to the intracavernous cranial nerves), we used surgical transvenous embolization. There were two important technical points for this approach. First, as long a branch as possible of the petrosal vein that drained the superior surface of the cerebellar hemisphere was dissected away from the cerebellar cortex just proximal to its tributary branches, because the working space was small and deep. This provided sufficient working space for direct catheterization. Second, when we encountered difficulties in introducing the guidewire into the cavity of the cavernous sinus, we were able to soften the sharp angle between the petrosal vein and the superior petrosal sinus via slight ventral inclination of the petrosal vein. This allowed smooth navigation of the guidewire, and subsequently the microcatheter, into the cavernous sinus.

For our Patient 2, it is reasonable to assume that occlusion of the venous drainage pathways, including the superior ophthalmic vein and the sphenoparietal sinus, with coils and thrombosis of the inferior petrosal sinus redirected the venous outflow into the petrosal vein, resulting in venous infarction in the thalamus and midbrain. Clipping of the petrosal vein might have been adequate for treatment of the fistula; however, we considered packing of the affected sinus to be more reliable than clipping of the distal draining vein, because it eliminated the possibility of opening other draining channels that were not observed on angiograms.

CONCLUSION

The technique of surgical transvenous embolization via a petrosal vein

Unauthorized reproduction of this article, in whole or in part, without permission, is prohibited.

that is described here is a valuable alternative for the treatment of carotid-cavernous fistulae that drain only or predominantly into the petrosal vein. This method may be useful in some cases in which transvenous access to the fistula site via a femoral approach or via exposure of the superior orbital vein is not possible.

Received, July 17, 2001.

Accepted, October 23, 2001.

Reprint requests: Jun-ichiro Hamada, M.D., Department of Neurosurgery, Kumamoto University School of Medicine, 1-1-1 Honjo, Kumamoto 860-8556, Japan.

Email: j-hamada@fc.kuh.kumamoto-u.ac.jp

REFERENCES

- Awad IA, Little JR, Akrawi WP, Ahl J: Intracranial dural arteriovenous malformations: Factors predisposing to an aggressive neurological course. *J Neurosurg* 72:839-850, 1990.
- Benndorf G, Bender A, Lehmann R, Lanksch W: Transvenous occlusion of dural cavernous sinus fistulas through the thrombosed inferior petrosal sinus: Report of four cases and review of the literature. *Surg Neurol* 54:42-54, 2000.
- Courtheoux P, Huet H, Hourcade A, Theron J: Dural fistula of the cavernous sinus: Treatment through an intravenous approach apropos of 4 cases [in French]. *J Neuroradiol* 22:301-308, 1995.
- Halbach VV, Higashida RT, Hieshima GB, Hardin CW, Pribram H: Transvenous embolization of dural fistulas involving the cavernous sinus. *AJNR Am J Neuroradiol* 10:377-383, 1989.
- Hanneken AM, Miller NR, Debrun GM, Nauta HJ: Treatment of carotid-cavernous sinus fistulas using a detachable balloon catheter through the superior ophthalmic vein. *Arch Ophthalmol* 107:87-92, 1989.
- Jahan R, Gobin YP, Glenn B, Duckwiler GR, Viñuela F: Transvenous embolization of a dural arteriovenous fistula of the cavernous sinus through the contralateral pterygoid plexus. *Neuroradiology* 40:189-193, 1998.
- Kuwayama N, Endo S, Kitabayashi M, Nishijima M, Takaku A: Surgical transvenous embolization of a cortically draining carotid cavernous fistula via a vein of the sylvian fissure. *AJNR Am J Neuroradiol* 19:1329-1332, 1998.
- Malek AM, Halbach VV, Dowd CF, Higashida RT: Diagnosis and treatment of dural arteriovenous fistulas. *Neuroimaging Clin N Am* 8:445-468, 1998.
- Miller NR, Monsein LH, Debrun GM, Tamargo RJ, Nauta HJ: Treatment of carotid-cavernous sinus fistulas using a superior ophthalmic vein approach. *J Neurosurg* 83:838-842, 1995.
- Monsein LH, Debrun GM, Miller NR, Nauta HJ, Chazaly JR: Treatment of dural carotid-cavernous fistulas via the superior ophthalmic vein. *AJNR Am J Neuroradiol* 12:435-439, 1991.

- Mullan S: Reflections upon the nature and management of intracranial and intraspinal vascular malformations and fistulae. *J Neurosurg* 80:606-616, 1994.
- Quinones D, Duckwiler G, Gobin PY, Goldberg RA, Viñuela F: Embolization of dural cavernous fistulas via superior ophthalmic vein approach. *AJNR Am J Neuroradiol* 18:921-928, 1997.
- Yamashita K, Taki W, Nishi S, Sadato A, Nakahara I, Kikuchi H, Yonekawa Y: Transvenous embolization of dural carotid-cavernous fistulae: Technical considerations. *Neuroradiology* 35:475-479, 1993.

COMMENTS

Hara et al. report on two patients with complicated carotid-cavernous fistulae that were successfully treated with transvenous embolization via a surgically exposed petrosal vein. Transection of a petrosal vein alone might have been a conventional way to treat this type of arteriovenous fistula. However, occlusion of the fistula site is important and reasonable, to avoid recruitment of new dangerous draining pathways.

The cautionary aspects of this report are also very important. The cases indicate the danger of incomplete treatment of carotid-cavernous fistulae and the possibility of iatrogenic venous hypertension as a sequela.

Akiyo Sadato
Nobuo Hashimoto
Kyoto, Japan

Hara et al. describe two fascinating and challenging cases. They are fascinating with respect to the pathophysiological processes and natural progression of dural carotid-cavernous fistulae and challenging with respect to treatment options. The second case in particular seems to illustrate the propensity of dural arteriovenous fistulae to perpetuate after incomplete occlusion, by redirecting flow to available venous channels and causing venous hypertension at any available site. The reason for new venous recruitment in this case, i.e., previous occlusion of otherwise accessible venous access to the lesion for embolization, is also a considerable obstacle to treatment. The authors describe an aggressive effective approach that takes advantage of the dilated venous pathways created by the lesion itself.

Combined surgical and endovascular treatment of carotid-cavernous fistulae is hardly a new concept. In fact, one of

the earliest treatments was transarterial muscle embolization after surgical exposure of the carotid artery. In recent years, however, the development of dural fistula treatment (indeed, the treatment of cerebrovascular disease itself) has followed two parallel but separate paths, i.e., open surgery and endovascular surgery. The appearance of highly integrated surgical and endovascular cerebrovascular services and the "hybrid" training of neurosurgeons to perform endovascular procedures has made the combined surgical and endovascular treatment of cerebrovascular disease more widely available.

Andrew J. Ringer
John M. Tew, Jr.
Cincinnati, Ohio

Surgical access for transvenous embolization of dural arteriovenous malformations has been used in numerous settings. Cannulation of the superior ophthalmic vein, puncture of the torcular or transverse sinus, and direct puncture of the cavernous sinus have all been widely applied and described. Mullan has written extensively on the use of this technique for the treatment of complex dural fistulae.

The authors present two cases involving clever application of the same principle via direct cannulation of the petrosal sinus for transvenous access and treatment of complex cavernous sinus dural fistulae. Readers are reminded that many advances are still possible through the creative application of pathoanatomic principles and the combination of surgical and endovascular techniques.

Issam A. Awad
Denver, Colorado

The authors present two interesting cases involving carotid-cavernous fistulae that drained primarily or solely into the petrosal vein, where occlusion of the inferior petrosal sinus precluded a retrograde transvenous approach to the fistula. In one case, prior partial obliteration of the fistula had been accomplished with transarterial and transvenous embolization via the superior orbital vein and sphenoparietal sinus. Both patients were successfully cured

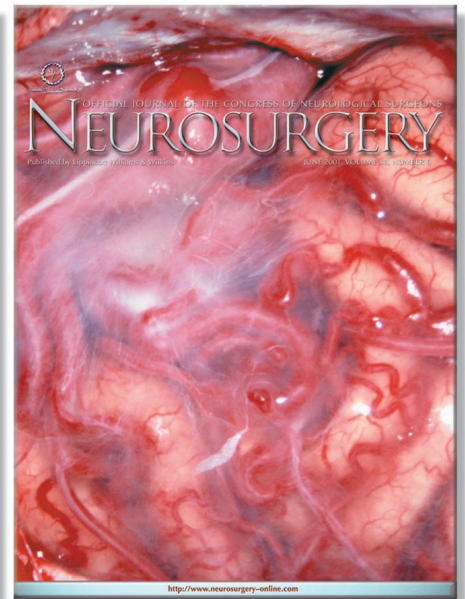

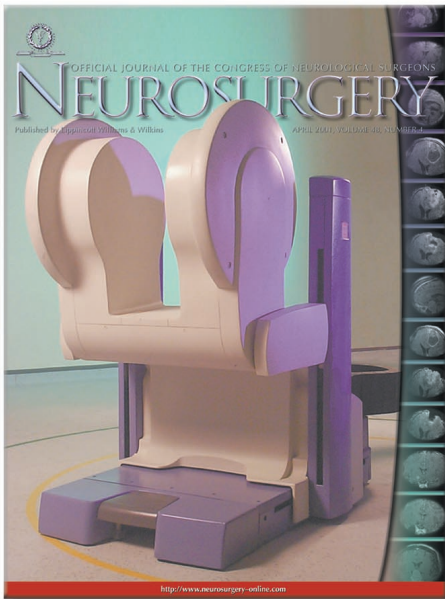
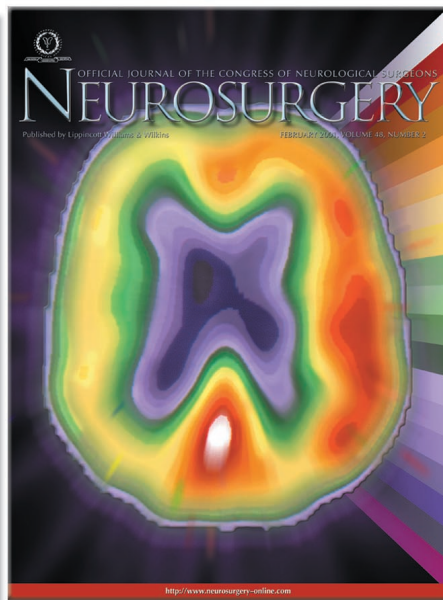
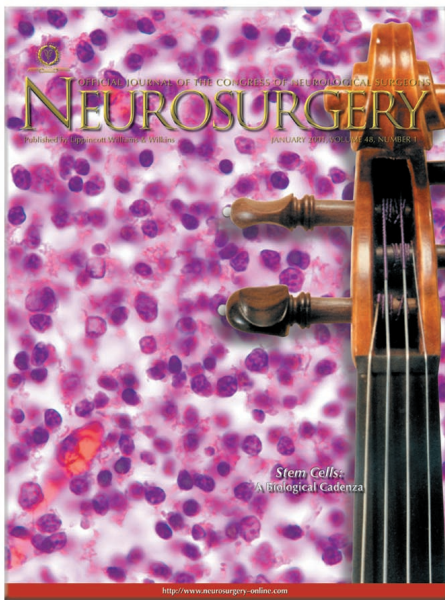
with the use of a retromastoid craniectomy, followed by intraoperative cannulation of the arterialized cerebellar hemisphere branch of the petrosal vein and transvenous navigation into the cavernous sinus, where Guglielmi detachable coils were successfully deployed.

Although it might have been possible to cure both residual fistulae by simply surgically clipping or coagulating the petrosal vein, those alternative proce-

dures might not have completely obliterated the fistula and they would carry some risk of causing cerebellar hemorrhage, if the cerebellar venous pressure were suddenly increased. In the second case, it is also possible that the residual fistula might have progressed to occlusion if more than 2 weeks had been allowed to elapse after the initial embolization attempt and partial obliteration. For some patients with carotid-cavernous fistulae for which endovascu-

lar embolization was incomplete, we cured the arteriovenous fistulae by surgically packing the cavernous sinus, using Parkinson's triangle as an entry point. The authors describe a clever, quite novel technique for curing these inaccessible carotid-cavernous fistulae, by using a surgical transvenous approach via the petrosal vein.

Gary K. Steinberg
Stanford, California



Unauthorized reproduction of this article, in whole or in part, without permission, is prohibited.