

Disappearance of an Intracerebral Arteriovenous Malformation in an HIV-Infected Patient after Initiation of HAART

K. Wolf, E.C. Kirsch, L. Sponagel, D.A. Rüfenacht, M. Battegay

Abstract

HIV infection or complications of HIV-induced immunodeficiency may affect the central nervous system (CNS). However, vascular cerebral pathologies are very rare, in particular intracerebral arteriovenous malformations (AVM). We report the case of an HIV-infected patient who had a cerebral AVM leading to symptoms such as recurring focal seizures. Only after initiation of potent antiretroviral combination therapy, but not antiretroviral monotherapy or bitherapy, could the viral load be suppressed and immunodeficiency resolved. Two years after the start of highly active antiretroviral therapy (HAART) total occlusion of the AVM could be demonstrated. Taken together, this case report may demonstrate the potent angiogenic activity of HIV for AVM. Also, this case report might show that inhibition of such a cofactor may lead to resolution of an AVM.

Key Words

HIV · Arteriovenous malformation · Antiretroviral therapy

Infection 2002; 30: 101–103
DOI 10.1007/s15010-002-2100-7

Introduction

HIV infection or complications of immunodeficiency, including infection with opportunistic microorganisms and malignancies, may affect the CNS [1]. Vascular cerebral pathologies in HIV-infected patients include arterial fibrosis, calcification, vasculitis and rarely intracerebral arteriovenous malformations (AVM) [2]. We report the case of an HIV-infected patient who had a cerebral AVM which completely resolved 2 years after initiation of potent antiretroviral combination therapy.

Case Report

The 53-year-old patient had acquired HIV infection in 1984. An oral hairy leukoplakia and a generalized lymphadenopathy were found and considered as HIV-related diseases. In 1989 he complained of recurrent vertigo, focal seizures with dysesthesia and weakness of his left leg. On cerebral magnetic resonance imaging (MRI) no signs of infarction, bleeding, encephalitis or toxoplas-

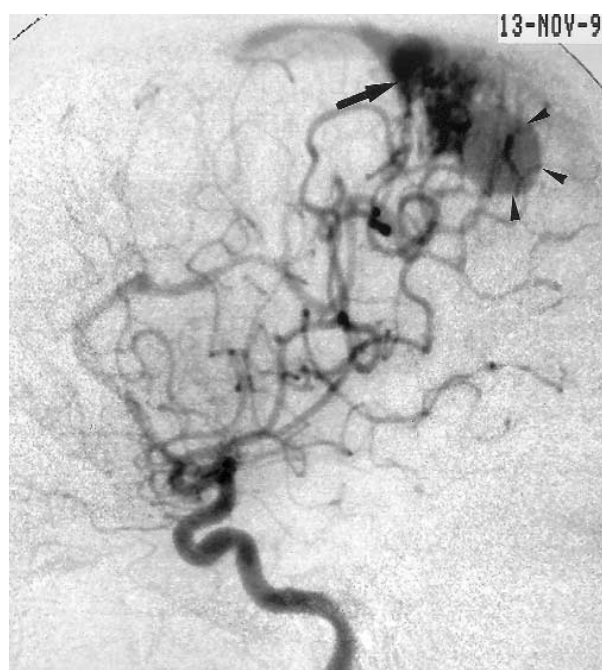


Figure 1. Right internal carotid digital subtraction angiography (lateral plane), before initiating a potent antiretroviral combination therapy. A rolandic, moderate sized AVM (black arrow) is demonstrated, with arterial supply from the right anterior and middle cerebral arteries. Note the large venous varix (arrowheads), which conducts the venous drainage to the adjacent superior sagittal sinus.

K. Wolf, L. Sponagel, M. Battegay (corresponding author)

Basel Center for HIV Research, Outpatient Dept. of Internal Medicine, University Hospital Basel, Petersgraben 4, CH-4031 Basel, Switzerland, Phone: (+41/61) 265-5072, Fax: -4604, e-mail: mbattegay@uhbs.ch

E.C. Kirsch

Neuroradiology, Dept. of Radiology, University Hospital Basel, Switzerland

D.A. Rüfenacht

Neuroradiology-HUG, University Hospital Geneva, Switzerland

Received: June 15, 2001 • Revision accepted: December 3, 2001

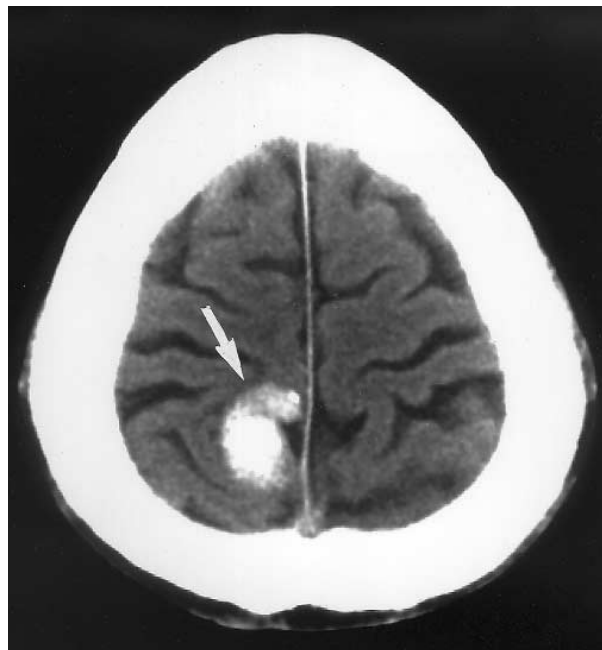


Figure 2. Unenhanced CT on the level of the high frontoparietal region. A hyperintense area, located in the right, parafalcine central gyrus (white arrow) is demonstrated, consistent with thrombosis of the former AVM.

mosis were detected. However, a cortical AVM was found in the right parietal lobe in the parasagittal region. On digital subtraction angiography (DSA) a rolandic, moderate sized (< 3 cm) AVM was confirmed, with arterial supply from the right anterior and middle cerebral arteries. There was single venous drainage to the adjacent superior sagittal sinus with a large varix. Additionally, a flow-related aneurysm of the pericallosal artery was diagnosed. After initiation of carbamazepine (400 mg bid), focal seizures recurred only sporadically. HIV infection remained stable for the next few years with CD4 T-cell counts between 300/ μ l and 500/ μ l, i.e. indicative of an intermediate immunodeficiency. In December 1990 an antiretroviral monotherapy with zidovudine (250 mg twice a day) was initiated and changed to didanosine (200 mg twice a day) in July 1991. In November 1996, the frequency of seizures increased. A repeat brain MRI revealed no changes. On DSA the right parietal AVM remained patent and was unchanged in size (Figure 1). Importantly, the viral load was never suppressed due to insufficient monotherapy. In July 1997 a potent antiretroviral combination therapy containing stavudine (40 mg twice a day), lamivudine (150 mg twice a day) and indinavir (800 mg three times a day) was started. Viral loads were suppressed for the first time below the limit of detection of 20 copies/ml. For HIV quantification plasma samples were processed according to the published protocols of the Roche HIV monitor test kit (Roche Diagnostics, Rotkreuz, Switzerland), with the modification of the ultrasensitive assay [3]. Subsequently, CD4 T-cell counts rose significantly to above 500/ μ l. In summer 1999, the patient suffered again from recurrent focal seizures to his left leg. The AVM was demonstrated to trigger these seizures on electroencephalography. In November 1999, the patient was hospitalized for a generalized tonic-clonic seizure. On unenhanced computed tomogra-

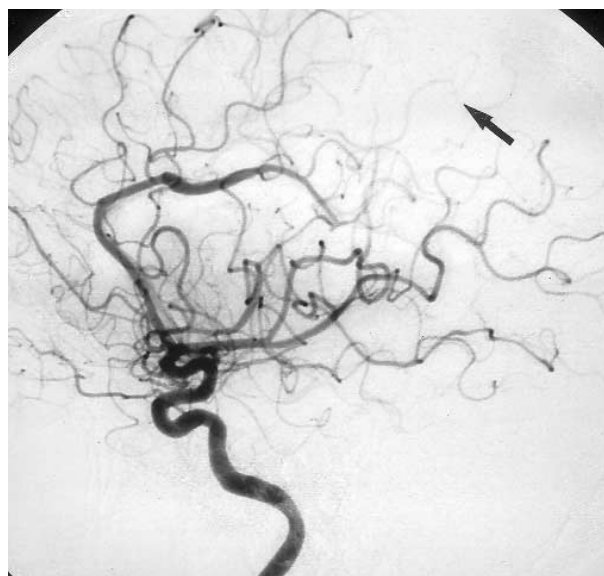


Figure 3. Right internal carotid digital subtraction angiography (lateral plane) 2 years after the antiretroviral combination therapy. Disappearance of the AVM (black arrow).

phy (CT) a hyperintense lesion was seen in the region of the earlier AVM, suspicious for a spontaneous thrombosis (Figure 2). This was confirmed with cerebral DSA. The AVM had undergone substantial changes without evidence for arteriovenous shunting. In addition, feeding arteries were reduced in size and venous structures only mildly increased (Figure 3). For persistence of sensible Jackson seizures, an antiepileptic therapy with oxcarbazepine (600 mg twice a day) was started. In June 2000, a follow-up MRI of the neurocranium showed a progressive organization and resorption of the parietal thrombosis. On follow-up MR angiography and cerebral DSA examinations a total occlusion of the AVM with normalization of the locoregional brain vasculature could be demonstrated at 1.5 years after diagnosis of thrombosis. The patient is clinically well and remains under anti-epileptic and anti-HIV medication. Electroencephalography in June 2000 showed a marginal change in normal activity, probably due to anti-epileptic therapy. However, no focus and no sign of cerebral hyperexcitability could be detected. The efficacy of antiretroviral therapy is still excellent with a suppressed viral load and a CD4 T-cell count of 616/ μ l.

Discussion

An intracerebral AVM is uncommon during HIV infection. Most case reports of AVM in HIV-infected patients concern children [4–7]. Interestingly, in these patients viral activity was usually very high, or the stage of HIV disease advanced [4]. In one study, HIV antigen was demonstrated in cells of the intima of an aneurysm of the circle of Willis of a 6-year-old boy [5], supporting a possible association of HIV and AMV. Significant angiogenic potential of virus could be demonstrated in HIV-infected patients coinfecting with human herpesvirus 8, who developed Kaposi's sarcoma [8]. The molecular pathogenesis is being elucidated

by recent findings, e.g. the potent trans-activator HIV protein Tat and its short core domain, Tat21-40, possesses potent angiogenic activity [9]. Tat also augments the activities of angiogenic molecules, such as basic fibroblast growth factor, interferon gamma and vascular endothelial growth factor [10]. Taken together, these results may demonstrate a role of HIV in activating an AVM. Conversely, potent antiretroviral therapy may reduce the activity of the virus-driven angiogenic process and subsequently lead to thrombosis of the AVM and its resolution as observed in our patient. First clinical signs of AVM 5 years after HIV diagnosis with active viral replication and resolution 2 years after initiation of potent anti-HIV therapy may argue for our hypothesis. On the other hand, very few spontaneous disappearances of AVM are reported [11–15]. Thrombosis within the vessels of an AVM is believed to be the most frequent cause. This may be triggered by intracerebral hemorrhage secondary to AVM rupture [12], due to accompanying brain edema and vasospasm [11], occlusion of a single draining vein with consecutive venous outflow obstruction and lesion thrombosis [13] or due to head injury [15]. Interestingly, immunohistochemical analysis of a thrombosed AVM revealed ongoing active angiogenic changes within AVM vessels 1 month after thrombosis [13]. This might suggest the possibility that viruses are significant cofactors for angiogenic processes and activation of AVM. The patient described in our report highlights an uncommon but clinically relevant and potentially life-threatening pathology in HIV-infected patients. Options for treatment of a cerebral AVM generally include watchful waiting, endovascular embolization, surgery and radiosurgery. Although it is not possible to construct a definite causal relationship upon a single case report, potent antiretroviral therapy may offer an additional therapy option in HIV-infected patients presenting with an AVM via inhibition of virus-induced angiogenic stimulation.

Acknowledgments

The authors are thankful to Edouard Battegay and Ernst-Wilhelm Radü for valuable discussions.

References

1. Tucker T: Central nervous system AIDS. *J Neurol Sci* 1989; 89: 119–133.
2. Mizusawa H, Hirano A, Llena JF, Shintaku M: Cerebrovascular lesions in acquired immune deficiency syndrome (AIDS). *Acta Neuropathol (Berl)* 1988; 76: 451–457.
3. Morandi PA, Schockmel GA, Yerly S, Burgisser P, Erb P, Matter L, Sitavanc R, Perrin L: Detection of human immunodeficiency virus type 1 (HIV-1) RNA in pools of sera negative for antibodies to HIV-1 and HIV-2. *J Clin Microbiol* 1998; 36: 1534–1538.
4. Husson RN, Saini R, Lewis LL, Butler KM, Patronas N, Pizzo PA: Cerebral artery aneurysms in children infected with human immunodeficiency virus. *J Pediatr* 1992; 121: 927–930.
5. Kure K, Park YD, Kim TS, Lyman WD, Lantos G, Lee S, Cho S, Belman AL, Weidenheim KM, Dickson DW: Immunohistochemical localization of an HIV epitope in cerebral aneurysmal arteriopathy in pediatric acquired immunodeficiency syndrome (AIDS). *Pediatr Pathol* 1989; 9: 665–667.
6. Gavin P, Yogev R: Central nervous system abnormalities in pediatric human immunodeficiency virus infection. *Pediatr Neurosurg* 1999; 31: 115–123.
7. Fulmer BB, Dillard SC, Musulman EM, Palmer CA, Oakes J: Two cases of cerebral aneurysms in HIV+ children. *Pediatr Neurosurg* 1998; 28: 31–34.
8. Mesri EA: Inflammatory reactivation and angiogenicity of Kaposi's sarcoma-associated herpesvirus/HHV8: a missing link in the pathogenesis of acquired immunodeficiency syndrome-associated Kaposi's sarcoma. *Blood* 1999; 93: 4031–4033.
9. Boykins RA, Mahieux R, Shankavaram UT, Gho YS, Lee SF, Hewlett IK, Wahl LM, Kleinman HK, Brady JN, Yamada KM, Dhawan S: Cutting edge: a short polypeptide domain of HIV-1-Tat protein mediates pathogenesis. *J Immunol* 1999; 163: 15–20.
10. Barillari G, Sgadari C, Palladino C, Gendelman R, Caputo A, Morris CB, Nair BC, Markham P, Nel A, Sturzl M, Ensoli B: Inflammatory cytokines synergize with the HIV-1 Tat protein to promote angiogenesis and Kaposi's sarcoma via induction of basic fibroblast growth factor and the alpha v beta 3 integrin. *J Immunol* 1999; 163: 1929–1935.
11. Ezura M, Kagawa S: Spontaneous disappearance of a huge cerebral arteriovenous malformation: case report. *Neurosurgery* 1992; 30: 595–599.
12. Pasqualin A, Vivenza C, Rosta L, Scienza R, Da Pian R, Colangeli M.I: Spontaneous disappearance of intracranial arterio-venous malformations. *Acta Neurochir (Wien)* 1985; 76: 50–57.
13. Abdulrauf SI, Malik GM, Awad IA: Spontaneous angiographic obliteration of cerebral arteriovenous malformations. *Neurosurgery* 1999; 44: 280–287.
14. Eisenmann JI, Alekoumbides A, Pribram H: Spontaneous thrombosis of vascular malformations of the brain. *Acta Radiol Diagn (Stockh)* 1972; 13: 77–85.
15. Carter BS, Brisman JL, Christopher OS: Spontaneous obliteration of an arteriovenous malformation associated with head trauma. *J Neurosurg* 2001; 94: 134.