

Neonatal Subependymal Giant Cell Astrocytoma

Azedine Medhkour^a David Traul^b Muhammad Husain^c

^aDivision of Neurosurgery, ^bSchool of Medicine, Medical College of Ohio, Toledo, Ohio, ^cDepartment of Pathology, University of Arkansas for Medical Sciences, Little Rock, Ark., USA

Key Words

Astrocytoma · Tuberos sclerosis · Neonatal

Abstract

Subependymal giant cell astrocytoma (SEGCA) is a benign, slow-growing glial tumor that manifests with signs and symptoms of obstructive hydrocephalus most often in adolescent patients with tuberous sclerosis complex (TSC). Neonatal highly aggressive SEGCA is very rare. We report a 5-month-old child with TSC presenting with a cystic mass lesion in the left frontal lobe as well as multiple other periventricular masses. After initial conservative treatment, the child was readmitted with intractable seizures, a massive increase in the size of the left frontal lobe tumor and obstructive hydrocephalus. Despite surgical interventions, the child succumbed to the intracranial lesions. In this report, we discuss the challenges of managing SEGCA and the importance of further studies, including genetic studies, that may lead to a better understanding of its pathophysiology.

Copyright © 2002 S. Karger AG, Basel

Introduction

Subependymal giant cell astrocytoma (SEGCA) is a slow-growing tumor arising in the periventricular regions adjacent to the foramen of Monro [1]. Commonly, SEG-

CA is diagnosed in adolescents as part of the tuberous sclerosis complex (TSC). Neonatal SEGCA is extremely rare, with less than 10 cases reported [1–6]. Considered a unique presentation of TSC, neonatal SEGCA may develop into highly aggressive, giant intracranial mass lesions within weeks of diagnosis, leading to rapid neurological deterioration and demise of the neonate despite aggressive surgical intervention. We report the case of a neonate diagnosed with TSC presenting with multiple SEGCA.

Case Report

This male neonate presented at the age of 7 weeks with intractable seizures. In the week prior to clinical evaluation, he developed facial twitching along with abnormal eye and mouth movements. These episodes had increased in both frequency and duration over a short period of time. The parents indicated that the neonate was sleepier than usual, in particular postictally. Additionally, the patient had frequent postprandial vomiting. On physical examination, the patient was awake and his anterior fontanel was soft and flat. His pupils were 3 mm and equally reactive to light. Extraocular movements were intact. The patient had decreased muscle tone; however, motor strength was within normal limits and he moved all four extremities appropriately. Chest auscultation revealed an irregular heart rhythm. Examination of the skin revealed two 0.5 × 2.0 cm hypopigmented lesions on the patient's left shin, well demonstrated by a Wood's lamp. Laboratory tests were unremarkable.

An electroencephalogram disclosed a focal area of sharp activity in the right frontocentral region. This finding was thought to be an underlying structural abnormality, possibly indicating an epileptogenic focus. Further evaluation of the irregular heart rhythm by echo-

KARGER

Fax +41 61 306 12 34
E-Mail karger@karger.ch
www.karger.com

© 2002 S. Karger AG, Basel
1016-2291/02/0365-0271\$18.50/0

Accessible online at:
www.karger.com/journals/pne

Azedine Medhkour, MD
Division of Neurosurgery, Medical College of Ohio
Dowling Hall, Room 2455, 3065 Arlington Avenue
Toledo, OH 43614-2598 (USA)
Tel. +1 419 383 3547, Fax +1 419 383 6570, E-Mail amedhkour@mco.edu

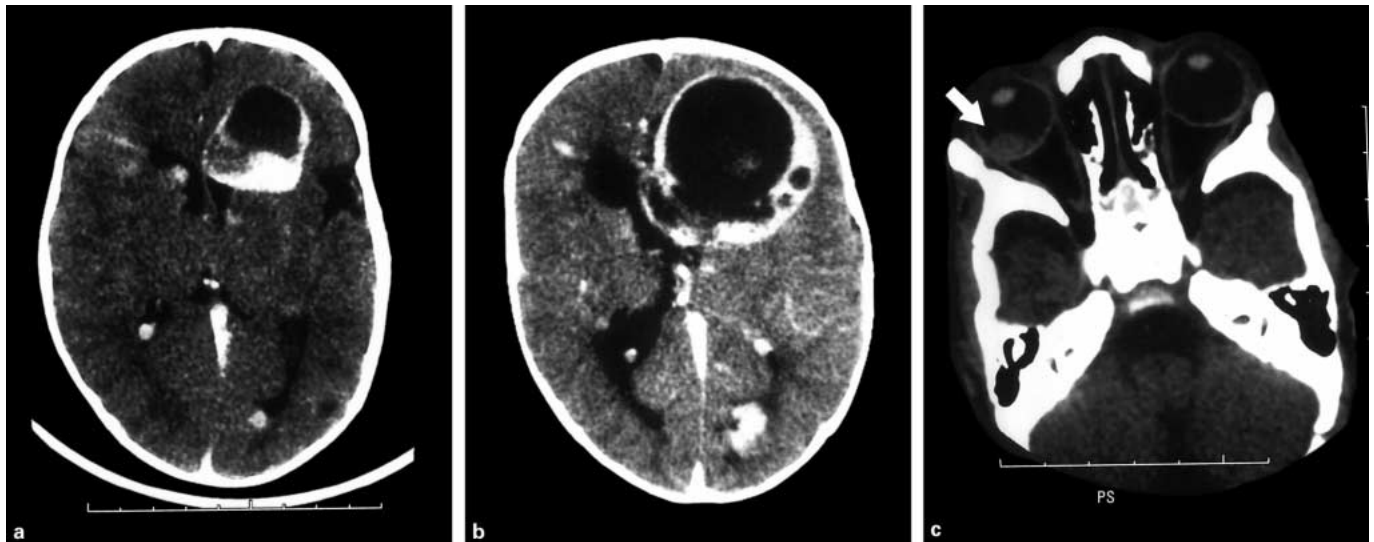


Fig. 1. a Enhanced head CT at the age of 7 weeks indicates a large ring-enhancing cystic mass in the left frontal lobe. b Subsequent CT at the age of 5 months reveals enlargement of the left frontal mass and a midline shift. c A large right-sided retinal mass (arrow) is also present.

cardiogram revealed a right atrial mass suspected to be a rhabdomyoma. Ophthalmologic examination under general anesthesia disclosed multiple large intraocular masses. Computed tomographic (CT) scan of the head revealed multiple cortical tubers as well as subependymal nodules. A large, ring-enhancing, partially cystic mass was observed in the left frontal lobe (fig. 1a). CT scan additionally disclosed a large, right-sided (fig. 1c) and a smaller, left-sided retinal mass.

The patient was initially treated with antiepileptic agents. At the age of 5 months, the patient was readmitted for sudden neurological deterioration, increased irritability and intractable seizures. Subsequent CT scan of the head revealed an interval enlargement of the left frontal lobe mass, measuring 6 cm in craniocaudal diameter by 4 cm in transverse diameter by 5 cm in anteroposterior diameter (fig. 1b). There was a massive midline structural shift from left to right with subfalcine herniation. The quadrigeminal plate cistern was asymmetric, indicating transtentorial herniation. The right-side ventricular system was enlarged. Additionally, the right frontal and occipital lesions were increased in size. An emergency craniotomy and subtotal resection of the left frontal tumor was performed. Intraoperatively, the brain herniated through the durotomy due to increased intracranial pressure. The cystic lesion was quickly drained. The tumor was highly vascular and extended from the vicinity of the Sylvian fissure laterally towards the interhemispheric region medially.

Pathological examination revealed a highly pleomorphic neoplasm composed of glial cells of small and atypically large sizes (fig. 2). The large cells had prominent nucleoli. There was an extensive necrotic and desmoplastic appearance. Mitotic figures were also present. Despite these findings, the tumor was benign in character. Cytogenic studies of the RB1 region of chromosome 13 using fluorescence in situ hybridization ruled out retinoblastoma.

Postoperatively, the patient did well for a period of 2 weeks. Upon reevaluation, it was observed that the other intracranial masses, particularly the right frontal lesion, had increased in size. Due to overt symptoms of increased intracranial pressure, resection of the right frontal lesion was performed. Intraoperatively, palpation of the exposed right frontal region revealed a board-like consistency throughout the exposed cortex. The right frontal mass was resected. The pathological specimen disclosed similar features to the left frontal tumor, characteristic of SEGCA. After an initial improvement, the condition of the patient deteriorated due to recurrence of the left frontal tumor, an increase in the size of the other intracranial masses and a generalized vasogenic edema. The patient subsequently succumbed to his disease within 2 weeks of the second tumor resection. An autopsy was not performed.

Discussion

SEGCA is part of TSC, a disorder that involves multiple organ systems. TSC is an autosomal-dominant neurocutaneous syndrome characterized by seizures, mental retardation and tumors of the skin, heart, kidneys and brain [7]. SEGCA is usually benign and is characterized by location in the vicinity of the foramen of Monro [7]. Patients may present with hydrocephalus in the case of obstruction of the cerebrospinal fluid pathways [1, 2]. Surgical resection of the tumors may result in resolution of the symptoms of increased intracranial pressure. Neo-

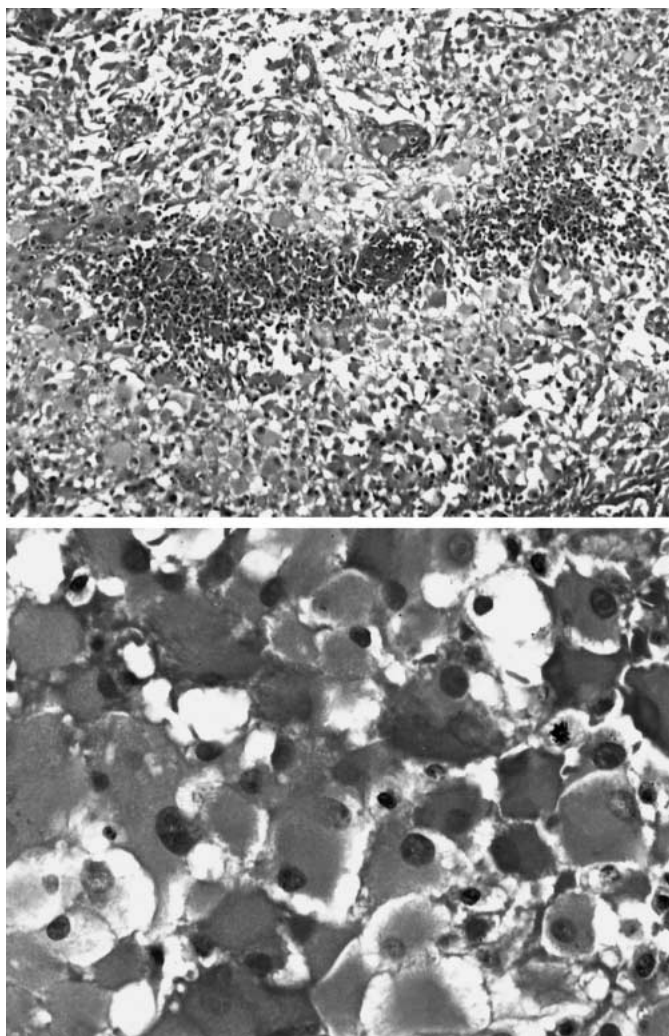


Fig. 2. Histological studies of the left frontal tumor reveal multiple foci of necrosis, with a vague pseudopalisading appearance. Some cells with prominent nucleoli give a ganglion-like appearance (top panel). Polygonal and globoid cells are seen with eccentric nuclei and abundant eosinophilic cytoplasm. One mitotic figure is visible (bottom panel).

neonatal SEGCA is more aggressive in nature and displays cellular pleomorphism, necrosis and mitotic figures despite its benign character [7].

Recent studies have indicated two genes associated with TSC disorder: TSC1 and TSC2. TSC1 has been localized to chromosome 9q34 [8]; however, the gene product of TSC1 is still not known. TSC2 is located on chromosome 16p13 and is thought to encode a tumor suppressor gene [9]. The protein product of TSC2, tuberlin, is normally present in multiple human tissues, including the

cerebellum and cerebral cortex [10]. Although loss of heterozygosity of TSC2 has been implicated in the development of inherited astrocytomas in adults, evidence of its association with pediatric tumor development is minimal [11]. Therefore, an unusually aggressive SEGCA as seen in our patient may be the result of more complex genetic events yet to be discovered. Better understanding of the genetic character of neonatal SEGCA and its manipulation may advance the current methods of therapy for these tumors.

In the present case, the neonate presented with intractable seizures, which is the most common (>80% of adult cases) presenting symptom [5]. The presence of intracranial SEGCA, multiple intraocular hamartomas, right atrial rhabdomyoma and hypopigmented skin lesions in our patient fulfilled the definitive criteria for diagnosing TSC [7]. Although TSC is believed to be autosomal dominant, there was no family history of TSC in the present case, which may indicate a new genetic mutation. Alternatively, variable penetrance of the TSC phenotype has been reported [5]. Postsurgical cardiac complications caused by cardiac rhabdomyomas in neonatal cases of TSC with SEGCA have been described [3], which suggest a conservative approach to initial management of an asymptomatic patient. However, due to a rapidly declining neurological status and symptoms of increased intracranial pressure, surgical resection of the SEGCA was warranted in our patient. Reports outlining the postoperative course after surgical resection of a SEGCA in neonates with clinical neurological deterioration are summarized in table 1. In a report by Painter et al. [3], two neonates with TSC found to have congenital brain tumors died shortly after tumor resection due to intraoperative ventricular arrhythmias. More recently, Oikawa et al. [6] reported a subtotal SEGCA resection in a neonate who remained neurologically stable for 6 months postoperatively, after which the patient developed myoclonic seizures. Additionally, Ramenghi et al. [2] reported a neonate with TSC who developed intractable seizures and mental retardation within 2 months of tumor resection. In the present report, our patient initially displayed improved neurological status; however, this lasted for only a brief period of time. Enlargement of the other intracranial lesions resulted in deterioration of the patient's health status and death despite a second tumor resection. To our knowledge, the benefit of radiotherapy or chemotherapy in neonatal SEGCA has not been formally investigated. In adolescents, SEGCA appears to be insensitive to radiotherapy, and reports have indicated that radiotherapy in addition to tumor resection does not offer any proven benefit to the

Table 1. Postoperative course after surgical resection of a SEGCA in neonates

| Report | Age at surgery/gender | Clinical findings | Treatment | Postoperative course |
|---------------------|-----------------------|---|------------------------------|--|
| Ramenghi et al. [2] | 5 months/male | opisthotonus, depigmented patches, seizures | resection | intractable seizures, mental retardation, cardiac hamartomas at 2 months |
| Painter et al. [3] | 6 weeks/female | depigmented patches, seizures | resection | died 5 h postoperatively from ventricular arrhythmia |
| | 5 days/male | macrocephaly, status epilepticus | subtotal resection | died 3 h postoperatively from ventricular arrhythmia |
| Oikawa et al. [6] | 16 days/female | lethargy | subtotal resection | stable 6 months postoperatively, then developed myoclonic seizures |
| Present report | 5 months/male | nausea, vomiting, depigmented patches, seizures | multiple subtotal resections | died 4 weeks postoperatively from intracranial masses |

patient [1, 12, 13]. Additionally, the benefit of chemotherapy in adolescent SEGCA has not been documented. These data indicate that, at present, tumor resection is the preferred treatment for patients with declining neurological status due to SEGCA.

The present report, together with the cases previously described, indicates that management of a neonate with aggressive intracranial tumors associated with TSC is extremely challenging and is associated with high morbidity and mortality.

References

- Hahn JS, Bejar R, Gladson CL: Neonatal subependymal giant cell astrocytoma associated with tuberous sclerosis: MRI, CT and ultrasound correlation. *Neurology* 1991;41:124–128.
- Ramenghi LA, Verrotti A, Domizio S, Di Rocco C, Morgese G, Sabatino G: Neonatal diagnosis of tuberous sclerosis. *Childs Nerv Syst* 1996;12:121–123.
- Painter MJ, Pang D, Ahdab-Barmada M, Bergman I: Connatal brain tumors in patients with tuberous sclerosis. *Neurosurgery* 1984;14:570–573.
- Al-Saleem T, Wessner LL, Scheithaur BW, Patterson K, Roach ES, Dreyer SJ, Fujikawa K, Bjornsson J, Berstein J, Henske EP: Malignant tumors of the kidney, brain, and soft tissues in children and young adults with the tuberous sclerosis complex. *Cancer* 1998;83:2208–2216.
- Nagib MG, Haines SJ, Erickson DL, Mastro AR: Tuberous sclerosis. A review for the neurosurgeon. *Neurosurgery* 1984;14:93–98.
- Oikawa S, Sakamoto K, Kobayashi N: A neonatal huge subependymal giant cell astrocytoma: Case report. *Neurosurgery* 1994;35:748–750.
- Gomez MR: Phenotypes of the tuberous sclerosis complex with a revision of diagnostic criteria. *Ann NY Acad Sci* 1991;615:1–7.
- Haines JL, Short MP, Kwaitkowski DJ, Jewell A, Andermann E, Bejjani B, Yang C-H, Gusella JF, Amos JA: Localization of one gene for tuberous sclerosis within 9q32–9q34 and further evidence for heterogeneity. *Am J Hum Genet* 1991;49:764–772.
- Identification and characterization of the tuberous sclerosis gene on chromosome 16. The European Chromosome 16 Tuberous Sclerosis Consortium. *Cell* 1993;75:1305–1315.
- Geist RT, Reddy AJ, Zhang J, Gutmann DH: Expression of the tuberous sclerosis 2 gene product, tuberin, in adult and developing nervous system tissues. *Neurobiol Dis* 1996;3:111–120.
- Wienecke R, Guha A, Maize JC Jr, Heideman RL, DeClue JE, Gutmann DH: Reduced TSC2 RNA and protein in sporadic astrocytomas and ependyomas. *Ann Neurol* 1997;42:230–235.
- Turgut M, Akalan N, Ozgen T, Ruacan S, Erbenli A: Subependymal giant cell astrocytoma associated with tuberous sclerosis: Diagnostic and surgical characteristics of five cases with unusual features. *Clin Neurol Neurosurg* 1996;98:217–221.
- Sinson G, Sutton LN, Yachnis AT, Duhaime AC, Shut L: Subependymal giant cell astrocytomas in children. *Pediatr Neurosurg* 1994;20:233–239.

Copyright: S. Karger AG, Basel 2002. Reproduced with the permission of S. Karger AG, Basel. Further reproduction or distribution (electronic or otherwise) is prohibited without permission from the copyright holder.

Copyright: S. Karger AG, Basel 2002. Reproduced with the permission of S. Karger AG, Basel. Further reproduction or distribution (electronic or otherwise) is prohibited without permission from the copyright holder.