

## CADASIL: PRESENTING AS A MOOD DISORDER

N. Thomas, T. Mathews\*, A. Loganathan+  
Medical Student, University of Dundee; \*Department of Neurology, Dayton Veterans  
Association Medical Center, Dayton, Ohio, U.S.A; +Borders General Hospital

**Abstract:** CADASIL is an autosomal dominant non-atherosclerotic vasculopathy that frequently presents as recurrent subcortical strokes, or vascular dementia in middle age. Some patients may have prominent mental symptoms or migraine. Widespread white matter demyelination and subcortical lacunar infarcts are demonstrated by magnetic resonance imaging. Demonstration of granular osmophilic material in arteries in skin biopsies is a useful diagnostic tool. CADASIL has been linked to mutation in the Notch 3 gene locus on chromosome 19. Genetic testing is available for clinical diagnosis.

Key words: CADASIL; Vascular dementia; Notch 3 gene

### Introduction

Cerebral autosomal dominant arteriopathy with subcortical infarcts and leukoencephalopathy (CADASIL) is increasingly being recognized as a common cause of familial vascular dementia and recurrent strokes in middle adulthood.<sup>1,2,3</sup> The clinical expression of CADASIL is highly variable and misdiagnosis is common. We report the clinical and autopsy findings of CADASIL in a patient whose initial manifestation was a severe depression.

### Case report

In 1977 this previously healthy 47-year-old man developed severe depression, anxiety and panic attacks refractory to medication and electro-convulsive therapy. Over the next eight years there was a slowly progressive dementia.

In 1985 he was investigated for vertigo and left facial weakness. He was normotensive and had no stroke risk factors. Except for memory impairment his neurological examination were normal. Cerebral angiography, electro-encephalography and spinal fluid analysis was normal. A computerized axial tomography scan of the head showed bilateral periventricular hypodensities.

In 1988 a MRI scan showed extensive hyperintensities and lacunar infarcts in the centrum semiovale and basal ganglia. (Fig. 1) His subsequent course was punctuated by recurrent ischaemic strokes and seizures. He became severely demented with corticospinal and corticobulbar signs. He progressed to a vegetative state and died 25 years after his initial mental symptoms.

### Family history (Fig. 2)

His father and uncle died of strokes at 35 and 45 years respectively. Both his sister and his daughter suffered from major depression and were confirmed to have CADASIL. Two nephews, both alcoholic, were likely to have had CADASIL. There was no family history of migraine.

### Autopsy

Cerebral white matter showed extensive symmetric demyelination and axonal rarefaction. There were numerous lacunar infarcts in the centrum semiovale basal ganglia, thalamus and brain stem. Small arteries and arterioles showed

marked thickening and deposits of non-amyloid material in the media. (Fig. 3)

### Discussion

The acronym CADASIL was introduced by Tournier-Lasserre *et al* who described a large French family with hereditary vascular dementia.<sup>1</sup> Worldwide over 400 families and sporadic cases have been identified.<sup>3</sup> CADASIL is probably underdiagnosed because the clinical spectrum is highly variable.

Typically symptoms begin between 30 and 50 years. Four clinical syndromes are seen:

- 1 **Recurrent subcortical strokes** or transient ischaemic attacks occur in 85% of patients.<sup>1,2,3</sup> In younger patients with recurrent familial stroke, rare causes such as inherited coagulopathies and CADASIL should be considered.
- 2 **Dementia** with a progressive or stepwise course is present in 40%. Unlike multi-infarct dementia major stroke risk factors are not present in CADASIL.
- 3 **Mood disorders** are prominent in 25% of CADASIL.<sup>3,5</sup> In our patient, major depression refractory to treatment preceded cognitive decline and recurrent strokes by eight years. Both his sister and daughter had major depression as the initial manifestation of CADASIL.

Fig 1: T2 weighted MRI  
Periventricular white matter hyperintensities

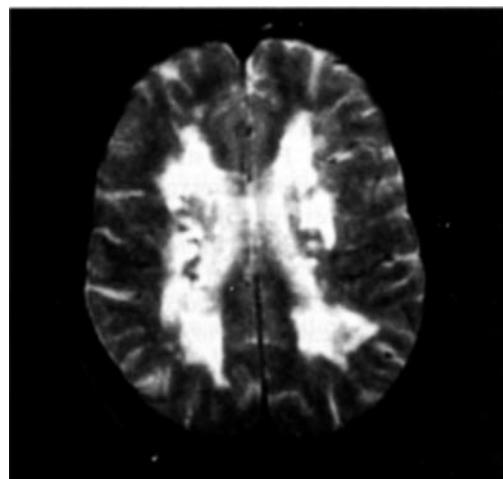


Fig 2: Family Tree

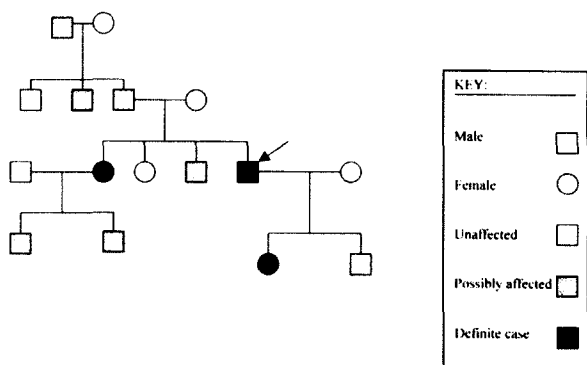
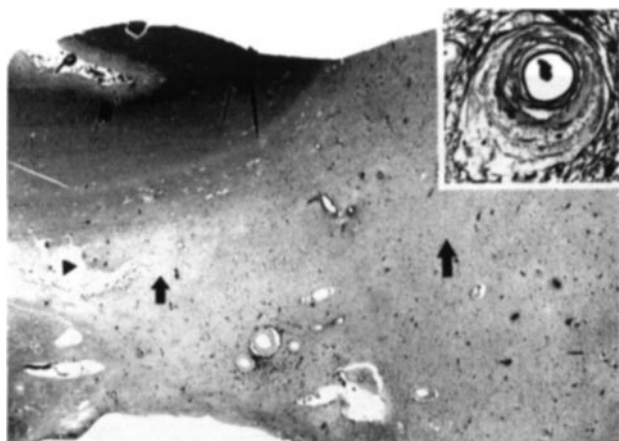


Fig 3: Pathology



**4 Migraine with aura** or complicated migraine is common in some patients and their families.<sup>3,5</sup>

Magnetic resonance imaging in CADASIL is always abnormal.<sup>3,4,5</sup> Extensive periventricular hyperintensities and

lacunar infarcts are seen. MRI abnormalities may also be seen in presymptomatic relatives. Multiple sclerosis can be differentiated from CADASIL by its distinct imaging and spinal fluid characteristics.

CADASIL is a systemic small vessel arteriopathy, but clinical manifestations are confined to the central nervous system.<sup>5,6</sup> Non-amyloid material is deposited in the media or small arteries in the brain and in other organs. Demonstration by electron microscopy of granular osmophilic deposits in the media of small arteries in skin biopsies is valuable in confirming the diagnosis.

Familial and sporadic CADASIL have been linked to Notch 3 gene mutation on chromosome 19. However, some CADASIL phenotypes do not have this genetic mutation.<sup>8</sup> The migraine — CADASIL link is supported by the finding that a gene for familial hemiplegic migraine has also been linked to Chromosome 19.<sup>9</sup> Genetic testing is now available for the diagnosis of CADASIL and the identification of presymptomatic carriers.

ACKNOWLEDGEMENTS: We thank The British Geriatrics Society for their support.

REFERENCES

- 1 Tournier-Lasserre E, Iba-Zizen M.T., Romero N. *et al.* Autosomal dominant syndrome with stroke-like episodes and leukoencephalopathy. *Stroke* 1991; 1297-1302.
- 2 Dichgans M., Mayer M., Uttner I *et al.*: The phenotypic spectrum of CADASIL: clinical findings in 102 cases. *Ann Neurol* 1998; 44:731-39.
- 3 Bousser M-G, Tournier-Lasserre (editorial) *J. Neurol Neurosurg. Psychiatry* 2001; 70:285-87.
- 4 Chabriat H., Levy C., Taillia H. *et al.* Patterns of MRI lesions in CADASIL. *Neurology* 1998; 51:452-57.
- 5 Rouchoux MM, Maurage CA: CADASIL: Cerebral autosomal dominant arteriopathy with subcortical infarcts and leukoencephalopathy; *J. Neuropathol Exp. Neurol* 1997; 56:947-64.
- 6 LaPoint S, Patel V., Rubio A. Cerebral autosomal dominant arteriopathy with subcortical infarcts and leukoencephalopathy (CADASIL) *Adv. in Anat Pathol.* 200.7 (5) 307-321.
- 7 Larsson C., Lardelli M., White I., Landahl U. The human Notch 3 mutations in CADASIL. *Nature* 1996; 373: 707-710.