

# Stroke after penetrating trauma of the oropharynx

MADELINE MATAR JOSEPH, MD, SUSAN LEWIS, MD

## INTRODUCTION

Intraoral trauma is a common childhood injury that can lead to serious vascular complications. Internal carotid artery thrombosis is a very rare complication that can cause catastrophic neurologic sequelae. We report a case of delayed onset of fever, seizure, and hemiplegia in a child after an intraoral injury caused by falling onto a glass vase.

## CASE

A 21-month-old boy was examined in the pediatric emergency department (ED) because of a new-onset seizure. Four days before admission, the patient fell with a glass vial in his mouth. The injury resulted in a small amount of bleeding from the mouth, which stopped promptly. Upon evaluation in a nearby hospital, the patient was found to have a severe laceration of the right tonsil, for which he underwent a right tonsillectomy. A 4-cm-long piece of glass was removed. Endoscopy (to detect any swallowed glass) and a four-vessel cerebral arteriogram were also performed; the results were unremarkable. The patient was discharged the next day and was reported to be doing well. Over the next 2 days, the patient was thought to be sleepier than usual, and, thus, his mother called the otolaryngologist. Because the patient did not have any fever and was eating fairly well, his sleepiness was attributed to the anesthetic agents used during surgery. On day 4 after the initial injury, the patient began vomiting, and then developed a generalized tonic-clonic seizure that lasted less than 5 minutes. The patient was transported to the hospital via rescue. On arrival at the ED, the patient was somnolent but could be aroused. His vital signs were remarkable for a temperature of 101.5°F. A healed scar in the right tonsillar pillar area was noted on the physical examination. The neurologic examination revealed a left hemiparesis with hyperactive deep tendon reflexes in the arm and leg and positive Babinski sign on the left. A computed tomography (CT) scan of the head revealed multifocal areas of low attenuation in the right parietal lobe in the distribution of the right middle cerebral artery consistent with a large ischemic infarction (Fig. 1). Carotid angiography showed complete occlusion of the right internal carotid artery (ICA) just above the common carotid artery bifurcation and numerous intraluminal defects in the supraclinoid ICA consistent with thrombi (Fig. 2). The left carotid angiography was normal. Laboratory findings were as follows: white blood cell count, 7.2; hemo-

globin/hematocrit, 10.5/30.9; hemoglobin electrophoresis, normal; platelet count, 420,000/ $\mu$ L; and blood chemistry within normal limits, including a blood glucose of 148 mg/dL. Blood and urine cultures were negative, and electrocardiogram was normal for the patient's age. A neurosurgical consultation was obtained. No interventions were recommended, and the patient received physical therapy during his hospitalization. He regained considerable strength in the left upper and lower limbs by the time of discharge 9 days later.

## DISCUSSION

Intraoral trauma is relatively common in children because they tend to put potentially dangerous objects in their mouth and then fall. Because the objects involved are often sharp items (eg, pencils, sticks, lollipops), these injuries have been named "pencil point" injuries (1). The vast majority of oral injuries are minor; therefore, they are not seen by medical personnel. Studies by Radkowski et al. (2) and Hellman et al. (3) reviewing oral trauma cases have shown that most of these injuries have no significant complications. Typical complaints of symptomatic children include transient oral bleeding and intraoral pain. Dysphasia, dysphonia, drooling, or subcutaneous emphysema in the submandibular region, upper thorax, or cervical triangle may indicate perforating laceration of the posterior oropharyngeal region (4). However, the potential for a serious neurologic catastrophe exists with any penetrating palatal trauma. ICA thrombosis with resultant neurologic deficit is a well-documented complication of both blunt and penetrating intraoral injuries in children and young adults. There have been 28 such cases reported in English literature since Caldwell (5) published the first case in 1936.

The first symptom in all patients is intraoral bleeding that generally is self-limited, except in the rare event of a palatine artery injury (6). If the ICA has been traumatized, patients develop irritability, vomiting, and drowsiness initially and generally manifest neurologic symptoms within 2 to 48 hours of injury (7–10). There have been reports of brief focal motor activity as a manifestation of ICA injury (7).

Often, there is no penetration of the vessel itself but, rather, compression of the ICA against the vertebrae or base of the skull causing an intimal tear that becomes the nidus for localized thrombogenesis (2). Usually, a 4- to 48-hour lucid interval ensues between the initial injury and development of neurologic deficits. The delay in occurrence of neurologic signs is caused by the time for formation and propagation of an intraluminal thrombus or embolization to occur. Distal extension to the circle of Willis leads to the development of the acute stroke syndrome within 24 to 48 hours. Typically, the middle cerebral artery is affected, resulting in contralateral hemiparesis. Other signs include blurred vision, hemianopsia, aphasia, hemiparesis or hemiplegia, focal motor seizures,

From the Department of Emergency Medicine, University of Florida Health Science Center, Jacksonville, Florida.

Address for reprints: Madeline Matar Joseph, MD, Director, Pediatric Emergency Medicine Fellowship Program, 655 West 8<sup>th</sup> Street, Jacksonville, FL 32209; e-mail: madeline.joseph@jax.ufl.edu

**Key Words:** Intraoral trauma, internal carotid artery, stroke

Copyright © Lippincott Williams & Wilkins. Unauthorized reproduction of this article is prohibited.

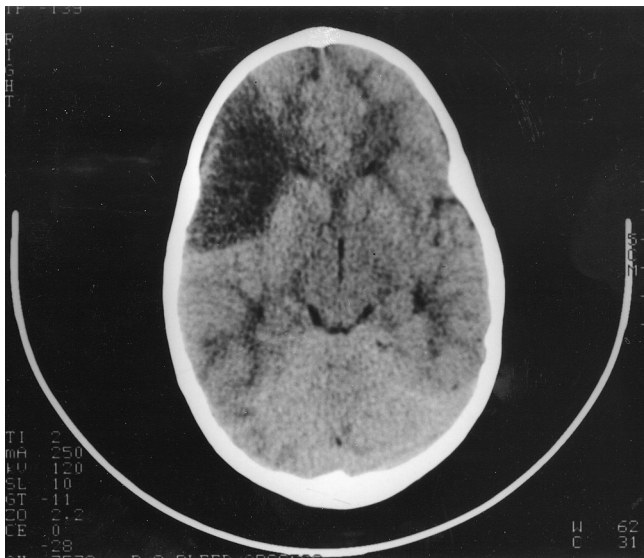


FIG. 1. Computed tomography scan showing multifocal areas of low attenuation in the right parietal lobe in the distribution of the right middle cerebral artery consistent with a large ischemic infarction.

and clouding of the sensorium (1, 2, 4, 11–14). Progression of the thrombus to the middle and anterior cerebral arteries may produce a large area of infarction, progressive edema, mass effect with transtentorial herniation, and death in some patients.

A few patients have developed immediate hemiparesis, possibly caused by a congenitally absent circle of Willis (12). Patients may also have elevated temperatures, because any intraoral wound greater than 1 cm in length has an increased risk of infection (15).

Our case is unique in that, although the patient developed some drowsiness within 48 hours as a possible sign of carotid artery insufficiency, he did not develop focal neurologic symptoms until 96

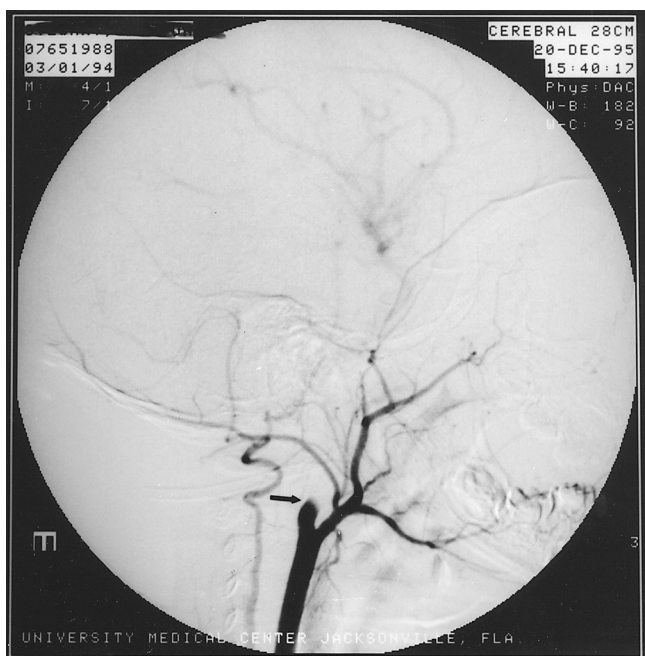


FIG. 2. Carotid angiography showing complete occlusion of the right internal carotid artery (ICA) just above the common carotid artery bifurcation and numerous intraluminal defects in the supraclinoid ICA consistent with thrombi.

hours after the initial injury. In addition, our patient arrived at the ED with fever and seizure; thus, febrile seizure and Todd paralysis were considered initially. Because of the patient's persistent lethargy, fever, and focal neurologic examination, a head CT scan was ordered to rule out a mass lesion such as an abscess. Vascular injury was thought unlikely at that time because of the delay between the seizure and the initial injury and the negative results of the cerebral arteriogram performed at the time of the injury.

Management of intraoral trauma in children remains controversial. A review of previous cases with ICA thrombosis has shown that thrombosis occurred only in cases in which the intraoral trauma involved the lateral palate region (13). It has thus been suggested that all patients with lateral palate region wounds should be admitted to the hospital for 48 hours. However, studies have since shown that the majority of children with trauma in this area do not develop ICA thrombosis, and, as shown by our case, admission for 48 hours may not cover the entire delay period (2, 3, 16). It is also not financially feasible to admit all children with intraoral trauma, because this is a rather common injury that almost never results in ICA thrombosis. Additionally, the severity, size, and shape of the penetrating wound are not predictive of potentially life-threatening sequelae. Admission from the ED should be reserved for those who have immediate symptoms, have an unreliable social situation, or require surgical repair. Others should be warned to return at the onset of any signs of vascular insufficiency such as drowsiness, irritability, or vomiting.

Our patient was not treated with any medications because of the prolonged period between the initial injury and the onset of symptoms. He underwent physical therapy, and he regained considerable strength in the left upper and lower limbs. He had a very mild limp at the time of discharge from the hospital 9 days after the initial injury.

Treatment modalities used in the past have included anticoagulation, surgical intervention, and supportive care. Because of the rarity of traumatic ICA thrombosis, it is unclear which treatment is the most appropriate. Anticoagulation with heparin has yielded contradictory results. Although Hengerer et al. (13) reported improvement in the patient's neurologic symptoms after anticoagulation was started, a case series of eight patients by Frantzen et al. (17) noted no difference in outcome whether or not the patient was treated with anticoagulation therapy (13–17). Some investigators have recommended antiplatelet therapy with aspirin (4). It remains to be seen whether the newer anticoagulants can be used in these patients. If anticoagulation is selected as the treatment of choice, it is important to rule out a dissecting injury with angiography before initiating treatment.

Surgical treatment has included thrombectomy, resection, and anastomosis and graft placement, with varying success. Both surgical and medical treatments seem to benefit patients with minimal or evolving neurologic deficits. Those with completed strokes are considered to be unlikely to respond (11). Unfortunately, at this point, no one treatment can be recommended over others, making it unlikely that the mortality rate of 30% can be reduced in the near future. Overall, 85% of those patients who survive will have permanent pareses (14, 18–20).

## CONCLUSIONS

In this case, ICA thrombosis leading to seizure and stroke occurred in a 21-month-old child 96 hours after intraoral trauma. Although this is a rare complication, warning signs of vascular insufficiency should be explained when discharging a patient with oral injury with no other symptoms.

**REFERENCES**

1. Bickerstaff ER. Aetiology of acute hemiplegia in childhood. *BMJ* 1964;2:82-87.
2. Radkowski D, McGill TJ, Healy GB, et al. Penetrating trauma of the oropharynx in children. *Laryngoscope* 1993;103:991-994.
3. Hellman JR, Shott SR, Gootee MJ. Impalement injuries of the palate in children: review of 131 Cases. *Int J Ped Otol* 1993;26:157-163.
4. Singer JI. Management strategy for penetrating oropharyngeal injury. *Pediatr Emerg Care* 1989;5:250-252.
5. Caldwell JA. Posttraumatic thrombosis of internal carotid artery: report of two cases. *Am J Surg* 1936;32:522-523.
6. Crawford BS. The management of perforating wounds of the palate. *Br J Plast Surg* 1970;23:262.
7. Braudo M. Thrombosis of internal carotid artery in childhood after injuries in region of soft palate. *BMJ* 1956;1:665-667.
8. Fairburn B. Thrombosis of the internal carotid artery after soft palate injury. *BMJ* 1957;2:750-751.
9. Mains B, Nagle M. Thrombosis of the internal carotid artery due to soft palate injury. *Laryngol Otol* 1989;103:796-797.
10. Woodhurst WB, Robertson WD, Thompson GB. Carotid injury due to intraoral trauma: case report and review of the literature. *Neurosurgery* 1980;6:559-563.
11. Higgens GL, Meredith JT. Internal carotid artery thrombosis following penetrating trauma of the soft palate: an injury of youth. *J Fam Pract* 1991;32:316-322.
12. Martin N, Warren GC. Thrombosis of the internal carotid artery due to intraoral trauma. *South Med J* 1969;62:103-107.
13. Hengerer AS, DeGroot TR, Rivers RJ, et al. Internal carotid artery thrombosis following soft palate injuries: a case report and review of 16 cases. *Laryngoscope* 1984;94:1571-1575.
14. Belfer RA, Ochsenschlager DW, Tomaski SM. Penetrating injury to the oral cavity: a case report and review of the literature. 1995;13:331-335.
15. Altieri M, Brasch L. Antibiotic prophylaxis in intraoral wounds. *Am J Emerg Med* 1986;4:507-510.
16. Domarus H, Poeschel W. Impalement injuries of the palate. *Plast Reconstr Surg* 1983;72:656-658.
17. Frantzen E, Jacobsen HH, Therkelsen J. Cerebral artery occlusion in children due to trauma to the head and neck. *J Neurol* 1961;11:695-700.
18. Graham WS, Schwartz JE, Stacy T. Stroke following oral trauma in children. *Ann Emerg Med* 1991;20:91029-91031.
19. Pearl PL. Childhood stroke following intraoral trauma. *J Pediatr* 1987; 110:574-575.
20. Rowley H, Christian J, Dennis A. Pharyngeal perforation: an easily missed finding following intraoral injury. *J Accid Emerg Med* 1995;12: 145-146.