

Middle cerebral artery aneurysm presenting as isolated hyperacusis

S. KHALIL, F.R.C.S., L. OGUNYEMI, F.R.C.S., J. OSBORNE, F.R.C.S.

Abstract

We present the first case of a middle cerebral artery aneurysm presenting as isolated hyperacusis. The patient had a Guglielmi detachable coil (GDC) embolization of his aneurysm with complete resolution of his symptoms. The pathophysiological mechanism is discussed. We suggest further radiological investigation in young patients presenting with this symptom.

Key words: Hyperacusis; Aneurysm; Middle Cerebral Artery

Introduction

Hyperacusis or phonophobia is used to describe an unusual hypersensitivity or discomfort induced by exposure to sound.¹ Hyperacusis may be due to either peripheral or central causes. Hyperacusis is an intriguing symptom that rarely confronts the otologist in isolation. It often accompanies tinnitus in patients with cochlear pathology. It has also been described in patients with Bell's palsy, Williams' syndrome, herpes zoster oticus, Lyme disease, myasthenia gravis, migraine, depression and other diseases.¹⁻⁷ We believe that this is the first case in the literature of an intracranial aneurysm presenting with hyperacusis. The otological presentations of intracranial aneurysms and pathophysiological mechanisms by which hyperacusis is produced are discussed.

Case report

A 35-year-old man presented to the out-patient department with a six-week history of hyperacusis. He described sounds suddenly becoming 'accelerated, exaggerated and very loud' in both ears. These episodes tended to last five to 10 minutes and were associated with nausea. They occurred approximately three to four times a week. He had no other otolaryngological symptoms and no past medical history of note. Ear, nose and throat examination was completely normal. Pure tone audiometry and tympanometry were normal. A magnetic resonance imaging (MRI) scan of his internal acoustic meati and posterior fossa was requested because of his unusual presentation. This revealed a large aneurysm approximately 4 × 3 cm arising from the right middle cerebral artery with a laminated thrombus within the aneurysmal sac and demonstrable flow beyond the aneurysm (Figures 1 and 2). Digital subtraction angiography showed the aneurysmal sac arising 1 cm distal to the origin of the middle cerebral artery (Figure 3).

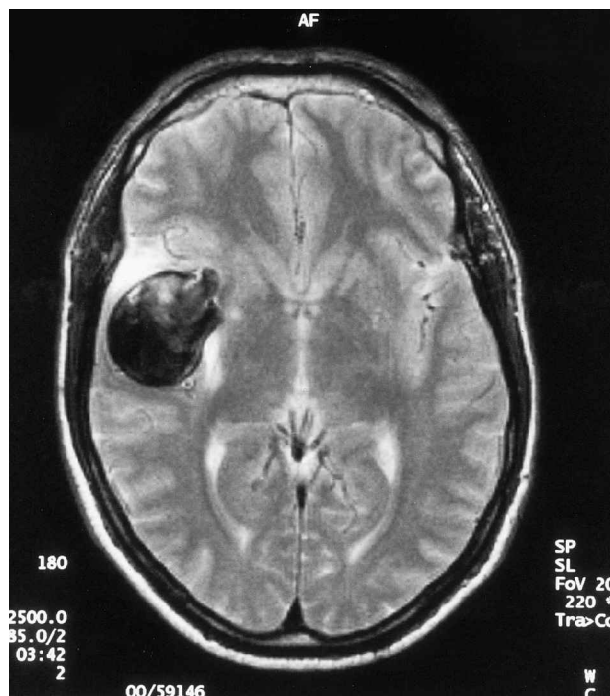


FIG. 1

Axial proton density T₂; showing a large aneurysm apparently arising from the right middle cerebral artery which measures 4 × 3 cm.

He was referred to the neurosurgical team and underwent GDC embolization of the aneurysm 12 days later. The procedure was uncomplicated and resulted in complete resolution of the hyperacusis. He remains asymptomatic 10 months after the operation.

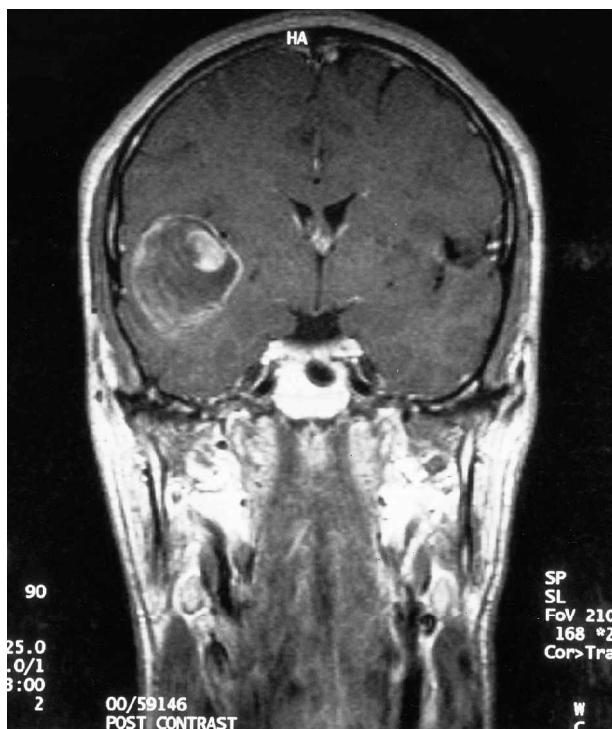

FIG. 2

Fine section coronal T₁ Post-gadolinium showing a large laminated thrombus within the aneurysmal sac which is of heterogeneous signal intensity.

Discussion

The middle cerebral artery enters the sylvian fissure and divides into two to four branches that supply the lateral parts of the cerebral hemisphere including the auditory cortex (Area 41 of Brodmann).⁸ Hence the afferent auditory pathways and auditory cortex are intimately associated with the middle cerebral arterial system.⁹ We postulate that the turbulent flow and pressure effects of a middle cerebral artery aneurysm irritated the nearby auditory cortex resulting in hyperacusis. This would be in keeping with the intermittent and brief nature of our patient's symptoms. The extensive crossover of auditory pathways at the brainstem explains the bilateral nature of his symptoms. The direct means by which hyperacusis is produced in the absence of cochlear pathology is unknown. Valente *et al.*⁶ speculate on the relation of hyperacusis to hypersensitivity of hearing or distortion of the neural coding of the auditory input causing abnormal growth in loudness, whilst central hyperacusis as advocated by Marriage and Barnes¹ in 1995 is due to reduction of serotonin metabolism within the forebrain. A middle cerebral artery aneurysm as we postulate could certainly produce distortion in auditory input and transient fluctuations in serotonin metabolism. Central hyperexcitability⁷ increased central gain¹⁰ and failure of the central nervous system to habituate to the startle response⁴ are other theories regarding the mechanism by which hyperacusis is produced. Most work on hyperacusis evolves from its association with tinnitus and it is less researched in its own right. Hyperacusis may be evaluated with measurements of loudness discomfort levels.^{1,6} Other investigations often depend on accompanying otological symptoms. Intracranial aneurysms are estimated to occur in about 0.2–9.9 per cent of the population.^{11–13} Unruptured intracranial aneurysms usually present with symptoms suggestive of raised intracranial pressure such as headaches, nausea, vomiting and blurring of vision or with cranial nerve

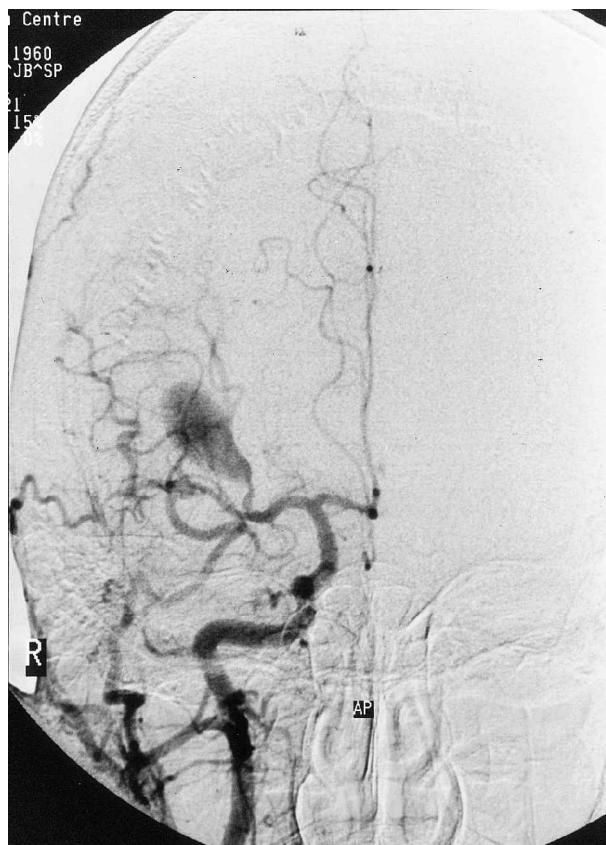

FIG. 3

Digital subtraction angiography showing the aneurysm arising from the right middle cerebral artery about 1 cm distal to its origin.

deficits, embolic ischaemia and mass effects.¹² Herald leaks of a subarachnoid haemorrhage are a late feature. Otological presentations are extremely uncommon. Pulsatile tinnitus is the most frequent otological manifestation with an anterior inferior cerebellar artery (AICA) aneurysm followed by a sigmoid sinus aneurysm as common culprits.^{14–16} Other reported otological presentations include vertigo, progressive and sudden sensorineural hearing loss. The management of unruptured aneurysms has been extensively debated in recent literature with most authors in favour of surgical intervention once they fulfil size criteria.^{11–13,17–19} The form of surgical intervention may be clipping of the aneurysm or, as in our case, embolization by a neuroradiologist.^{17–19}

This unique case suggests that in any young patient presenting with unexplained auditory symptoms further radiological investigation should be considered.

References

- 1 Marriage J, Barnes NM. Is central hyperacusis a symptom of 5-hydroxytryptamine (5-HT) dysfunction? *J Laryngol Otol* 1995;**109**:915–21
- 2 Adour KK. Diagnosis and management of facial paralysis. *N Eng J Med* 1982;**307**:348–51
- 3 Wayman DM, Pham HN, Byl BM, Adour KK. Audiological manifestation of Ramsay Hunt syndrome. *J Laryngol Otol* 1990;**104**:104–8
- 4 Klein A, Armstrong B, Greer M, Brown F. Hyperacusis and otitis media in individuals with Williams syndrome. *J Speech Hear Disord* 1990;**55**:339–44
- 5 Behan PO, Bakheit AMO. Clinical spectrum of postviral fatigue syndrome. *Br Med Bull* 1991;**47**:739–808

- 6 Valente M, Goebel J, Duddy D, Sinks B, Peterein J. Evaluation and treatment of severe hyperacusis. *J Am Acad Audiol* 2000;**11**:295–9
- 7 Phillips DP, Carr MM. Disturbances of loudness perception. *J Am Acad Audiol* 1998;**9**:371–9
- 8 Phillips DP, Williams PL. Angiography. In: Warwick R, Williams PL, eds. *Gray's Anatomy* 35th edn. Edinburgh: Longman, 1973;637–8
- 9 Wright T. Anatomy and development of the ear and hearing. In: Ludman H, Wright T, eds. *Diseases of the Ear*. 6th edn. London: Arnold 1998;29
- 10 Jastreboff PJ, Hazell JW. A neurophysiological approach to tinnitus: clinical implications. *B J Audiol* 1993;**27**:7–17
- 11 International study of unruptured aneurysms investigators. Unruptured intracranial aneurysms: Risk of rupture and risk of surgical intervention. *N Engl J Med* 1998;**339**:1725–33
- 12 Wiebers DO, Whisnant JP, O'Fallon WM. The natural history of unruptured intracranial aneurysms. *N Engl J Med* 1981;**304**:696–8
- 13 Flamm ES, Grigorian AA, Macrovi A. Multifactorial analysis of surgical outcome in patients with unruptured middle cerebral artery aneurysms. *Ann Surg* 2000;**232**:570–5
- 14 Spallone A, De Santis S, Giuffre R. Peripheral aneurysms of the anterior inferior cerebellar artery. Case report and review of literature. *Br J Neurosurg* 1995;**9**:537–41
- 15 Kinney WC, Kinney SE, Perl J, Lind, Lee JH, Chyatte D, Miller DW, et al. Rare lesions of the posterior fossa with initial retrocochlear auditory and vestibular complaints. *Am J Otol* 1997;**18**:373–80
- 16 Banczerowski P, Sipos L, Vajda J. Aneurysm of the internal auditory artery: our experience and review of the literature. *Acta Neurochir* 1996;**138**:1157–62
- 17 Dovey Z, Misra M, Thornton J, Charbel FT, Debrun GM, Ausman JL. Guglielmi detachable coiling for intracranial aneurysms: the story so far. *Arch Neurol* 2001;**58**:559–64
- 18 Vinuela F, Duckwiler G, Mawad M. Guglielmi detachable coil embolization of acute intracranial aneurysm: perioperative anatomical and clinical outcome in 403 patients. *J Neurosurg* 1997;**86**:475–82
- 19 Heiskanen O, Poranen A. Surgery of incidental intracranial aneurysms. *Surg Neurol* 1987;**28**:432–6

Address for correspondence:
 Mr J. Osborne, F.R.C.S.,
 Department of Otolaryngology,
 Glan Clwyd Hospital,
 Bodelwyddan, Denbighshire, LL18 5UJ, UK.

Fax: 01745534160
 E-mail: Jon.Osborne@cd-tr.wales.nhs.uk

Mr J Osborne takes responsibility for the integrity of the content of the paper.
 Competing interests: None declared
