

Seizure at Stroke Onset: Should It Be an Absolute Contraindication to Thrombolysis?

Magdy Selim Sandeep Kumar John Fink Gottfried Schlaug
Louis R. Caplan Italo Linfante

Department of Neurology, Division of Cerebrovascular Diseases, Beth Israel Deaconess Medical Center, Boston, Mass., USA

Key Words

Stroke · Magnetic resonance imaging · Diffusion-weighted images · Perfusion-weighted images · Tissue plasminogen activator · Seizures

Abstract

Background: Current guidelines for the treatment of acute ischemic stroke exclude patients with seizure at stroke onset from consideration for thrombolytic therapy. It may be difficult to differentiate an ischemic stroke from postictal Todd's paralysis by clinical examination and noncontrast CT scan. Magnetic resonance imaging (MRI) with diffusion- (DWI) and perfusion-weighted images (PWI) and angiography (MRA) can be used to confirm the diagnosis of an acute ischemic process in the presence of concurrent seizures. **Methods:** A case report of a patient who presented with seizures, in whom the combination of DWI/PWI MRI and MRA confirmed the diagnosis of an embolic ischemic stroke. The patient was treated with intravenous recombinant tissue plasminogen activator with clinical and radiological improvement.

Conclusions: Treatment decisions with regard to thrombolysis in acute stroke patients should be based on parameters of cerebral perfusion, assessment of collateral blood flow and presence of potentially salvageable tissue. Modern neuroimaging techniques that can rapidly assess these variables, such as DWI/PWI MRI and MRA, can improve the current selection of patients who are likely to benefit from thrombolysis and extend its benefit to patients who would otherwise be excluded, such as those with seizures at stroke onset.

Copyright © 2002 S. Karger AG, Basel

Introduction

Current treatment guidelines for acute ischemic stroke list 'seizure at onset' as an exclusion criterion for the use of recombinant tissue plasminogen activator (rt-PA) [1, 2]. Occasional patients, with acute ischemic stroke, present with seizures at stroke onset [3]. It may be difficult to differentiate an ischemic stroke from postictal Todd's paralysis by clinical examination and noncontrast CT scan. Magnetic resonance imaging (MRI) with sequences that include diffusion- (DWI) and perfusion-weighted images (PWI) and angiography (MRA) allows

The authors have no conflicts of interest to declare.

KARGER

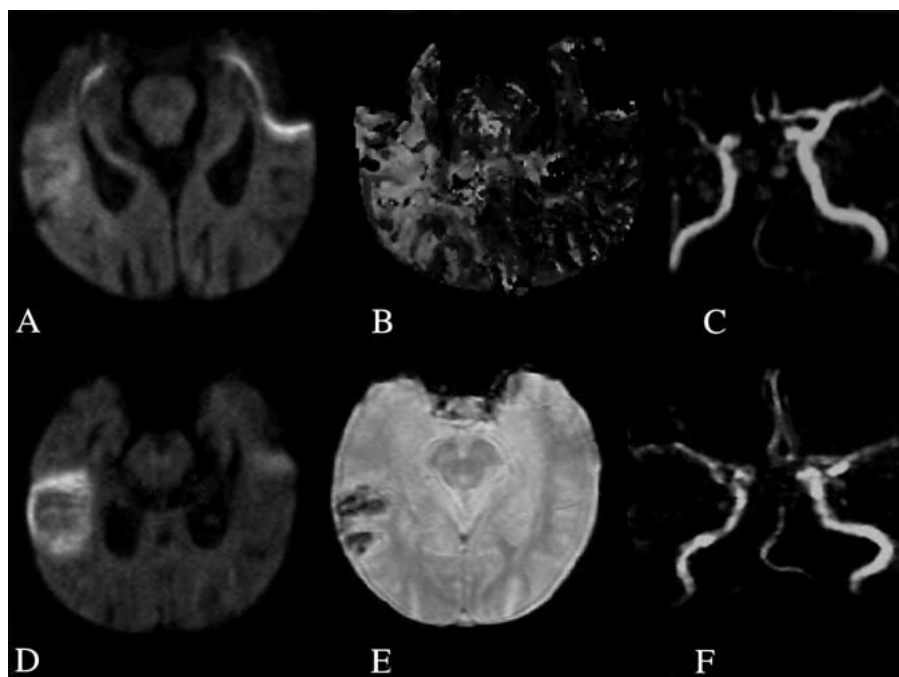
Fax +41 61 306 12 34
E-Mail karger@karger.ch
www.karger.com

© 2002 S. Karger AG, Basel
1015-9770/02/0141-0054\$18.50/0

Accessible online at:
www.karger.com/journals/ced

Magdy H. Selim, MD, PhD
University of Massachusetts Medical School, Department of Neurology
UMass Memorial Medical Center, 119 Belmont Street
Worcester, MA 01605 (USA)
Tel. +1 508 334 6641, Fax +1 508 334 6695, E-Mail selimm@ummhc.org

Fig. 1. MRI findings at 120 min from symptom onset (A–C) and at 24 h after treatment with intravenous rt-PA (D–F). A Axial DWI showing restricted diffusion (increased signal) in the right temporoparietal region. B PWI, relative mean transit time map, showing a large area of hypoperfusion in the right cerebral hemisphere. C MRA showing cut-off of the M1 segment of the right middle cerebral artery, consistent with occlusion. D DWI showing evolution of the right temporoparietal diffusion abnormality, 24 h after thrombolysis, without significant increase in size. E Susceptibility-weighted image showing hemorrhagic transformation within the area of infarction. F MRA showing recanalization of the right middle cerebral artery.



identification of ischemic tissue and the corresponding arterial occlusion within the 3-hour window for thrombolysis [4]. We now report a patient with an ischemic stroke who presented with seizures, in whom DWI/PWI and MRA showed the presence of an arterial occlusion and acute ischemic tissue. The patient was successfully treated with intravenous rt-PA.

Case Report

An 86-year-old woman with a history of hypertension, hyperlipidemia, coronary artery disease and atrial flutter developed seizures characterized by ‘jerking of her right arm and leg and immediate unresponsiveness’, witnessed by her internist during a routine follow-up office visit. She was immediately rushed to our emergency department, where she was thought to have a focal motor seizure with secondary generalization. She received intravenous lorazepam and phenytoin that aborted her clonic activity. Her medications included moexipril, nitroglycerine, digoxin and furosemide. She had no history of prior strokes or seizures. She lived alone, independently. She did not smoke and rarely consumed alcohol.

On examination, her temperature was 37.2 C°, blood pressure 180/60 mm Hg and pulse 100 beats/min and regular. Her cardiac and general examinations were normal. On neurological examination, she was unarousable. She grimaced and withdrew the right side in response to nail bed pressure. Her eyes were deviated to the right. Oculocephalic reflexes were intact. Her pupils were regular with a sluggish response to light. She had weakness of the left lower face.

Her left arm and leg were flaccid and plegic. She had a Babinski’s sign on the left. Her Glasgow Coma Score was 6; the National Institute of Health Stroke Scale score was 21.

Routine blood counts and chemistries were normal. Noncontrast CT of the head, within 90 min after symptom onset, excluded hemorrhage and did not show early signs of ischemia. An EEG showed diffuse slowing and frequent right temporal spikes, without evidence of ongoing seizure activity.

The possibility of stroke with seizure at onset was entertained given the discrepancy between her presentation and focal examination, i.e. right-sided seizures and left-sided long tract signs and hemiplegia. DWI, 120 min after symptom onset, revealed increased signal intensity in the right posterior frontal, temporoinsular and occipital cortex (fig. 1A); PWI showed delayed arrival of the contrast to the right hemisphere, and an area of hypoperfusion larger than the diffusion lesion (fig. 1B). Intracranial MRA showed decreased flow in the right internal carotid artery and cutoff of the M1 segment of the right middle cerebral artery (fig. 1C). The right posterior cerebral artery originated from the internal carotid artery. She was treated with intravenous rt-PA (total dose = 57.2 mg; 5.7 mg as a bolus over 1 min and 51.5 mg as an infusion over 60 min) within 150 min from symptom onset. Follow-up MRI, 24 h later, showed a small region of hemorrhagic transformation within the infarct (fig. 1D, E) and recanalization of the right middle cerebral artery (fig. 1F).

Her neurological status gradually improved. She was discharged a week later. At discharge, she had a left homonymous hemianopia and slightly impaired short-term memory. Her National Institute of Health Stroke Scale score was 5, with a modified Rankin scale score of 1.

Discussion

To date, intravenous rt-PA remains the only medication approved by the Food and Drug Administration for treatment of acute ischemic stroke [5, 6]. The narrow 3-hour 'therapeutic window' and a list of exclusion criteria, however, limit its use to only a minority of acute stroke patients. Published guidelines for thrombolytic therapy for acute stroke recommend that a CT scan should be performed prior to the administration of rt-PA and exclude patients who exhibit seizures at stroke onset from consideration for thrombolysis, since the diagnosis of stroke in this setting may be difficult to distinguish from Todd's paralysis [1, 2]. The frequency of seizures during the first 24 h of an ischemic stroke is estimated to be <3% [7]. Nonenhanced CT is of limited value in this setting, since early signs of ischemia are often subtle [8].

Although stroke is primarily a clinical diagnosis, cerebral imaging studies during the acute phase can play a crucial role in selecting patients who may be candidates for rt-PA. Several recent advanced cerebral imaging strategies can provide information to ascertain the presence of an ischemic process, assess its hemodynamics and estimate the tissue at risk [9–13]. The combination of DWI/PWI MRI coupled with MRA can identify the extent of infarcted tissue soon after the onset of stroke and permits simultaneous characterization of hypoperfused tissue at risk for infarction, major vessel occlusion and regional cerebral blood flow during the hyperacute phase of stroke [4, 14, 15]. Emerging evidence suggests that DWI/PWI MRI can have a substantial impact on patient selection for thrombolysis and can possibly be used to extend the current 3-hour time window for tPA on a patient-by-patient basis [16, 17].

This patient illustrates the usefulness of combined DWI/PWI and MRA in confirming the diagnosis of acute ischemia in the setting of concurrent seizures. One might argue that signal changes on DWI can be seen during epileptic seizures [18]. However, they do not correspond to a vascular territory as in the present case. Furthermore, the presence of concomitant PWI signal changes in the territory of a documented arterial occlusion is highly suggestive of ischemia. In contrast, studies using single-photon emission CT show an increase in regional perfusion during epileptic seizures [19]. The Copenhagen Stroke Study suggested that seizure at stroke onset might signify a large area of hypoperfused, but potentially salvageable tissue [20]. The findings in our patient support this hypothesis. Such patients would likely benefit from early reperfusion.

It is important to recognize that involuntary movements of the limbs can occasionally be seen in patients with acute stroke [21]. These movements may include intermittent shaking and jerky movements, and may be reported by witnesses as 'seizures'. The simultaneous impairment of consciousness in our patient suggests that the observed movements were epileptic in nature.

This single-case report highlights the potential value of multimodal MRI sequences, in improving diagnosis, management and prognosis of acute stroke patients. It may also provide a rationale to revise current exclusion criteria for thrombolysis (i.e. seizure at onset, hypoglycemia and hyperglycemia) since, when in doubt, the diagnosis of ischemic tissue may be supported by the imaging study. Modern neuroimaging techniques, which can rapidly assess the status of cerebral vasculature, collateral blood flow and presence of ischemic tissue, such as this multiple MRI sequence, can improve the selection of patients who are likely to benefit from thrombolysis.

Acknowledgments

G.S. is presently supported by grants from the Fireman and Rubenstein Foundations and the Doris Duke Clinical Scientist Development Award. J.F. is supported by the New Zealand Neurological Foundation V.J. Chapman Fellowship Grant.

References

- 1 Quality Standards Subcommittee of the American Academy of Neurology: Practice advisory: Thrombolytic therapy for acute ischemic stroke – Summary statement. *Neurology* 1996; 47:835–839.
- 2 Adams HP, Brott TG, Furlan AJ, Gomez CR, Grotta J, Helgason CM, Kwiatkowski T, Lyden D, Marler JR, Torner J, Feinberg W, Mayberg M, Thies W: Use of thrombolytic drugs: A supplement to the guidelines for the management of patients with acute ischemic stroke. A statement for health care professionals from a special writing group of the stroke council American Heart Association. *Stroke* 1996;27:1711–1718.
- 3 Szaflarski JP, Woo D, Kissela BM, Cahill WT, Miller R, Khoury J, Broderick JP: The incidence of seizures after acute stroke: A preliminary report. *Abstr 125th ANA Meet, Boston, 2000.*
- 4 Schellinger PD, Jansen O, Fiebach JB, Pohlers O, Ryssel H, Heiland S, Steiner T, Hacke W, Sartor K: Feasibility and practicality of MR imaging of stroke in the management of hyperacute cerebral ischemia. *Am J Neuroradiol* 2000;21:1184–1189.
- 5 Activase, alteplase recombinant for acute ischemic stroke: Efficacy supplement. Peripheral and Central Nervous System Drug Advisory Committee Meeting, Bethesda, June 1996.
- 6 The National Institute of Neurological Disorders and Stroke rt-PA Stroke Study Group: Tissue plasminogen activator for acute ischemic stroke. *N Engl J Med* 1995;333:1581–1587.
- 7 So EL, Annegers JF, Hauser WA, O'Brien PC, Whisnant JP: Population-based study of seizure disorders after cerebral infarction. *Neurology* 1996;46:350–355.
- 8 Grotta JC, Chiu D, Lu M, Patel S, Levine SR, Tilley BC, Brott TG, Haley EC, Lyden PD, Kothari R, Frankel M, Lewandowski CA, Libman R, Kwiatkowski T, Broderick JP, Marler JR, Corrigan J, Huff S, Mitsias P, Talati S, Tanne D: Agreement and variability in interpretation of early CT changes in stroke patients qualifying for intravenous rtPA therapy. *Stroke* 1999;30:1528–1533.
- 9 Marchal G, Beaudouin V, Rioux P, de la Sayette V, Le Doze F, Viader F, Derlon JM, Baron JC: Prolonged persistence of substantial volumes of potentially viable brain tissue after stroke: A correlative PET-CT study with voxel-based data analysis. *Stroke* 1996;27:599–606.
- 10 Karonen JO, Vanninen RL, Liu Y, Ostergaard L, Kuikka JT, Nuutinen J, Vanninen EJ, Partanen PL, Vainio PA, Korhonen K, Perkio J, Siveniu SJ, Aronen HJ: Combined diffusion and perfusion MRI with correlation to single-photon emission CT in acute ischemic stroke: Ischemic penumbra predicts growth infarct. *Stroke* 1999;30:1583–1590.
- 11 Rubin G, Levy EI, Scarrow AM, Firlik AD, Karakus A, Wechsler L, Jungreis CA, Yonas H: Remote effects of acute ischemic stroke: A xenon CT cerebral blood flow study. *Cerebrovasc Dis* 2000;10:221–228.
- 12 Sakoh M, Ostergaard L, Rohl L, Smith DF, Simonsen CZ, Sorensen JC, Poulsen PV, Gyldested C, Sakaki S, Gjedde A: Relationship between residual cerebral blood flow and oxygen metabolism as predictive of ischemic tissue viability: Sequential multitracer positron emission tomography scanning of middle cerebral artery occlusion during the critical first 6 hours after stroke in pigs. *J Neurosurg* 2000;93:647–657.
- 13 Mayer TE, Hamann GF, Baranczyk J, Rosengarten B, Klotz E, Wiesmann M, Missler U, Schulte-Altedonneburg C, Brueckmann HJ: Dynamic CT perfusion imaging of acute stroke. *Am J Neuroradiol* 2000;21:1441–1449.
- 14 Grandin CB, Duprez TP, Smith AM, Mataligne F, Peeters A, Oppenheim C, Cosnard G: Usefulness of magnetic resonance-derived quantitative measurements of cerebral blood flow and volume in prediction of infarct growth in hyperacute stroke. *Stroke* 2001;32:1147–1153.
- 15 Schellinger PD, Jansen O, Fiebach JB, Heiland S, Steiner T, Schwab S, Pohlers O, Ryssel H, Sartor K, Hacke W: Monitoring intravenous recombinant tissue plasminogen activator thrombolysis for acute ischemic stroke with diffusion and perfusion MRI. *Stroke* 2000;31:1318–1328.
- 16 Schellinger PD, Fiebach JB, Mohr A, Ringleb PA, Jansen O, Hacke W: Thrombolytic therapy for ischemic stroke – A review. II. Intra-arterial thrombolysis, vertebrobasilar stroke, phase IV trials, and stroke imaging. *Crit Care Med* 2001; 29:1819–1825.
- 17 Albers GW: Advances in intravenous thrombolytic therapy for treatment of acute stroke. *Neurology* 2001;57(suppl 5):S77–81.
- 18 Diehl B, Najm I, Ruggieri P, Foldvary N, Mohamed A, Tkach J, Morris H, Barnett G, Fisher E, Duda J, Luders HO: Perictal diffusion-weighted imaging in a case of lesional epilepsy. *Epilepsia* 1999;40:1667–1671.
- 19 Lamy C, Derambure P, Josien E, Destee A, Vermesch P, Leduc V, Steinling M: Factors playing a role in the increase of localized perfusion observed by SPECT during an epileptic seizure. *Rev Neurol (Paris)* 2000;156:1113–1119.
- 20 Reith J, Jorgensen HS, Nakayama H, Raaschou HO, Olsen TS: Seizures in acute stroke: Predictors and prognostic significance. The Copenhagen Stroke Study. *Stroke* 1997;28: 1585–1589.
- 21 Saposnik G, Caplan LR: Convulsive-like movements in brainstem stroke. *Arch Neurol* 2001;58:654–657.