

Anterior Transpetrosal Approach for Pontine Cavernous Angioma

—Case Report—

Nobuhito SAITO^{*,**}, Tomio SASAKI^{*,**}, Emiko CHIKUI^{**},
Ryuji YUYAMA^{**}, and Takaaki KIRINO^{**}

^{*}Department of Neurosurgery, Gunma University School of Medicine, Maebashi, Gunma;

^{**}Department of Neurosurgery, University of Tokyo Hospital, Tokyo

Abstract

A 58-year-old male patient presented with headache and unsteady gait. Magnetic resonance imaging revealed hemorrhage from a pontine cavernous angioma. The patient experienced stepwise aggravation of symptoms due to repeated hemorrhages. We decided to surgically remove the pontine cavernous angioma through an anterior transpetrosal approach, since the angioma and hematoma were located near the ventrolateral surface of the pons. The brain stem was incised at a site caudal to the trigeminal nerve and the hematoma and angioma were totally removed. No additional neurological deficits were observed following surgery. Brain stem cavernous angiomas are usually removed via a trans-fourth ventricle or lateral suboccipital approach. However, these approaches may not be appropriate if the angioma is located ventrally to the pons. We propose that the anterior transpetrosal approach is the method of choice for ventrally located pontine cavernous angioma.

Key words: cavernoma, brain stem, surgical approach

Introduction

Cavernous angiomas in the brain stem require surgical intervention when the clinical symptoms of the patient deteriorate due to repeated hemorrhages.⁴⁾ The surgical approach necessitates an incision in the brain stem, carrying the risk of aggravating the neurological deficits of the patient. The surgery is hazardous and challenging, since vital nuclei and fasciculi are densely packed in this small region. Therefore, the surgical approach must be carefully planned to identify the most accessible route and minimize injury to the brain stem. Removal of the angioma is not technically very difficult in most cases, because the boundary between the angioma and normal brain stem tissue is typically well demarcated.

Most brain stem cavernous angiomas were removed via a trans-fourth ventricle or lateral suboccipital approach.^{1-3,5,9-11,13-15)} However, these approaches may not be appropriate if the angioma is located ventrally to the pons. We describe a case of

ventral pontine cavernous angioma, which was successfully removed through an anterior transpetrosal approach.

Case Report

A 58-year-old male patient experienced headache and unsteady gait on October 7, 1997. He developed dysarthria on October 18 and was admitted to another hospital, where computed tomography without contrast medium revealed a high-density mass lesion in the pons. The patient was transferred to our department for further studies.

On admission, neurological examination revealed truncal ataxia, nystagmus on left gaze, and dysarthria. Magnetic resonance (MR) imaging revealed a pontine lesion appearing as a heterogeneous intensity mass measuring $2.0 \times 2.2 \times 2.0$ cm. The diagnosis was hemorrhage from a cavernous angioma. In addition, MR imaging revealed multiple supra- and infratentorial lesions, some depicted as heterogeneous intensity lesions and others as low intensity dots, suggesting the presence of multiple cavernous angiomas. Cerebral angiography revealed no vascular malformations. Conservative treatment was

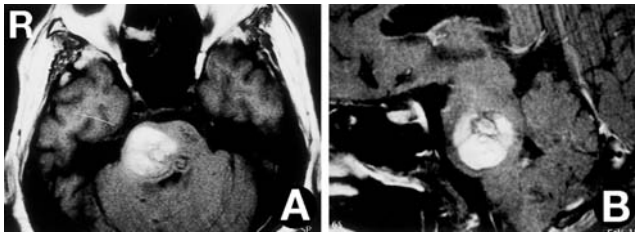


Fig. 1 Preoperative T₁-weighted magnetic resonance images, axial view (A) and sagittal view (B), showing a pontine cavernous angioma and hematoma.

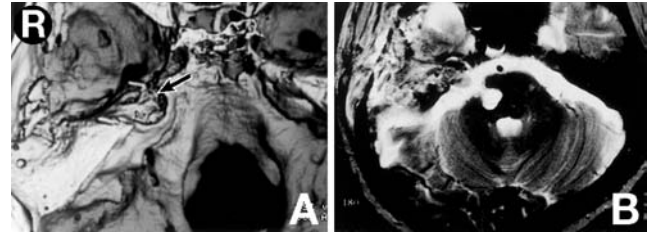


Fig. 3 (A) Postoperative three-dimensional computed tomography scan indicating the extent of drilling of the petrous apex (arrow). (B) Postoperative T₂-weighted magnetic resonance image showing total removal of the hematoma and angioma.

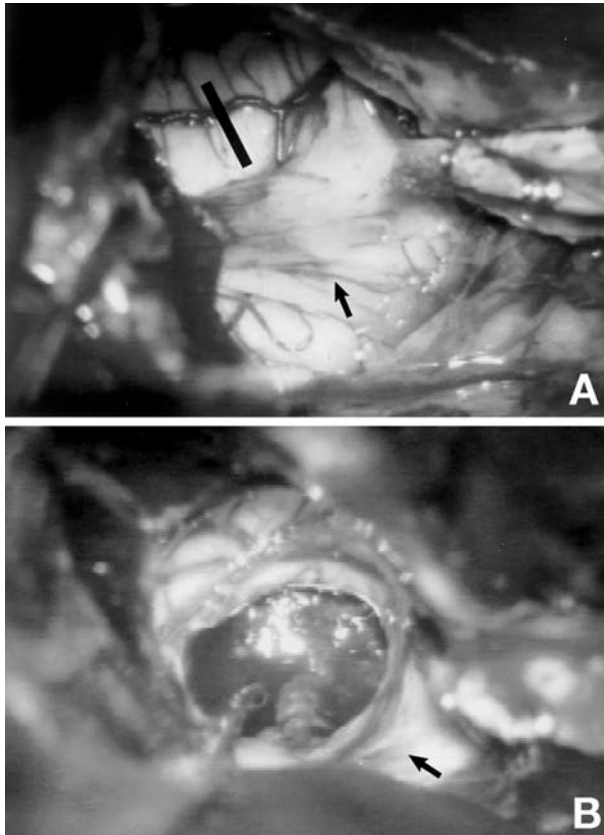


Fig. 2 Intraoperative photographs of the right ventrolateral pons through the anterior transpetrosal approach before (A) and after (B) removal of the angioma. The incision was made as indicated by the line. arrow: Right trigeminal nerve.

chosen. However, the patient experienced stepwise aggravation of symptoms, to paresthesia of the face and left limbs on October 27, and motor weakness in the left limbs on November 7. MR imaging revealed expansion of the pontine hematoma, suggesting rebleeding from the cavernous angioma (Fig. 1). As

his symptoms were deteriorating due to repeated hemorrhages, the decision was made to remove the pontine cavernous angioma.

The patient underwent surgical removal of the cavernous angioma on November 25, 1997. Intraoperative lumbar drainage was used to minimize brain damage due to retraction. With the patient in a supine lateral position, right temporal craniotomy was performed. The dura mater was dissected from the floor of the middle cranial fossa. The middle meningeal artery was cauterized and divided. The petrous apex was exposed extradurally, preserving the greater superficial petrosal nerve. The petrous apex was drilled out along the greater superficial petrosal nerve medially to the trigeminal notch posteriorly as far as just medial to the gasserian ganglion. The internal auditory canal, geniculate ganglion, and internal carotid artery were not exposed. The dura over the temporal lobe was opened and the temporal lobe was retracted intradurally. The dura of the middle cranial fossa floor was divided perpendicularly toward the posterior cranial fossa and the cerebellar tentorium was also divided. The superior petrosal sinus was clipped and divided, and the posterior cranial fossa dura was opened. This approach visualized both the rostral and caudal aspects of the trigeminal nerve. The pons was swollen and the basilar artery was not identified. The brain stem was incised at a site caudal to the trigeminal nerve (Fig. 2). The cavernous angioma and hematoma were exposed and totally removed. After removal of the angioma, dural plasty was performed using temporal muscle fascia. The bone defect of the petrous apex was filled with a muscle piece and sealed with fibrin glue.

Postoperative neuroimaging studies confirmed total removal of the angioma (Fig. 3). No additional neurological deficits were observed following surgery.

Discussion

Most pontine cavernous angiomas have been treated via a trans-fourth ventricle approach.^{1-3,9-11,13-15} This approach involves opening the floor of the fourth ventricle and carries the risk of injury to the nuclei and fasciculi of the cranial nerves VI, VII, and VIII in this region. Facial nerve paresis, abducens nerve paresis, eye movement disorder, mutism, and peduncular hallucination have occurred as complications.^{1,10,13,14} The supra- and infrafacial triangles may be safe entry zones to the floor of the fourth ventricle.⁸ However, this approach is still not suitable if the cavernous angioma is localized ventrally to the pons.

Other possible approaches for brain stem cavernous angiomas include a lateral suboccipital approach for lateral pontine lesions^{1,5} and an infratentorial supracerebellar approach for dorsal midbrain lesions.^{1,3} Hearing loss and hemiparesis are complications of the lateral suboccipital approach.¹ A subtemporal approach for ventral upper pons cavernous angioma can expose the ventral aspects of the midbrain and upper pons but does not visualize the caudal aspect of the pons.^{2,3} A trans-oral trans-clival approach has been utilized to visualize the ventral brain stem directly.¹² However, the operative field is very narrow and involves a high risk of cerebrospinal fluid leakage.

The anterior transpetrosal approach of Kawase provides a view of the ventrolateral aspect of the pons, and is useful in the surgical management of petroclival meningioma and lower basilar artery aneurysm.^{6,7} In the present case, we used this approach to successfully remove a ventral pontine cavernous angioma. The approach provided a wide view of the ventral pons and the patient experienced no additional neurological deficit, but rather improvement after surgery. Pontine cavernous angiomas can be classed into six groups according to location.² The sagittal transpontine access medial to the trigeminal nerve was proposed for safe access to the ventral mid-pons. Our case was approached via this route, indicating that this approach is a relatively safe route when the angioma is located near the surface. To access this region, an anterior transpetrosal approach is preferable to a lateral suboccipital approach because stretching of cranial nerves V, VII, and VIII is avoided.

In conclusion, we propose that the anterior transpetrosal approach is the method of choice for ventrally located pontine cavernous angioma.

References

- 1) Bertalanffy H, Gilsbach JM, Eggert HR, Seeger W: Microsurgery of deep-seated cavernous angiomas: report of 26 cases. *Acta Neurochir (Wien)* 108: 91-99, 1991
- 2) Cantore G, Missori P, Santoro A: Cavernous angiomas of the brain stem. Intra-axial anatomical pitfalls and surgical strategies. *Surg Neurol* 52: 84-93, 1999
- 3) Fahlbusch R, Strauss C, Huk W: Pontine-mesencephalic cavernomas: indications for surgery and operative results. *Acta Neurochir Suppl (Wien)* 53: 37-41, 1991
- 4) Fritschi JA, Reulen HJ, Spetzler RF, Zabramski JM: Cavernous malformations of the brain stem. A review of 139 cases. *Acta Neurochir (Wien)* 130: 35-46, 1994
- 5) Heffez DS, Zinreich SJ, Long DM: Surgical resection of intrinsic brain stem lesions: an overview. *Neurosurgery* 27: 789-797, 1990
- 6) Kawase T, Shiobara R, Toya S: Anterior transpetrosal-transtentorial approach for sphenopetroclival meningiomas: surgical method and results in 10 patients. *Neurosurgery* 28: 869-875, 1991
- 7) Kawase T, Toya S, Shiobara R, Mine T: Transpetrosal approach for aneurysms of the lower basilar artery. *J Neurosurg* 63: 857-861, 1985
- 8) Kyoshima K, Kobayashi S, Gibo H, Kuroyanagi T: A study of safe entry zones via the floor of the fourth ventricle for brain-stem lesions. Report of three cases. *J Neurosurg* 78: 987-993, 1993
- 9) LeDoux MS, Aronin PA, Odrezin GT: Surgically treated cavernous angiomas of the brain stem: report of two cases and review of the literature. *Surg Neurol* 35: 395-399, 1991
- 10) Nakagawa H, Furuta Y, Nakajima S, Murasawa A, Nakajima Y: Surgical excision of familial cavernous angioma in the pontomedullary region: case report. *Neurol Med Chir (Tokyo)* 30: 422-427, 1990
- 11) Ogata N, Yonekawa Y: Paramedian supracerebellar approach to the upper brain stem and peduncular lesions. *Neurosurgery* 40: 101-104, 1997
- 12) Reisch R, Bettag M, Perneczky A, Kawase T, Toya S, Shiobara R, Mine T: Transoral transclival removal of anteriorly placed cavernous malformations of the brainstem. *Surg Neurol* 56: 106-115, 2001
- 13) Samii M, Eghbal R, Carvalho GA, Matthies C, Kawase T, Toya S, Shiobara R, Mine T: Surgical management of brainstem cavernomas. *J Neurosurg* 95: 825-832, 2001
- 14) Symon L, Jackowski A, Bills D: Surgical treatment of pontomedullary cavernomas. *Br J Neurosurg* 5: 339-347, 1991
- 15) Yoshimoto T, Suzuki J: Radical surgery on cavernous angioma of the brainstem. *Surg Neurol* 26: 72-78, 1986

Address reprint requests to: N. Saito, M.D., Department of Neurosurgery, Gunma University School of Medicine, 3-39-22 Showa-machi, Maebashi, Gunma 371-8511, Japan.
e-mail: nsaito@med.gunma-u.ac.jp.