

# Occurrence of subdural hematoma and resolution of gait disturbance in a patient treated with shunting for normal pressure hydrocephalus

Akira Nakamizo<sup>a,\*</sup>, Takanori Inamura<sup>a</sup>, Satoshi Inoha<sup>a</sup>, Hiroshi Kuba<sup>a</sup>,  
Toshiyuki Amano<sup>a</sup>, Masayuki Sasaki<sup>b</sup>, Masashi Fukui<sup>a</sup>

<sup>a</sup> Department of Neurosurgery, Graduate School of Medical Sciences, Kyushu University, 3-1-1 Maidashi, Higashi-ku, Fukuoka, Japan

<sup>b</sup> Department of Radiology, Kyushu University, Fukuoka, Japan

Received 12 April 2001; received in revised form 27 March 2002; accepted 27 March 2002

## Abstract

A 66-year-old man with gait disturbance was diagnosed with normal pressure hydrocephalus (NPH) and treated with ventriculoperitoneal shunting using a programmable valve. The valve ultimately set at a pressure of 40 mmH<sub>2</sub>O after higher settings no longer relieved symptoms. However, this pressure setting was excessively low and was associated with occurrence of bilateral subdural hematomas. Paradoxically, this event was associated with stable improvement of gait. Our patient's gait disturbance was unassociated with muscle weakness, spasticity, cerebellar ataxia, or Romberg's sign, and, therefore, was consistent with a frontal gait disorder. Cerebral cortical blood flow as measured after shunting by single photon emission computed tomography (SPECT) was slightly increased from the value before shunting, possibly because of intracranial hypotension related to the valve setting. Lasting improvement of gait in our case may be a result of increased blood flow in the supplementary motor area (SMA). © 2002 Elsevier Science B.V. All rights reserved.

**Keywords:** Subdural hematoma; Normal-pressure hydrocephalus; Ventriculoperitoneal shunt; Intracranial hypotension; Single-photon emission computed tomography (SPECT); Gait disturbance

## 1. Introduction

Gait disturbance in normal pressure hydrocephalus (NPH), similar in several ways to that in Parkinson's disease, is described as a moderately severe frontal gait disorder characterized by a wide base, short steps, shuffling, and hesitation in starting to walk and in turning [1]. Recently the supplementary motor area (SMA) in the frontal lobe has been implicated as a possible cause of gait disturbance in Parkinson's disease [2]. We describe a case of 66-year-old man with an unusual clinical course after shunting for NPH, and discuss the possible mechanism of his gait disturbance in terms of these events and observations.

## 2. Case presentation

A 66-year-old man developed progressive gait disturbance, unsteadiness, and bradykinesia 3 years prior to admission. He initially was diagnosed with Parkinson's disease at another hospital because the gait disturbance had a festinating quality. Despite antiparkinsonian drug therapy, these symptoms worsened gradually and mild urinary incontinence appeared. The patient was referred to our institution.

No muscle weakness, no spasticity or other pyramidal signs, and no proprioceptive sensory disturbance or Romberg's sign suggestive of sensory ataxia or spinal cord dysfunction were present. Signs of cerebellar ataxia and those of extrapyramidal rigidity also were absent. The patient walked slowly with a wide-based, short-stepped, and shuffling stride. The 'magnetic' phenomenon was noted upon walking in narrow surroundings. Arm swing during walking was preserved. The patient was unsteadily while standing, and fell easily when pushed. He did not show resting tremor, hesitation

\* Corresponding author. Tel.: +81-92-642-524; fax: +81-92-642-5526

E-mail address: nakamizo@ns.med.kyushu-u.ac.jp (A. Nakamizo).

upon starting and turning, or difficulty rising from a chair. His handwriting showed no sign of disturbance.

Magnetic resonance imaging (MRI) showed symmetric dilation of the entire ventricular system, diffuse brain atrophy, and periventricular hyperintensity (PVH) on T2-weighted images in relation to the posterior horn of the lateral ventricle (Fig. 1). Radioisotope (RI) cisternography demonstrated RI reflux into the ventricles and abnormal retention of RI. Cerebrospinal fluid (CSF) pressure was 110 mmH<sub>2</sub>O. Removal of 45 ml of CSF by lumbar puncture produced temporary improvement of gait. Based on these results, the patient was diagnosed with NPH.

We performed a right ventriculoperitoneal shunt operation including placement of a programmable valve, initially setting the pressure as 120 mmH<sub>2</sub>O (Codman-Medos; Le locle, Swiss). About 4 days after the operation, gait disturbance resolved. Postoperative computed tomography (CT) and MRI did not demonstrate obvious improvement of ventricular size or PVH, but the magnetic phenomenon previously apparent while walking through narrow spaces disappeared at 2 months following the operation.

Six months after the operation, gait disturbance reappeared but resolved upon reducing pressure in the shunt system to 90 mmH<sub>2</sub>O. CT showed a slight size reduction in the lateral ventricle, but not in all ventricles (Fig. 2). Almost 13 months after operation, gait disturbance again recurred, resolving upon reducing the pressure to 70 mmH<sub>2</sub>O. At 19 months after surgery, the pressure was inadvertently set at 100 mmH<sub>2</sub>O, and gait deteriorated; this resolved upon reducing the pressure to 60 mmH<sub>2</sub>O. Finally, 27 months after operation, the pressure was set at 40 mmH<sub>2</sub>O because slight gait disturbance occurred at 60 mmH<sub>2</sub>O; improvement of gait persisted for more than 15 months. CT and MRI performed at 42 months after the operation unexpectedly showed small bilateral subdural hematomas associated with reduced size of all ventricles (Fig. 3). Gait improved steadily, without festination or occurrence of the magnetic phenomenon.

In this patient we compared frontal cerebral blood flow (CBF) in a region including the SMA by single

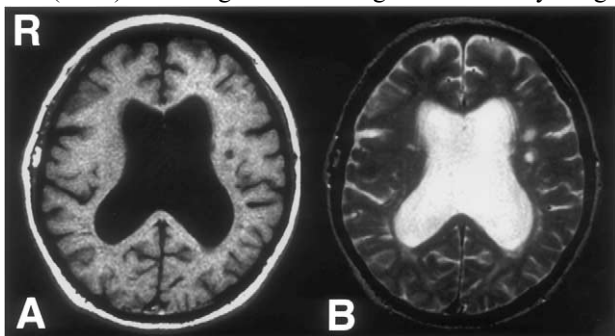


Fig. 1. MRI preoperatively shows a dilated lateral ventricle on T1-weighted images (A) and PVH on T2-weighted images (B).

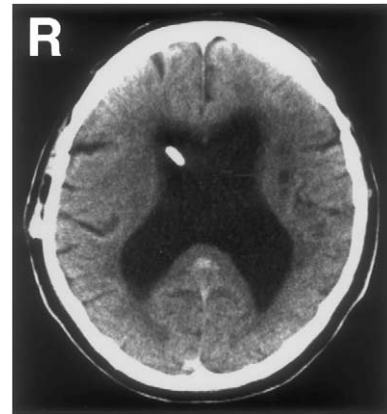

Fig. 2. CT at 6 months after surgery shows size reduction in the lateral ventricle.

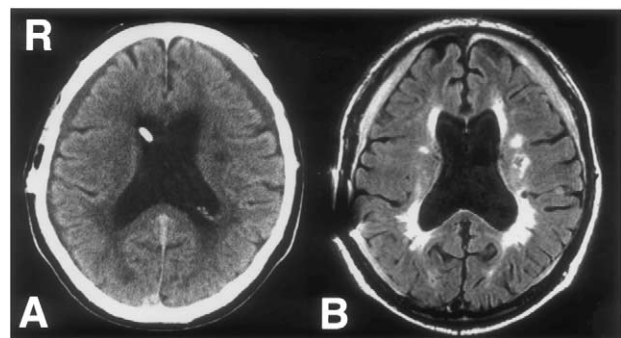


Fig. 3. CT (A) and FLAIR magnetic resonance images (B) at 42 months after the operation shows bilateral subdural hematomas associated with reduced size of the lateral ventricles.

photon emission computed tomography (SPECT) using <sup>99m</sup>Tc-ECD performed both preoperatively and at 42 months postoperatively. We calculated CBF as the ratio of frontal cerebral to cerebellar hemisphere flow using NIH IMAGE software (version 1.60; Fig. 4). The preoperative ratio was 0.99 and 0.89 in the right and left hemispheres, respectively; postoperatively the ratio in-

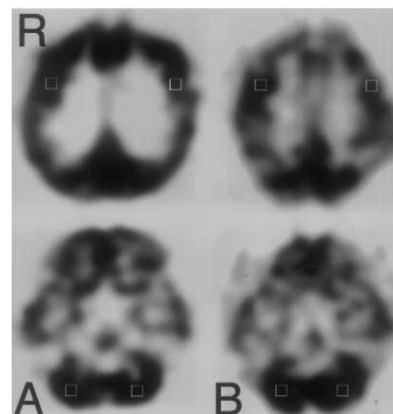


Fig. 4. Single-photon emission CT using <sup>99m</sup>Tc-ECD before the shunting operation (A, left) and 42 months after the operation (B, right). The white open square indicates the area of densitometric measurement using NIH IMAGE software.

creased to 1.02 and 0.96, respectively, (not statistically significant).

### 3. Discussion

Subdural hematoma sometimes occurs after VP shunting when excessive diversion of CSF results in intracranial hypotension. When our patient's shunt system was reprogrammed at a pressure of 40 mmH<sub>2</sub>O to alleviate symptoms, this excessively low pressure resulted in occurrence of subdural hematomas. However, gait improved when the subdural hematomas occurred. Two phenomena, thus, can be recognized: stepwise decreases of shunt pressure producing temporary improvement of gait for 2 or 3 months; and subdural hematoma occurrence at the intracranial pressure of 40 mmH<sub>2</sub>O associated with lasting gait improvement. These events are related to the pathophysiology of NPH.

Several hypotheses have been offered concerning neurological signs and symptoms of NPH. Most involve enlarged ventricles causing compression of periventricular neuronal connections according to the laws of Pascal and Laplace [3]. Corticospinal fibers from cortical areas supplying the lower limbs and frontopontocerebellar fibers are among the pathways believed to be compressed by the enlarged ventricles [4,5]. Other authors have maintained that gait dysfunction in NPH could be caused by frontal apraxia reflecting disconnection between the idea of walking and the required motor program [6,7]. Since our case showed only a gait disturbance without any signs of muscle weakness, spasticity, cerebellar ataxia, or Romberg's sign, our case was typical for frontal gait disorder and frontal disequilibrium. Frontal gait disorder, frequently seen with NPH, is characterized by a wide base, short steps, shuffling, hesitation in starting to walk and in turning, and moderate disequilibrium [1].

Davis et al. recently proposed that dysfunction of the SMA takes part in the gait disturbance of Parkinson's disease, in which SMA activity is reduced because motor centers in the thalamus are suppressed by excessive inhibitory outflow from the internal segment of the globus pallidus [2]. Neurophysiologically, the SMA is active in programming and preparing for voluntary sequential movement, including triggering of motor actions. SPECT indicates that the SMA is highly active during walking in normal human subjects, while positron emission tomography (PET) has shown impaired activation of frontal areas including the SMA during movement in Parkinson's disease. These findings suggest that the frontal disequilibrium and frontal gait disorder that occur as symptoms of NPH may be caused by SMA dysfunction. NPH shows a gait disturbance similar to that in Parkinson's disease with respect to abnormal

postural responses and locomotion disturbance. This similarity can be explained anatomically; neuronal connections between the frontal cortex and basal ganglia concerned with gait initiation course near the anterior horns of the lateral ventricles and are easily compressed by ventricular dilation. When we compared pre- and postoperative cortical blood flow by SPECT using 99 mTc-ECD, our case showed a slight postoperative increase in cortical blood flow, possibly a result of intracranial hypotension (40 mmH<sub>2</sub>O). Lasting improvement of gait in our case may have involved increased cortical blood flow in the SMA and decreased pressure upon tracts located near the ventricular wall.

Small lesions were seen in the paraventricle white matter of the left hemisphere in our case (Figs. 1 and 3). For NPH diagnosis, it should be differentiated from Binswanger disease. The characteristics of Binswanger disease seen in images are symmetric diffuse white matter lesions, small infarcts in basal ganglia, and dilated ventricles [8]. The differentiation is sometimes difficult, especially in the cases of Binswanger disease accompanied with dilated ventricles. Even in our case, exclusion of Binswanger disease was impossible. However, gait disturbance improved upon reducing the pressure of the device. Long-term follow-up in this case and study of others is needed to better understand the multiple factors involved in the pathophysiology of these events.

### Acknowledgements

The author wishes to thank Ms. Yosie Hirose for her valuable assistance.

### References

- [1] Gilman S. Gait disorders. In: Lowland L, editor. Merritt's textbook of neurology. Philadelphia: Lea & Febiger, 1989:55.
- [2] Davis KD, Taub E, Houle S, Lang AE, Dostrovsky JO, Tasker RR, Lozano AM. Globus pallidus stimulation activates the cortical motor system during alleviation of parkinsonian symptoms. *Nat Med* 1997;3:671–4.
- [3] Hakim S, Adams R. The special clinical problem of symptomatic hydrocephalus with normal CSF pressure. *J Neurol Sci* 1965;2:307–27.
- [4] Goto I, Kuroiwa Y, Kitamura K. The triad of neurological manifestations in bilateral chronic subdural hematoma and normal pressure hydrocephalus. *J Neurol Sci* 1986;30:123–8.
- [5] Fisher CM. Hydrocephalus as a cause of disturbances of gait in the elderly. *Neurology* 1982;32:1358–63.
- [6] Meyer J, Barron D. Apraxia of gait: a clinico-physiological study. *Brain* 1960;83:261–84.
- [7] Petrovici I. Apraxia of gait and of trunk movements. *J Neurol Sci* 1968;7:229–43.
- [8] Bennett DA, Wilson RS, Gilley DW, Fox JH. Clinical diagnosis of Binswanger's disease. *J Neurol Neurosurg Ps* 1990;53:961–5.