

Clinical Study

Hemorrhage and VEGF expression in a case of primary CNS lymphoma

James Rubenstein¹, Nancy Fischbein², Ken Aldape³, Eric Burton⁴ and Marc Shuman¹

¹*Division of Hematology/Oncology, ²Department of Radiology, ³Department of Pathology,*

⁴*Department of Neurological Surgery, University of California, San Francisco, CA, USA*

Key words: primary CNS lymphoma, hemorrhage, angiogenesis, vascular endothelial growth factor

Summary

Hemorrhage at presentation in primary CNS lymphoma is exceedingly rare. We describe a patient with primary CNS lymphoma who presented with seizures and was found to have an intracerebral hemorrhage which prompted a cerebral angiogram. Ultimately pathologic evaluation of the lesion revealed a highly cellular B-cell lymphoma with marked hypervascularity and intense expression of vascular endothelial growth factor (VEGF). A review of four other recent cases of primary CNS lymphoma at our institution revealed less-intense VEGF immunoreactivity. This is the first report of VEGF expression in primary CNS lymphoma. The potential significance of VEGF expression with respect to the biology of this tumor is discussed.

Introduction

An important goal in clinical cancer research is to be able to correlate the imaging characteristics of tumors with specific molecular features which underly their biology.

Case Report

A 55 year-old man presented with tonic clonic seizures involving the right arm. Physical examination was remarkable for right upper extremity weakness. An MRI of the brain revealed a hemorrhagic mass involving the left posterior frontal lobe with significant surrounding vasogenic edema (Figure 1). A left posterior frontal craniotomy was performed and biopsy material showed diffuse large cell non-Hodgkin's lymphoma, CD20-positive. Systemic staging evaluation, including ophthalmologic examination, MRI of spine, CT scans of chest, abdomen and pelvis and bone marrow biopsy, was negative. The CSF was cytologically benign and complete blood count was within normal limits. Coagulation tests were within normal limits. The patient had previously been in excellent health. An HIV test was negative.

The patient was treated for primary central nervous system lymphoma. His initial treatment consisted

of dexamethasone and anticonvulsants. Subsequently he was treated with a combination of high-dose methotrexate, cytarabine, and Rituximab. A partial response was obtained which lasted 10 months. However, because of progressive disease he ultimately was treated with whole brain radiation and is currently in remission, 30 months after diagnosis.

Pathologic review of the biopsy material showed an invasive, highly cellular neoplasm consisting of malignant lymphocytes. Marked hypervascularity was evident. (Figure 2). Immunoperoxidase analysis showed that the tumor cells exhibited intense reactivity for vascular endothelial growth factor (VEGF). A review of four other recent cases of primary CNS B-cell lymphoma tumors at our institution also revealed VEGF immunoreactivity by lymphoma cells. Intensity of VEGF staining in these cases, however, was markedly lower than in this patient. Each of these cases also presented with gadolinium enhancement on MRI but not with hemorrhage or with significant neovascularization. The weakest VEGF expression in this cohort was found in the one tumor which did not respond to high-dose methotrexate plus Rituximab.

Discussion

Hemorrhage at the time of presentation in primary CNS lymphoma is rare. In a recent review of the radiographic

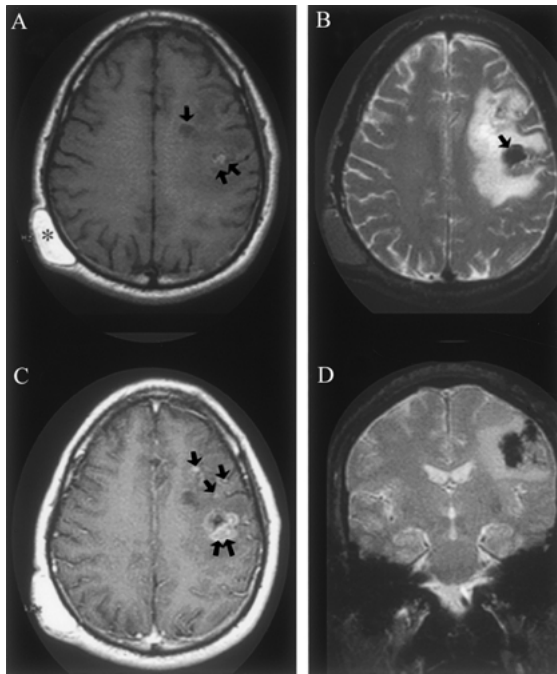


Figure 1. (A) An axial T1-weighted image (TR 600/TE min) demonstrates parenchymal subcortical hypointensity and sulcal effacement in the left frontal lobe, consistent with vasogenic edema. A more focal hypointensity medially (arrow) likely represents cyst formation, while a focal hyperintensity (double arrow) suggests the presence of subacute blood. A right parietal scalp mass (asterisk) with signal characteristics that parallel fat represents an incidental lipoma. (B) An axial T2-weighted image (TR 2500/TE 80) demonstrates the vasogenic edema to better advantage. In addition, multiple small foci of hypointensity located anteriorly and a dominant focus of hypointensity (arrow) more posteriorly are consistent with blood products. The areas which show iso- or hypointensity on the T1WI and hypointensity on the T2WI are consistent with deoxyhemoglobin, while the area which is hyperintense on T1WI and hypointense on T2WI is consistent with extracellular methemoglobin. (C) An axial post-gadolinium T1-weighted image demonstrates irregular foci of enhancement located anteriorly within the left frontal lobe (arrows), and a dominant enhancing mass located more posteriorly (double arrow). The multiple irregular foci of enhancement and dominant mass suggest an underlying neoplastic process rather than the enhancement that can be associated with a subacute hematoma. (D) A coronal multiplanar gradient-refocused image (TR 787/TE 25/flip angle 20) shows multiple regions of very low signal due to magnetic susceptibility effects caused by the presence of blood products. The zone of surrounding vasogenic edema is again seen as surrounding high signal intensity.

features of 33 cases of primary CNS lymphoma, none were associated with intracranial bleeding [1]. This is the first demonstration, of which we are aware, of VEGF expression by tumor cells in primary CNS

lymphoma. Histologic analysis of this case suggests a correlation between intratumoral hemorrhage, neovascularization and the degree of VEGF expression in primary central nervous system lymphoma.

Over the past several years, a vast accumulation of evidence suggests that the growth of solid tumors is dependent on angiogenesis. Recent evidence suggests that the growth of hematologic malignancies is also associated with an angiogenic phenotype. For example, several recent studies have demonstrated that elevated serum levels of VEGF is associated with poor outcome in systemic non-Hodgkin's lymphoma [2,3]. One recent study has demonstrated that simultaneous serum elevation of VEGF and basic fibroblast growth factor (bFGF) is an independent predictor of poor prognosis in non-Hodgkin's lymphoma [4]. Moreover, exposure of human vascular endothelial cells to recombinant human VEGF results in an increase in the level of gene expression for several hematopoietic growth factors including macrophage colony-stimulating factor, granulocyte colony-stimulating factor and interleukin-6 [5]. These findings raise the possibility that angiotropism in primary central nervous system lymphoma may constitute an important paracrine growth mechanism for lymphoma progression.

Expression of VEGF by primary central nervous system lymphoma cells may contribute significantly to several of the pathobiological features of this tumor. First, the majority of primary central nervous system lymphomas are associated with enhancement on MRI or CT scan [6]. While these tumors typically obtain nourishment by angiotropism and not by angiogenesis, expression of VEGF could contribute to the vascular destabilization and permeability changes which characterize the disrupted blood-brain barrier in these tumors, thus accounting for this contrast enhancement [7]. VEGF stimulates the formation of endothelial fenestrations and is a strong inducer of vascular permeability, with a potency 50,000 times greater than histamine [8]. Second, VEGF expression could contribute to the vasogenic edema which is characteristic of this type of brain tumor. Third, overexpression of VEGF isoforms 121 and 165 has been shown to induce vascular destabilization in an animal model of glioblastoma, resulting in intracerebral hemorrhage [9]. The intense VEGF expression noted in this case also supports a role for VEGF overexpression and the induction of spontaneous tumor hemorrhage. Fourth, glucocorticoids have a critical role in the treatment of primary CNS lymphoma: at least 25% of patients exhibit a radiographic response to dexamethasone

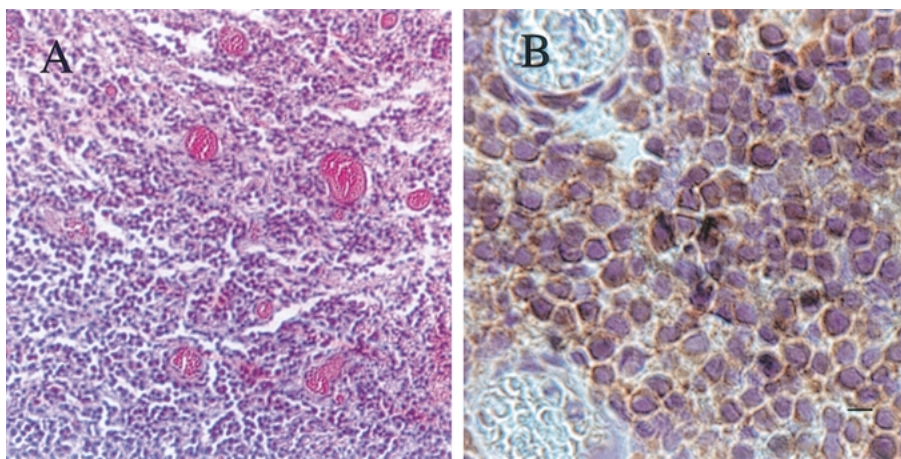


Figure 2. (a) Hematoxylin and eosin stain of primary CNS lymphoma tumor obtained from the patient showing high-grade lesion with evidence of neovascularization. (100 \times). (b) Diffuse VEGF immunoreactivity by primary central lymphoma cells was detected. (400 \times). Bar = 10 μ m. Trace VEGF immunoreactivity was detected in normal brain. High levels of VEGF immunohistochemistry was demonstrated using both a monoclonal antibody (PharMingen) and with a polyclonal antibody (Santa Cruz). Immunoreactivity was abrogated when a blocking peptide was used. Four other primary CNS lymphoma tumors analyzed exhibited moderate levels of VEGF immunoreactivity.

[10]. The basis for this effect may be secondary to at least two mechanisms of action: while glucocorticoids likely exert a direct apoptotic effect on malignant lymphocytes, it is also plausible that dexamethasone may also reduce lymphoma-associated vascular permeability by blocking both the expression and/or actions of VEGF [11]. Fifth, VEGF-mediated permeability changes may contribute positively to the relatively successful role of systemic chemotherapy in this disease.

While further studies are required to confirm this observation, these findings suggest a potential application of biological therapies which inhibit VEGF action in the treatment of this highly lethal brain tumor.

Acknowledgements

Supported by the American Society of Clinical Oncology, the California Cancer Research Program, and the UCSF/Mt Zion Cancer Center.

This study was approved by the UCSF Committee on Human Research.

References

- Jenkins CN, Colquhoun IR: Characterization of primary intracranial lymphoma by computed tomography: an analysis of 36 cases and review of the literature with particular reference to calcification, haemorrhage and cyst formation. *Clin Radiol* 53: 428–434, 1998
- Salven P, Teerenhovi L, Joensuu H: A high pretreatment serum vascular endothelial growth factor concentration is associated with poor outcome in non-Hodgkin's lymphoma. *Blood* 90: 3167–3172, 1998
- Bertolin F, Paolucci M, Peccatori F, Cinieri S, Agzzi A, Ferrucci PF, Coccorocchio E, Goldhirsch A, Martinelli G: Angiogenic growth factors and endostatin in non-Hodgkin's lymphoma. *Br J of Haematol* 106: 504–509, 1999
- Salven P, Orpana A, Teerenhovi L, Joensuu H: Simultaneous elevation in the serum concentrations of the angiogenic growth factors VEGF and bFGF is an independent predictor of poor prognosis in non-Hodgkin lymphoma: a single institution study of 200 patients. *Blood* 96(12): 3712–3718, 2000
- Bellamy WT, Richter L, Frutiger Y, Grogan TM: Expression of vascular endothelial growth factor and its receptors in hematopoietic malignancies. *Cancer Res* 59(3): 728–733, 1999
- Roberts WG, Palade GE: Increased microvascular permeability and endothelial fenestration induced by vascular endothelial growth factor. *J Cell Sci* 108: 2369–2379, 1995
- Fine HA, Mayer RJ: Primary central nervous system lymphoma. *Ann Intern Med* 119: 1093–1104, 1993
- Molnar PP, O'Neill BP, Scheithauer BW, Groothuis DR: The blood-brain barrier in primary CNS lymphomas: ultrastructural evidence of endothelial cell death. *Neuro-Oncol*: 1(2): 89–100, 1999
- Cheng SY, Nagane M, Huang HS, Cavenee WK: Intracerebral tumor-associated hemorrhage caused by overexpression

- of the vascular endothelial growth factor isoforms VEGF121 and VEGF165 but not VEGF189. *Proc Natl Acad Sci USA* 94(22): 12081–7, 1997
10. Weller M: Glucocorticoid treatment of primary CNS lymphoma. *J Neuro-Oncol* 43: 237–239, 1999
 11. Heiss JD, Papavassiliou E, Merrill MJ, Nieman L, Knightly JJ, Walbridge Edwards NA, Oldfield EH: Mechanism of dexamethasone suppression of brain tumor-associated vascular permeability in rats. *J Clin Invest* 98(6): 1400–1408, 1996

Address for offprints: James Rubenstein, Division of Hematology/Oncology, University of California, 505 Parnassus Avenue, Room M1282, San Francisco, CA 94143, USA; E-mail: jamesr@medicine.ucsf.edu