

An Unusual Manifestation of Wegener's Granulomatosis in a 4-Year-Old Girl

Johannes-Peter Haas, MD*[†],
Markus Metzler, MD*, Hans Ruder, MD[‡],
Rüdiger Waldherr, MD[§],
Michael Böswald, MD[¶], and
Thomas Rupprecht, MD*

We report a female who was diagnosed with Wegener's granulomatosis at 4 years of age with life-threatening intracranial bleeding. The patient's serum was positive for c-antineutrophilic cytoplasmic antibodies, and histologic analysis of the lung biopsy revealed evidence of granulomatous vasculitis. Initial treatment with steroids and cyclophosphamide was successfully converted to a long-term medication regimen consisting of azathioprine, trimethoprim, and sulfamethoxazole. Thereafter the patient showed no signs of disease activity for more than 3 years and manifested only a low-grade neurologic handicap. In February 2001, 5 years after the initial diagnosis, she presented with altered consciousness and myoclonic multifocal seizures. Subsequent diagnostic studies confirmed the diagnosis of disseminated cerebral vasculitis unresponsive to steroid treatment. Acute neurologic symptoms relented immediately after cyclophosphamide pulse therapy. Magnetic resonance imaging of the brain demonstrated complete remission within 8 weeks. Her current treatment includes steroids and monthly pulses of cyclophosphamide. © 2002 by Elsevier Science Inc. All rights reserved.

Haas J-P, Metzler M, Ruder H, Waldherr R, Böswald M, Rupprecht T. An unusual manifestation of Wegener's granulomatosis in a 4-year-old girl. *Pediatr Neurol* 2002; 27:71-74.

Introduction

Intracranial hemorrhage during childhood is most frequently caused by vascular malformations, coagulation disorders, and brain tumors [1]. Cerebral vasculitis can also be a cause of cerebral bleeding [4]. Wegener's granulomatosis is a rare disorder in pediatric patients. Most pediatric patients with Wegener's granulomatosis demonstrate involvement of the kidneys, lungs, and the nasal mucosa [17]. In adults 50% of patients suffering from Wegener's granulomatosis have been reported to have neurologic symptoms, although in fact only 10% of the patients have involvement of the central nervous system [2]. We report a rare case of Wegener's granulomatosis with involvement of the central nervous system beginning in early childhood.

Case Report

On hospital admission in January 1996, a 4-year-old female presented with headache, seizures, altered consciousness, inappropriate language, and various degrees of coma (Glasgow Coma Scale 6-10). There was no history of trauma or infection. The physical examination revealed signs of increased intracranial pressure including papilledema. Cranial computed tomography revealed a massive intracerebral hemorrhage in the right frontotemporal region (Fig 1). Craniotomy was performed immediately, and the child recovered with the residual of a moderate spastic hemiplegia of the left side. On day 25 after craniotomy an acute respiratory distress syndrome occurred with poor oxygenation and bilateral nodular infiltrates on chest radiography, but normal cardiac function (Fig 2). At that time the erythrocyte sedimentation rate was 25/52 mm, C-reactive protein 10.6 mg/dL, and values for amylase and lipase were consistent with acute pancreatitis. Tests for coagulation disorders revealed no abnormalities, there was no skin involvement, nor impaired liver or kidney function. Despite negative microbiologic studies acute respiratory distress syndrome was thought to result from infection. Under treatment with antibiotics (including imipenem and tobramycin) and prednisolone (0.5 mg/kg), mechanical ventilation was gradually withdrawn and discontinued after 9 days.

Consequently pulmonary function improved, and pancreatic function parameters returned to normal. As a consequence of the complete withdrawal of prednisolone therapy, acute respiratory distress syndrome relapsed at day 60 and was suspected to be triggered by systemic

From the *Department of Pediatrics, Friedrich-Alexander University, Erlangen, Germany; the [†]Department of Pediatrics, Division of Neonatology and Intensive Care, Ernst-Moritz-Arndt University, Greifswald, Germany; [‡]Caritashaus, Feldberg, Germany; the [§]Laboratory for Pathology, Heidelberg, Germany; and the [¶]Department of Pediatrics, St. Franziskus Hospital, Muenster, Germany.

Communications should be addressed to:
Dr. Haas; Department of Pediatrics, Division of Neonatology and Intensive Care, Ernst-Moritz-Arndt University, Soldmannstr. 15, 17487 Greifswald, Germany.

Received November 13, 2001; accepted February 4, 2002.

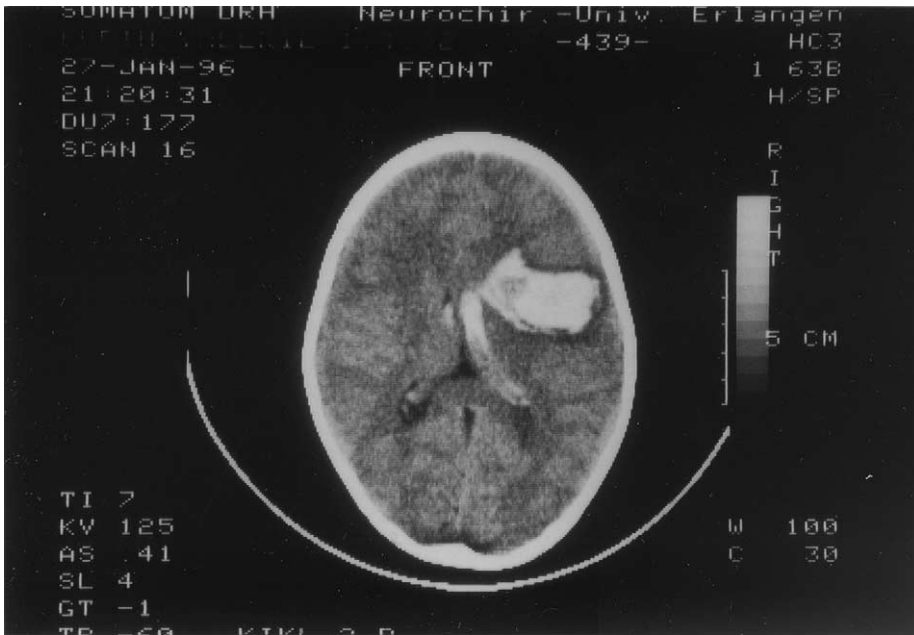

Figure 1. Cranial computed tomography on the day of admission demonstrating extensive intracerebral hemorrhage in the right frontotemporal region.

vasculitis. Blood tests revealed erythrocyte sedimentation rate of 43/121 mm and c-antineutrophil cytoplasmic antibody (c-ANCA) titer of 1:40 and a negative antiproteinase 3 (PR-3)-enzyme-linked immunosorbent assay test. C3 levels were unaltered, and tests for antinuclear antibodies were negative. The patient responded well to steroids (2 mg/kg/day) and was discharged from hospital 4 weeks later. Steroids were administered over 4 months, and the dose was gradually decreased to 0.1 mg/kg/day. Six weeks after the steroid treatment had been discontinued the patient developed acute respiratory distress syndrome again along with microalbuminuria (69 mg/L). Lung biopsy revealed the histology of a focal necrosis, palisading granulomas, and giant cells, characteristically typical for chronic necrotizing granulomatous vasculitis. The c-ANCA titer continued to be positive (1:40). Again the patient was started on prednisolone treatment (2 mg/kg/day) with doses that were gradually decreased by 0.2 mg/kg each week down to a final dose of 0.1 mg/kg. Moreover, treatment with oral cyclophosphamide was begun (3 mg/kg

administered 5 days per week) with a cumulative dose of 750 mg/kg/year, as published elsewhere [5]. A rapid and complete remission of the acute respiratory distress syndrome and proteinuria was achieved within 6 weeks, and inflammation parameters including the c-ANCA titer returned to normal. After 12 months, cyclophosphamide was replaced by azathioprine (2 mg/kg/day), which was administered for an additional 12 months. Because the patient's stable remission continued, steroids were discontinued, and azathioprine was replaced by cotrimoxazole/SMX (T/S 2 mg/kg twice daily), which was administered for another 12-month period [16]. During this time the patient was in good health with no signs of active inflammation, and the lung function parameters were within normal limits. She was mentally and physically rehabilitated and spastic hemiplegia of the left side was the only residual condition. She was able to walk, run, and perform simple functions with her left hand and successfully attended a regular school. In February 2001 she presented with altered consciousness and head pain. There were no other symptoms

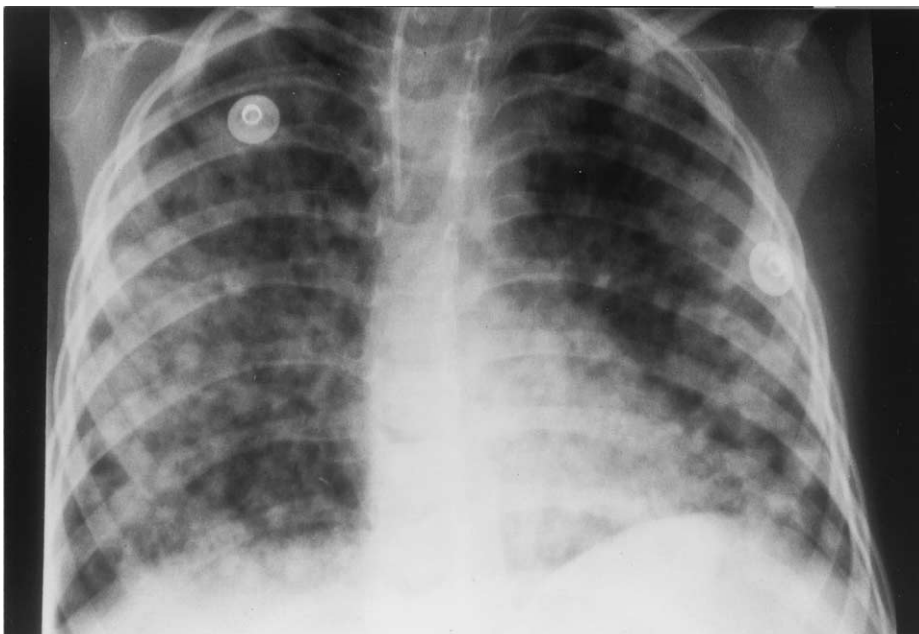


Figure 2. Anteroposterior chest x-ray on day 25 depicts bilateral nodular infiltrates as characteristic indications of acute respiratory distress syndrome.

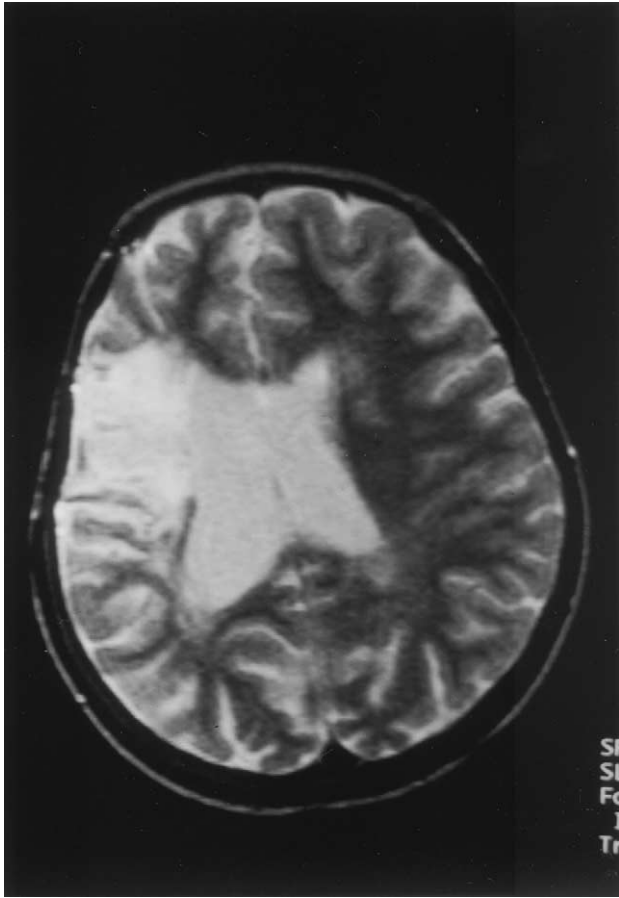


Figure 3. Cerebral magnetic resonance imaging in February 2001 after 5 days of multifocal symptoms demonstrates a right frontotemporal hyperdense area that corresponds with the encephalomalacia scar resulting from the intracerebral bleeding in 1996. There are no signs of active vasculitis. (Siemens open magnetom T₂-weighted sequence.)

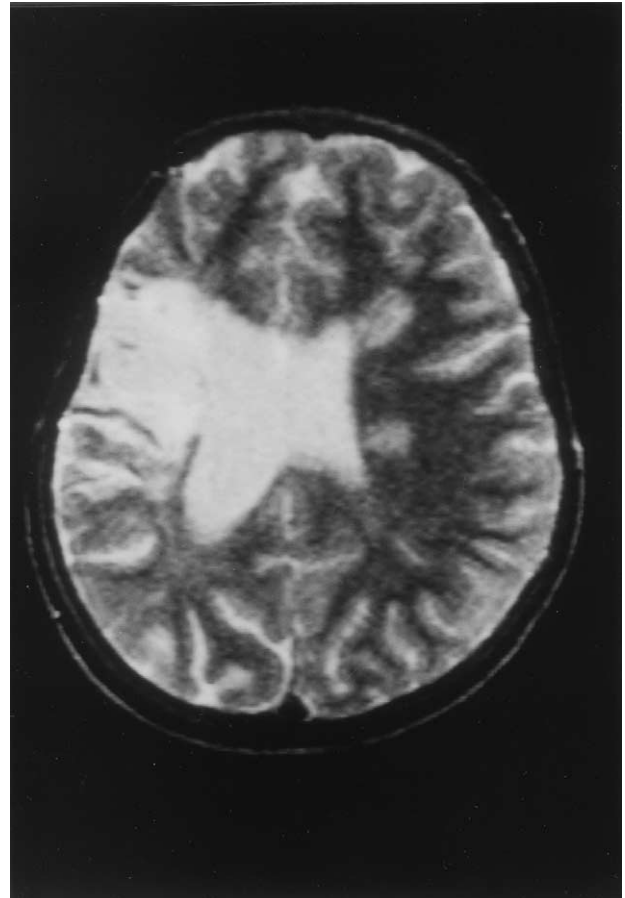


Figure 4. Cerebral magnetic resonance imaging in March 2001, 12 days after initial presentation of symptoms, illustrates disseminated multifocal cerebral vasculitis, indicated by hyperdense spots of gadolinium in both hemispheres, the thalamus, and the cerebellum. (Siemens open magnetom T₂-weighted sequence.)

of vasculitis. Analysis of blood and cerebral fluid revealed no signs of inflammation. c-ANCA results were negative, and the patient had no detectable pulmonary disease. Magnetic resonance imaging of the brain did not reveal any changes characteristic of cerebral vasculitis. The encephalomalacia from her initial intracerebral bleeding did not reveal any alterations as compared with previously performed imaging studies (Fig 3). Her overall condition deteriorated quickly, and she subsequently developed myoclonic multifocal seizures that were resistant to therapy with benzodiazepine and phenytoin. Because the initial suspicion was that a relapse of her intracerebral vasculitis might have occurred, treatment was immediately begun with high-dose steroids (2 mg/kg/day). Cranial magnetic resonance imaging was repeated at day 10 and revealed that multilobar lesions had developed involving supratentorial and infratentorial areas of the brain (Fig 4). Blood and cerebrospinal fluid analyses did not demonstrate a systemic inflammatory response, although c-ANCA results were slightly positive with a titer of 1:80. Neurologic symptoms did not respond to steroid therapy, and it was therefore decided to add an IV cyclophosphamide pulse with 750 mg/m² of body surface. This treatment improved the patient's symptoms dramatically and resulted in cessation of seizures within 12 hours and a complete recovery from the neurologic symptoms within 3 days. The patient was able to leave the hospital on day 10 after the first cyclophosphamide pulse. Since then she received three IV pulses of cyclophosphamide, and steroids were gradually decreased to a final dose of 0.2 mg/kg administered every second day. Cerebral recovery was documented, with magnetic resonance imaging of the brain performed at the time of the third IV cyclophosphamide pulse in June 2001. At this time, all signs of the acute vasculitis had recovered completely. Cyclophosphamide was

discontinued after six pulses, and immunosuppressive treatment was maintained with azathioprine administered orally with a dosage of 2 mg/kg/day and the steroid treatment described above.

Discussion

Central nervous system bleeding can result from a variety of causes [1,12]. The patient described in this report had no history of trauma, coagulopathy, hypertension, or brain tumor. The reasons most likely responsible for the patient's initial intracerebral bleeding in 1996 seem to be vascular malformation and cerebral vasculitis. No signs of vascular malformations have been revealed in any of the cerebral angiograms performed with magnetic resonance imaging since the initial presentation in our patient. Although this does not exclude a malformation completely, the further course of the patient led us to conclude that cerebral vasculitis seems to be most likely responsible for the cerebral hemorrhage. Because our patient had also lung involvement, isolated angiitis of the central nervous system, which is a rare disease with a poor prognosis, was excluded [9]. Histology demonstrated granulomatous vasculitis, and there was a relapse of the cerebral vasculitis in 2001. Therefore, retrospectively we

propose the intracerebral bleeding in 1996 to be the initial presentation of Wegener's granulomatosis. Cerebral manifestations of Wegener's granulomatosis occur in approximately 5% of the cases with thrombosis obstructing intracerebral arteries and veins [10]. Cranial magnetic resonance imaging with intermediate weighted and T₂-weighted imaging can be helpful in detecting central nervous system involvement of vasculitis [14]. Although nonspecific for cerebral vasculitis in Wegener's granulomatosis, most patients were found to have had diffuse white matter lesions with high signal intensity on T₂-weighted magnetic resonance imaging [10]. Treatment and prognosis of cerebral vasculitis in childhood is an area in which there is little clinical experience and data. Observations in adult patients with cerebral vasculitis caused by lupus erythematosus indicated that the long-term outcome may benefit from aggressive treatment involving cyclophosphamide [8]. The data for treatment of childhood granulomatous diseases are limited; therefore the first course of treatment in our patient was based on protocols that are used for the treatment of Wegener's granulomatosis in adults [5,16]. During the relapse in 2001 a cerebral vasculitis was present without lung or kidney involvement. Again therapy was based on protocols published for treatment of cerebral vasculitis in adults [8]. To prevent future relapses the immunosuppressive treatment with azathioprine and low-dose steroids should potentially be a lifelong treatment.

The patient reported herein exhibited a clinical and histologic picture consistent with granulomatous vasculitis. It fits in well with Wegener's granulomatosis, although we have not observed signs of kidney involvement. Wegener's granulomatosis is classified as a small-vessel vasculitis according to the Chapel Hill consensus conference [7]. The differential diagnosis of small vessel vasculitis includes Churg-Strauss syndrome, which demonstrates central nervous system involvement more frequently than Wegener's granulomatosis [6]. However, we could not detect signs of eosinophilia, either in blood smears or in the biopsy of our patient. Wegener's granulomatosis is a systemic vasculitis that is diagnosed only rarely in children during the first decade of life [3,17]. Symptoms and course of the disease seem to be similar to those observed in adults with Wegener's granulomatosis. There are very little data on the prognosis of Wegener's granulomatosis in young children. A limited disease without renal involvement has been described in children and adults [11,13]. We observed another female who began with lung disease at 6 years of age without kidney involvement and experienced renal failure at 10 years of age. Patients such as these might indicate that Wegener's granulomatosis and related vasculitides may be underdiagnosed in children [15]. The initial manifestation as an intracerebral hemorrhage is a rare complication of Wege-

ner's granulomatosis and has only been reported in some cases [18]. This report emphasizes the importance of considering Wegener's granulomatosis even in young children who present with unexplained intracerebral bleeding or acute respiratory distress syndrome.

References

- [1] **Al-Jarallah A**, Al-Rifai MT, Riela AR, Roach ES. Nontraumatic brain hemorrhage in children: Etiology and presentation. *J Child Neurol* 2000;15:284-9.
- [2] **Cruz DN**, Segal AS. A patient with Wegener's granulomatosis presenting with a subarachnoid hemorrhage: Case report and review of CNS disease associated with Wegener's granulomatosis. *Am J Nephrol* 1997;17:181-6.
- [3] **Dillon MJ**. Rare vasculitic syndromes. *Ann Med* 1997;29:175-9.
- [4] **Ferro JM**. Vasculitis of the central nervous system. *J Neurol* 1998;245:766-76.
- [5] **Guillevin L**, Cordier JF, Lhote F, et al. A prospective, multicenter, randomized trial comparing steroids and pulse cyclophosphamide versus steroids and oral cyclophosphamide in the treatment of generalized Wegener's granulomatosis [see comments]. *Arthritis Rheum* 1997;40:2187-98.
- [6] **Jennette JC**, Falk RJ. Small-vessel vasculitis [see comments]. *N Engl J Med* 1997;337:1512-23.
- [7] **Jennette JC**, Falk RJ, Andrassy K, et al. Nomenclature of systemic vasculitides. Proposal of an international consensus conference. *Arthritis Rheum* 1994;37:187-92.
- [8] **Karassa FB**, Ioannidis JP, Boki KA, et al. Predictors of clinical outcome and radiologic progression in patients with neuropsychiatric manifestations of systemic lupus erythematosus. *Am J Med* 2000;109:628-34.
- [9] **Lanthier S**, Lortie A, Michaud J, Laxer R, Jay V, deVeber G. Isolated angitis of the CNS in children. *Neurology* 2001;56:837-42.
- [10] **Murphy JM**, Gomez-Anson B, Gillard JH, et al. Wegener granulomatosis: MR imaging findings in brain and meninges. *Radiology* 1999;213:794-9.
- [11] **Nordmark G**, Boquist L, Ronnblom L. Limited Wegener's granulomatosis with central nervous system involvement and fatal outcome. *J Intern Med* 1997;242:433-6.
- [12] **Qureshi AI**, Tuhim S, Broderick JP, Batjer HH, Hondo H, Hanley DF. Spontaneous intracerebral hemorrhage. *N Engl J Med* 2001;344:1450-60.
- [13] **Reznik VM**, Griswold WR, Lemire JM, Mendoza SA. Pulmonary hemorrhage in children with glomerulonephritis. *Pediatr Nephrol* 1995;9:83-6.
- [14] **Sailer M**, Burchert W, Ehrenheim C, et al. Positron emission tomography and magnetic resonance imaging for cerebral involvement in patients with systemic lupus erythematosus. *J Neurol* 1997;244:186-93.
- [15] **Schwab M**, Boswald M, Ludwig K, Wittekind C, Waldherr R, Ruder H. A patient with Down's syndrome and anti-neutrophilic cytoplasmic antibody-positive vasculitis [letter; comment]. *Pediatr Nephrol* 1996;10:249-50.
- [16] **Stegeman CA**, Tervaert JWC, de Jong PE, Kallenberg CGM. Trimethoprim-sulfamethoxazole (Co-Trimoxazole) for the prevention of relapses of Wegener's granulomatosis. *N Engl J Med* 1996;335:16-20.
- [17] **Stegmayr BG**, Gothefors L, Malmer B, Muller Wiefel DE, Nilsson K, Sundelin B. Wegener granulomatosis in children and young adults. A case study of ten patients. *Pediatr Nephrol* 2000;14:208-13.
- [18] **von Scheven E**, Lee C, Berg BO. Pediatric Wegener's granulomatosis complicated by central nervous system vasculitis. *Pediatr Neurol* 1998;19:317-9.