

CLINICAL NOTE

Accidental Pneumothorax From a Nasogastric Tube in a Patient With Severe Hemineglect: A Case Report

Martin Winterholler, MD, PhD, Frank J. Erbguth, MD, PhD

ABSTRACT. Winterholler M, Erbguth FJ. Accidental pneumothorax from a nasogastric tube in a patient with severe hemineglect: a case report. *Arch Phys Med Rehabil* 2002;83:1173-4.

Nasogastric tubes are frequently used for nutrition of patients with neurologic diseases. We report an instance of inadvertent placement of a standard nasogastric tube into the left pleural space in a patient with right parietotemporal intracerebral hemorrhage and severe hemineglect on the left side. The 2 confirmatory maneuvers—aspiration of fluid and auscultating the abdomen on insufflating air—were false-positive. We conclude that only radiologic confirmation of the position of nasogastric tubes and the awareness of the associated dangers will help minimize the occurrence of such events in patients with disorders of perception or altered consciousness.

Key Words: Case report; Intubation, nasogastric; Neurologic disorders; Rehabilitation.

© 2002 by the American Congress of Rehabilitation Medicine and the American Academy of Physical Medicine and Rehabilitation

NASOGASTRIC TUBES are frequently used in hospitals, rehabilitation units, and nursing homes for nutrition of patients with neurologic diseases who have difficulties swallowing or impaired consciousness. The placement of such tubes may have potential serious side effects.¹ The risks in comatose patients are well defined, but little is known about the risk of such a procedure in patients with disorders of perception. We report an instance of inadvertent placement of a nasogastric tube into the left pleural space in a patient with right parietotemporal intracerebral hemorrhage and severe hemineglect on the left side.

CASE DESCRIPTION

A 68-year-old woman with a history of arterial hypertension was hospitalized for an acute stroke. A computed tomography scan showed a right hemispheric temporo-occipital intracranial hemorrhage (3×5×3cm). She was somnolent and had incomplete left hemiparesis but was able to communicate (Glasgow Coma Scale [GSC] score, 14). She had severe hemineglect, complete hemianopsia, hemianalgesia, and hemihypesthesia on her whole left side. Because she was unable to swallow, a standard nasogastric tube was inserted for fluid, medication, and food. She was alert during the procedure (GCS score, 14)

and was not observed to cough severely during tube placement. A small amount of fluid was aspirated, and, on insufflating air, auscultation of the abdomen revealed a confirmatory gurgle.

Tea and 100mL of nutrition were administered. One hour later, she began to suffer from severe dyspnea. A chest radiograph (fig 1) was immediately performed. It revealed misplaced insertion of the nasogastric tube into the left mainstem bronchus, pneumothorax, and pleural effusion. The tube was immediately removed, she was intubated, and a closed tube thoracostomy and bronchoscopy were performed. The patient's recovery was complicated by severe pneumonia and pleuritis caused by *Staphylococcus aureus*, which was treated with imipenem. Two weeks later she was transferred to a rehabilitation unit.

DISCUSSION

This patient had an atypical right hemispheric intracranial hemorrhage resulting in hemianopsia, hemineglect, and hemianalgesia. She was awake when the nasogastric tube was inserted. The typical symptoms of tube misplacement into the lower respiratory tract—coughing and discomfort—were not present. Reduced perception and severe hemineglect including the left bronchial system and the left pleura may have contributed to the lack of symptoms related to the nasogastric tube misplacement.

For the general patient population, there are a number of commonly accepted clinical signs that suggest proper placement of a nasogastric tube including (1) insufflation of air with sounds heard over the region of the stomach; (2) aspiration of fluid, suggesting placement of the tube in the stomach; (3) passage of the full distance of the tube with easy removal of a guide wire; and (4) absence of coughing, suggesting esophageal passage of the tube.^{2,3} These traditional criteria for proper tube placement, however, have been shown to be suboptimal in critically ill patients.⁴ Major underlying factors favoring tube malpositioning include depressed sensorium, impaired gag reflex, recent endotracheal intubation, decreased laryngeal sensitivity, and neuromuscular blocking drugs.⁵⁻⁹

Cases of complications caused by misplaced nasogastric feeding tubes have been reported from at least 10 different teaching hospitals.^{2,5,10} All pleuropulmonary complications were the result of the inadvertent passage of tubes into the trans-bronchial tree with eventual perforation into the lung and pleural space. Although perforation of the esophagus or the skull base by a nasogastric tube has been reported sporadically, malpositioning of nasogastric tubes in the tracheobronchial tree appears to be more common.¹¹

The rate of inadvertent insertion of nasogastric and nasointer tubes into the trachea and distal airways ranges from 0.3% to 15%.^{10,12,13} Both penetration of the airways and the introduction of several chemicals into the lung and the pleural spaces may occur before it is recognized that the tube has been incorrectly placed. Bankier et al¹⁰ found a pneumothorax in 4 of 14 cases with tracheobronchial intubation of nasogastric tubes. Such complications may be fatal.¹⁴

Physical examination is often a poor predictor of tube misplacement.^{10,13,15} In our case, the 2 confirmatory maneuvers—

From the Neurologische Klinik, Martin-Luther-Universität Halle, Halle, Germany (Winterholler); and the Neurologische Klinik, Klinikum Nürnberg, Germany (Erbguth).

No commercial party having a direct financial interest in the results of the research supporting this article has or will confer a benefit upon the author(s) or upon any organization with which the author(s) is/are associated.

Reprint requests to Martin Winterholler, MD, PhD, Neurologische Klinik, Martin-Luther-Universität Halle, Ernst-Grube-Str 40, D-06097 Halle, Germany, e-mail: martin.winterholler@medizin.uni-halle.de.

0003-9993/02/8308-6785\$35.00/0

doi:10.1053/apmr.2002.33643

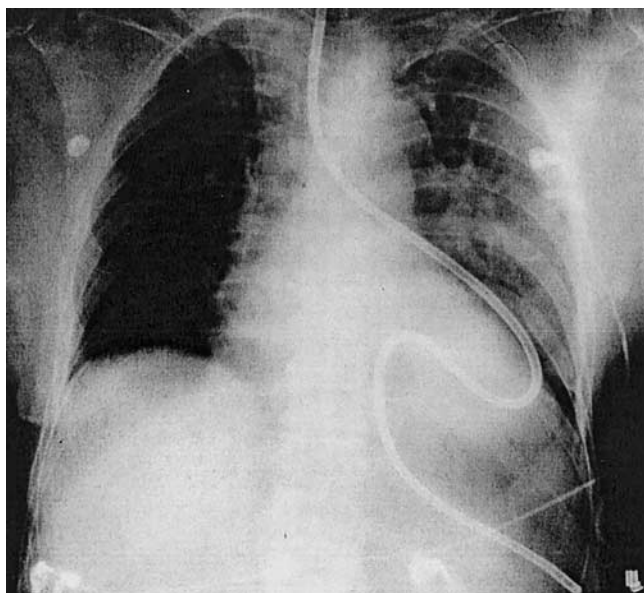


Fig 1. Chest radiograph showing misplacement of a nasogastric tube. The tube was inserted down the left mainstem bronchus into the left lung penetrating the pleura, resulting in left-side pneumothorax and iatrogenic hydrothorax.

aspiration of fluid and auscultating the abdomen on insufflating air—were false-positive.

Therefore, the traditional criteria for appropriate tube positioning are not applicable for critically ill patients or the mentally ill and patients with disorders of perception for the following reasons. Insufflation of air with sounds heard over the region of the stomach should not be accepted as evidence of gastric placement because small bore tubes do not always allow sufficient passage of air. Moreover, air bubbling in the pleura, lung, or esophagus may be transmitted below the diaphragm.⁴ Aspiration of fluid should not be interpreted as appropriate placement in the stomach because fluid aspirated may come from the pleural space, from bronchial secretions, or even from the brain.¹¹ If the tube passes the full length and an eventual guide wire is removed easily, the tubing is thought to be straight and unlikely to be kinked or coiled up in the lung. However, several reports^{6,16} refute this claim.

Radiographic imaging is commonly used to confirm the position of the tube; it is strongly recommended in all cases with neurologic or mental deficits, as well as in cases with diminished consciousness, especially before the tube is used for enteral feeding or the instillation of drugs and other substances.^{12,13} However, the radiograph may be misinterpreted^{17,18}; in a series of 11 patients with misplaced nasogastric tubes, the fault position was not identified in 3 cases (27%).¹⁴ The majority of the reported patients with intrapulmonary or pleural misplacement of the nasogastric tube were comatose or intubated.^{2,4,6-14} But patients with disorders of perception or other acute neurologic diseases may also be at high risk.

CONCLUSION

Only radiologic confirmation of the position of nasogastric tubes and the awareness of the associated dangers will help minimize the occurrence of such events in patients with disorders of perception or altered consciousness. Furthermore, newly developed guide wire Dobhoff feeding tubes, which are softer than conventional nasogastric tubes, can be positioned in the proximal small bowel with radiologic confirmation. This procedure reduces the risk of reflux and aspiration.¹⁹

References

1. Boyes RJ, Kruse JA. Nasogastric and nasoenteric intubation. *Crit Care Clin* 1992;8:865-72.
2. Vaughan ED. Hazards associated with narrow-bore nasogastric tube. *Br J Oral Maxillofac Surg* 1981;19:151-4.
3. Tucker A, Lewis J. Passing a nasogastric tube. *BMJ* 1980;281:1128-9.
4. Miller KS, Tomlinson JR, Sahn SA. Pleuropulmonary complications of enteral feeding tubes. *Chest* 1985;88:130-3.
5. McWay RE, Curry NS, Schnabel SI, Reines HD. Complications of nasoenteric feeding tubes. *Am J Surg* 1988;155:253-7.
6. James HJ. An unusual complication of passing a narrow-bore nasogastric tube. *Anesthesiology* 1978;33:716-8.
7. Schorlemmer GR, Battaglini JW. An unusual complication of naso-enteral feeding with small-diameter feeding tubes. *Ann Surg* 1984;199:104-6.
8. Hand RW, Kempster M, Levy JH, Rogol PR, Spirn P. Inadvertant transbronchial insertion of narrow-bore feeding tubes into the pleural space. *JAMA* 1984;251:2396-7.
9. Aronchick JM, Epstein DM, Geffer WB, Miller WT. Pneumothorax as a complication of placement of a nasoenteric tube. *JAMA* 1984;252:3287-8.
10. Bankier AA, Wiesmayr MN, Henk C, et al. Radiographic detection of intrabronchial malpositions of nasogastric tubes and subsequent complications in intensive care patients. *Intensive Care Med* 1997;23:406-10.
11. Fremsted JD, Martin SH. Lethal complication from insertion of nasogastric tube after severe basilar skull fracture. *J Trauma* 1978;18:820-2.
12. Hendry PJ, Akyurekli Y, McIntyre R, Quarrington A, Keon J. Bronchopleural complications of nasogastric feeding tubes. *Crit Care Med* 1986;14:892-94.
13. Thomas B, Cummin D, Falcone RE. Accidental pneumothorax from a nasogastric tube [letter]. *N Engl J Med* 1996;335:1325.
14. Torrington KG, Bowman MA. Fatal hydrothorax and empyema complicating a malpositioned nasogastric tube. *Chest* 1981;79:240-2.
15. Nakao MA, Killam D, Wilson R. Pneumothorax secondary to inadvertent placement of nasoenteric tube past a cuffed endotracheal tube. *Crit Care Med* 1983;11:210-11.
16. Culpepper JA, Veremakis C, Guntapalli KK, Sladen A. Malpositioned nasogastric tube causing pneumothorax and bronchopleural fistula [letter]. *Chest* 1982;81:390.
17. Wechsler RJ, Steiner RM, Kinori I. Monitoring the monitors: the radiology of thoracic catheters, wires, and tubes. *Semin Roentgenol* 1988;23:61-84.
18. Perlman SJ, Rogers LF, Mintzer RA, Mueller CF. Abnormal course of a nasogastric tube in traumatic rupture of left hemidiaphragm. *AJR Am J Roentgenol* 1985;142:85-8.
19. Harrison AM, Clay B, Grant MJ, et al. Nonradiographic assessment of enteral feeding tube position. *Crit Care Med* 1997;25:2055-9.