

Distal Anterior Inferior Cerebellar Artery Syndrome After Acoustic Neuroma Surgery

*Joseph L. Hegarty, *†Robert K. Jackler, ‡Peter L. Rigby, *†Lawrence H. Pitts,
and *Steven W. Cheung

*Departments of Otolaryngology–Head and Neck Surgery and †Neurological Surgery, University of California, San Francisco, San Francisco, California; and ‡Department of Otorhinolaryngology and Biocommunication, Louisiana State University, New Orleans, Louisiana, U.S.A.

Objective: To define a clinicopathologic syndrome associated with persistent cerebellar dysfunction after acoustic neuroma (AN) excision.

Study Design: Case series derived from radiographic and clinical chart review.

Setting: Tertiary referral center.

Patients: In 12 patients with AN, persistent cerebellar dysfunction developed after AN removal. Each case demonstrated abnormality in the ipsilateral cerebellar peduncle on postoperative magnetic resonance imaging.

Main Outcome Measures: Cerebellar function and ambulatory status over the first postoperative year.

Results: On magnetic resonance imaging scans, the extent of cerebellar peduncle infarcts was variable. It ranged from focal brain injury (<1 cm) involving only one third of the peduncle to diffuse defects (>2 cm) spanning the full thickness of the peduncle. Peduncular infarcts were associated with large tumor size (average 3.8 cm, range 2.0–5.5 cm diameter). The long-term functional outcomes (>1 yr) varied. Dysmetria was unchanged or improved in over half of the patients (6 of 11

patients). Gait recovered to normal or to preoperative levels in 5 patients. In the 6 patients with persistent impaired mobility, 2 had mild gait disturbance, 3 required regular use of a cane, and 1 has been dependent on a walker. One patient had sustained mild motor weakness. Three of 11 patients remained dependent on others for activities of daily living.

Conclusions: Peduncle injury most likely stems from interruption of distal branches of the anterior inferior cerebellar artery (AICA). These small vessels are intimately related to the capsule of the tumor and may supply both the neoplasm and the brain parenchyma. It has long been recognized that interruption of the proximal segment of the AICA results in severe injury to the pons, with devastating neurologic sequelae. A limited AICA syndrome caused by loss of its distal ramifications seems a more plausible explanation for peduncular infarction than either venous insufficiency or direct surgical trauma. **Key Words:** Acoustic neuroma—Anterior inferior cerebellar artery—Cerebellar dysfunction.

Otol Neurotol 23:560–571, 2002.

Persistent cerebellar dysfunction is an uncommon complication of microsurgical acoustic neuroma (AN) removal. Most authors have attributed this postoperative deficit to surgical trauma from one of two mechanisms: retraction injury of the lateral cerebellar hemisphere or vascular compromise with attendant ischemia of brainstem vestibular nuclei (1). The widespread use of magnetic resonance imaging (MRI) to evaluate brain dysfunction confers an opportunity to correlate imaging findings with neurologic deficits. While reviewing the postoperative MRI scans of several such patients with postoperative dysmetria, we recognized a characteristic pattern of abnormality in the ipsilateral cerebellar peduncle. This motivated us to perform a systematic review of the clinical and imaging characteristics of a series of

patients with postoperative cerebellar dysfunction. Hypotheses for the site of lesion and probable mechanism of operative injury were developed to explain the findings.

MATERIALS AND METHODS

Study design

A retrospective review of clinical records and imaging material of postoperative AN patients with persistent cerebellar dysfunction was performed. This study was reviewed and approved by the Committee on Human Research at the University of California, San Francisco (UCSF). From 1980 to 2000, 564 patients who underwent AN surgery at UCSF and had complete medical records available were reviewed. Twelve patients with worsened postoperative cerebellar function and a postoperative MRI scan showing a focal cerebellar peduncular lesion were identified. One patient in this report (illustrative case) was treated surgically at another institution but was included to show the clinical findings of a classic full anterior inferior cerebellar artery (AICA) syndrome. Vestibulo-cerebellar func-

Address correspondence and reprint requests to Steven W. Cheung, M.D., Box 0342 400, Parnassus Avenue, Suite A-730, San Francisco, CA 94143-0342, U.S.A. Email: cheung@phy.ucsf.edu

tion was assessed by use of the following clinical measures: motor function, cerebellar function, ambulatory status, and independence of activity. The time intervals for analysis were these: preoperatively; before hospital discharge; and 2 to 3 weeks, 4 to 6 months, and 1 year postoperatively. All patients underwent preoperative and postoperative MRI, including T1-, T2-, and postgadolinium T1-weighted images of the cerebellopontine angle (CPA). Clinical case summaries were prepared, with illustrative preoperative (when available) and postoperative MRI findings.

RESULTS

Cerebellar peduncular infarctions: case studies

Figures 1 through 3 show the preoperative and postoperative MRI scans in Cases 1 through 12.

Case 1

A 53-year-old woman had experienced gradual unilateral sensorineural hearing loss and mild positional vertigo but normal gait. She had a 3-cm AN (with both solid and cystic components) compressing the brainstem and deforming the fourth ventricle. During translabyrinthine removal, multiple small vessels lay on the tumor/brainstem interface. The tumor was completely removed. Postoperatively, she experienced severe dysmetria and dysarthria, which improved over the early postoperative months. She required rehabilitation for a gait disturbance that improved during 6 months to walking with a cane. At 1 year, she ambulated independently but had a somewhat unsteady wide-based gait. Early post-

operative MRI scans revealed a transmural area of altered signal intensity (low T1, high T2) in the cerebellar peduncle.

Case 2

A 70-year-old man had experienced new-onset seizures, hearing loss, facial paresthesia, and slight imbalance. She had a 2-cm AN. During translabyrinthine excision, near-total removal was elected because of the intimate adherence of the tumor to the facial nerve. Postoperatively, the patient experienced moderate dysmetria and imbalance, requiring a walker. These deficits resolved completely within 6 months. A 1-year postoperative MRI scan revealed a small focal defect in the middle and proximal superior cerebellar peduncles.

Case 3

A 52-year-old man had experienced progressive sensorineural hearing loss and blepharospasm but no disturbance of balance. There was a 4.5-cm AN with marked brainstem compression. During translabyrinthine excision, the tissue planes were poor, and a small branch of the AICA traversing the tumor was divided during dissection. The main trunk of the AICA remained intact, and the tumor was completely excised. Postoperatively, the patient experienced dysarthria and an unstable gait, requiring a walker, which improved over the following year. At 1 year, he still continued to have some unsteadiness but ambulated independently. An early postoperative MRI scan demonstrated a 2.5-cm area of high signal

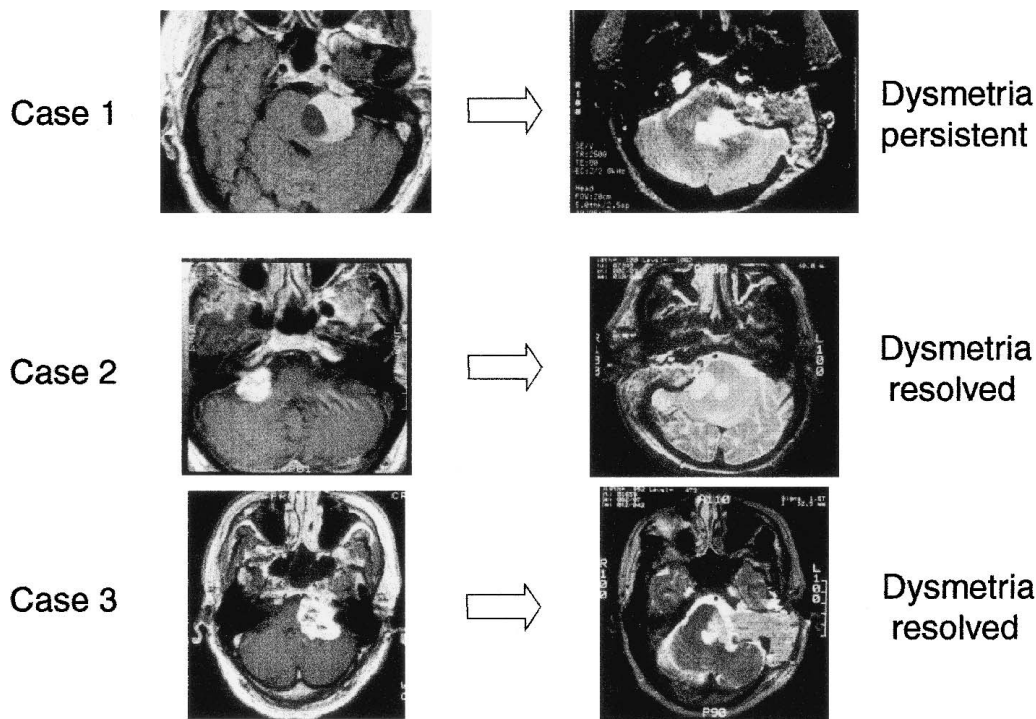


FIG. 1. Preoperative and postoperative magnetic resonance imaging scans for Cases 1 through 3: patients with focal cerebellar peduncle infarction.

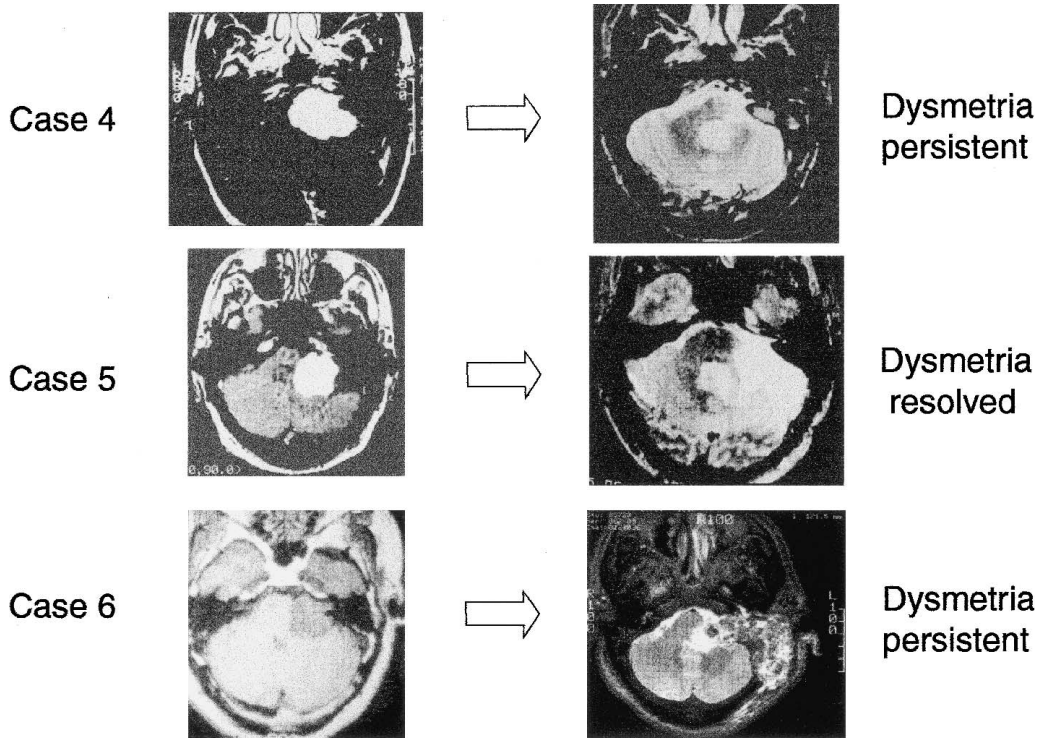


FIG. 2. Preoperative and postoperative magnetic resonance imaging scans for Cases 4 through 6: patients with focal cerebellar peduncle infarction.

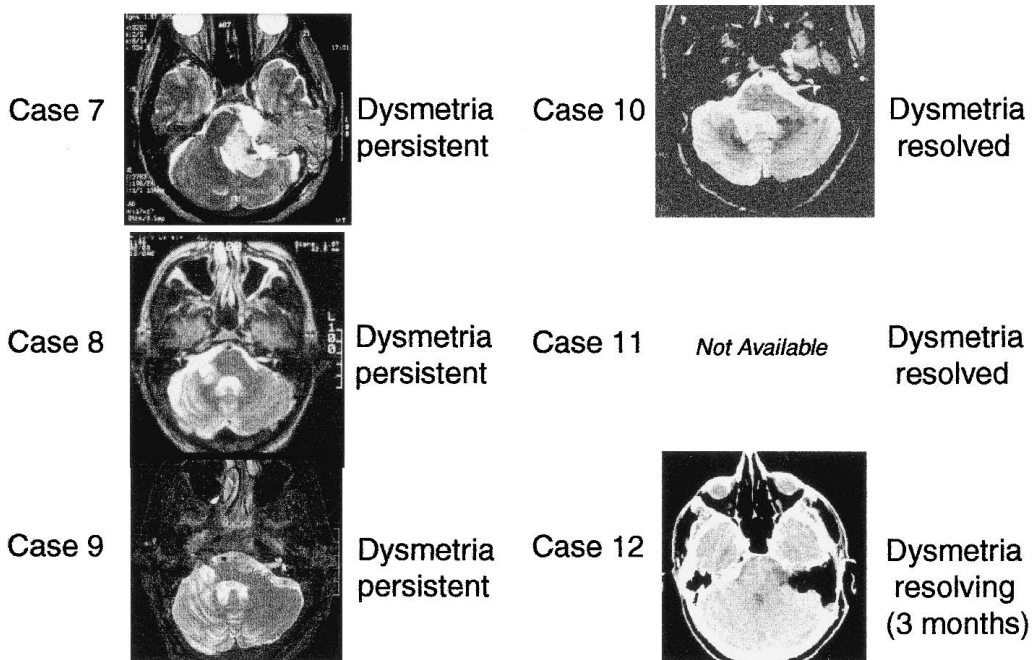


FIG. 3. Postoperative magnetic resonance imaging scans in cases 7 through 10 and 12: patients with focal cerebellar peduncle infarction.

intensity in the middle and superior cerebellar peduncles on T2-weighted images.

Case 4

A 59-year-old man had experienced progressive hearing loss and facial paresthesias but no disturbance of balance. He had a 4.8-cm AN, with fourth ventricle compression and severe brainstem shift. After translabyrinthine excision, he experienced severe gait disturbance that necessitated the use of a wheelchair for 6 months. By 1 year he was ambulating with a walker. He also had a mild residual ipsilateral lower extremity motor weakness. His 1-year postoperative MRI scan revealed a well-demarcated 1.5-cm defect in the cerebellar peduncles, which extended from the superficial pial surface almost to the wall of the fourth ventricle.

Case 5

A 48-year-old man had experienced progressive unilateral sensorineural hearing loss and no disturbance of balance, but a Romberg examination showed a positive result (tendency to fall to the right). A 4-cm AN with substantial cerebellar and brainstem compression was excised via the retrosigmoid approach. The tumor was adherent to adjacent brain structures, and numerous bridging vessels were interrupted during tumor removal. Early postoperatively, the patient had mild dysmetria and required a walker for ambulation. By 1 year postoperatively, the dysmetria had resolved, but the imbalance required the continued use of a cane. A 1-year postoperative MRI scan revealed a 1- × 2-cm oval defect in the middle and superior cerebellar peduncles. This involved approximately two thirds the thickness of the peduncle. Encephalomalacia of the lateral one third of the cerebellum was also evident.

Case 6

A 52-year-old man had experienced long-standing sensorineural hearing loss and trigeminal dysfunction but no disturbance of balance. A 3.5-cm AN was completely removed via the translabyrinthine approach. Postoperatively, he had limb dysmetria and gait ataxia. Initially he required the use of a cane. By 8 months postoperatively he was able to ambulate independently, with mild residual imbalance. Mild ipsilateral hand clumsiness also persisted. Early postoperative MRI scans revealed a focal 1-cm abnormality of the lateral aspect of the middle cerebellar peduncle, manifested by mixed signal intensity (both high and low) on T1-weighted sequences. The lesion involved approximately one half of the thickness of the peduncle.

Case 7

A 21-year-old woman had experienced bifrontal headaches and weakness of the left arm for 7 months, preceded by balance disturbance for 5 years. Interestingly, her audiogram was completely normal except for absence of acoustic reflexes. A 5-cm AN on the left side was entirely removed via the translabyrinthine approach.

Facial nerve anatomic discontinuity was managed with a hypoglossal-facial nerve anastomosis. Postoperatively, left upper extremity dysmetria and a positive Romberg test result persisted for more than 1 year, but the patient ambulated independently without assistance. Early postoperative MRI scans showed a large infarct of the middle and superior cerebellar peduncles, characterized by high signal intensity on T2-weighted images and a mixed signal on T1-weighted images, consistent with infarction.

Case 8

A 44-year-old man had experienced progressive sensorineural hearing loss but no disturbance of balance. A 2.9-cm AN effaced the cerebellar peduncle and cerebellum. During retrosigmoid excision, dense capsular adhesions were encountered at the root entry zone of the VIIth and VIIIth cranial nerves, and a small branch of the AICA was electrocoagulated during dissection. The main AICA trunk was preserved. Postoperatively, the patient experienced mild dysmetria, which persisted at his 1-year follow-up examination. A walker was required for ambulation in the early postoperative period, with improvement to normal gait by 6 months. Late postoperative MRI scans revealed a focal defect, approximately 1 × 1 cm in diameter, in the cerebellar peduncle, spanning approximately one third of its thickness.

Case 9

A 71-year-old woman with a 9-year history of unilateral hearing loss, a 3-year history of progressive dysequilibrium, and recent difficulty with handwriting had a 4-cm cystic AN. Her audiogram was significant for trace asymmetry in the low frequencies but a moderate loss of unilateral speech discrimination. Cerebellar examination showed mild dysdiadochokinesia and normal gait. A near-total (98%) translabyrinthine excision was performed, during which an AICA arterial branch on the lateral tumor surface was divided. Postoperatively, significant ipsilateral dysmetria with ataxic gait required the full-time use of a cane for 2 months. Over the ensuing months, she improved to using a cane intermittently. At 1 year, she continued to have persistent dysmetria with ataxia. A postoperative MRI scan at that time showed significant encephalomalacia of the middle and superior cerebellar peduncles and cerebellum.

Case 10

A 27-year-old woman had experienced progressive vertigo and imbalance, hearing loss, and unilateral facial paresthesia. A 4.5-cm AN with fourth ventricle compression and deep pontine indentation was completely excised via the translabyrinthine approach. The tumor/brain dissection plane was poor; there were multiple bridging vessels. Postoperatively, she experienced mild dysmetria and unstable gait. At 1 year, her dysmetria resolved and her gait was substantially improved; however, she had an abnormal Romberg test result.

Case 11

A 25-year-old woman had experienced progressive sensorineural hearing loss, facial numbness, and episodic imbalance associated with head motion. Her gait was normal, but she was unsteady on tandem walk testing. A 3.8-cm AN with brainstem compression and fourth ventricle distortion was completely excised via a translabyrinthine craniotomy. Her postoperative course was complicated by a wound cerebrospinal fluid leak requiring temporary lumbar drainage, mild dysmetria and imbalance, and a choreiform movement disorder that developed 2 weeks postoperatively (presumably Sydenham chorea related to a previous streptococcal infection). Her cerebellar dysfunction resolved completely by 4 months postoperatively. One year after surgery, MRI scans revealed volume loss of the cerebellar peduncles with secondary dilation of the fourth ventricle lateral recess.

Case 12

A 50-year-old man had experienced progressive facial hypesthesia, gait disturbance, hearing loss, and slurred speech for 1 year. An audiogram revealed minimal threshold asymmetry and well-preserved speech discrimination. Physical examination confirmed trigeminal anesthesia, bidirectional end gaze nystagmus, mild dysdiadochokinesis, and a broad-based gait. A 3.5-cm AN without subpial T2 signal abnormality was near-totally excised (96%) via the translabyrinthine approach. During tumor dissection, an inferior pole AICA branch was interrupted. Postoperatively, obstructive hydrocephalus required limited external ventriculostomy drainage. Other postoperative findings included loss of contralateral pain and temperature sensation and marked ipsilateral dysmetria. He is currently convalescing at home with the occasional use of a cane. Immediately postoperative com-

puted tomography revealed hypointensity of the middle and superior cerebellar peduncles.

**Peduncular and lateral brainstem infarction
(complete anterior inferior cerebellar
artery syndrome)**

In this illustrative case, a 51-year-old man had experienced progressive hearing loss. A 3-cm AN was excised at an outside facility via the retrosigmoid approach, and the patient was referred to UCSF for postoperative evaluation. His postoperative course was complicated by early postoperative hemorrhage requiring reexploration and evacuation. He remained comatose for 6 weeks. At 1 year postoperatively he had multiple deficits, which included ataxia, dysmetria, dysdiadochokinesis, dysarthria, dysphagia, seizures, ipsilateral facial anesthesia, facial palsy, and contralateral upper and lower extremity dysesthesias. He was wheelchair bound. The late 1-year postoperative MRI scan showed infarction of the lower lateral pons and middle and superior cerebellar peduncles (transmural), and cerebellar encephalomalacia (Fig. 4).

Summary data*Patient characteristics*

The mean age of the patient group was 47 years (range, 21–71 yr), and the mean tumor size was 3.8 cm (range, 2.0–5.5 cm). The surgical approach chosen was translabyrinthine in 10 of the 12 patients and retrosigmoid in 2. Twelve cases of focal cerebellar peduncle infarctions were identified in 564 cases reviewed. The lower bound estimate for the incidence of cerebellar peduncle infarction after AN surgery is 2.1%. Patients with focal infarction and clinically silent or insignificant sequelae would not have been captured by this retrospec-

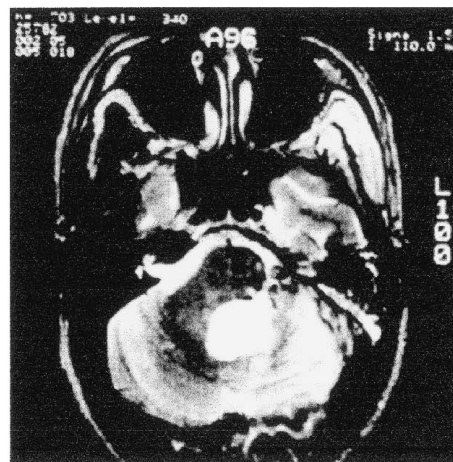
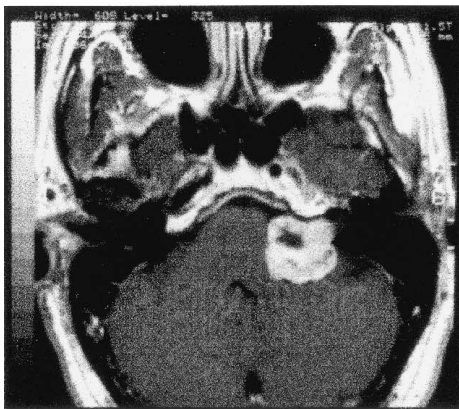
Illustrative Case - Full AICA Syndrome

FIG. 4. Preoperative and postoperative magnetic resonance imaging scans in an illustrative case of full anterior inferior cerebellar artery syndrome. Note the complete involvement of the cerebellar peduncles and cerebellar encephalomalacia.

tive review. Because of the positive correlation of peduncular infarction with tumor size, a stratified estimate based on large tumors is warranted. During the past 20 years, 87 tumors larger than 3 cm were surgically treated. When adjustment was made for large tumors, the incidence of distal AICA infarction increased to 13% (11/87).

Clinical findings

Table 1 summarizes the clinical findings for the study cohort. On preoperative neurotologic examination, 5 of 12 patients had evidence of mild cerebellar dysfunction, manifested as dysmetria, dysdiadochokinesis, and truncal sway. Cerebellar dysmetria was unchanged or improved in 6 of 11 patients (55%), compared with their preoperative assessment, who were followed up for at least 1 year. In the immediate postoperative period, the patients' ambulatory status was as follows: 2 patients were bedridden or wheelchair bound, 7 required a walker, and 2 had an unstable or wide-based gait. The gait at the 1-year evaluation was better or the same as the preoperative state in 5 patients (45%) and worse in 6 patients (55%). In the latter group, 2 patients had mild gait disturbance, 3 required the regular use of a cane, and 1 has been dependent on a walker. Three of 12 patients had new motor weakness; 1 had resolved by the 4th-month visit, 1 had resolved by the 1-year visit, and 1 persisted at 1 year. All 3 patients had large (>3 cm) tumors and marked brainstem compression. This subgroup of patients also had postoperative dysarthria (1 persisted at 1 year, 2 resolved). Activities of daily living at 1 year were significantly restricted in 3 of 11 patients (27%) because of ongoing dependency on other persons.

DISCUSSION

Anatomy of the anterior inferior cerebellar artery

The AICA and the small arteries from the dura of the internal auditory canal provide the main arterial supply to ANs. In large tumors, the superior cerebellar artery may drape the upper surface, whereas the posterior inferior cerebellar artery (PICA) may lie subjacent to the inferior pole of the tumor. The AICA origination from the basilar artery is distributed in the following manner: proximal third, 52%; middle third, 46%; and distal third, 2% (2). Duplication of the AICA occurs in 11 to 26% of persons in various reports, and triplication may occur but is rare. Occasionally, the AICA is absent, and its vascular territory is supplied by the PICA. The AICA generally arises as the first large branch of the basilar artery and has a diameter less than 1.25 mm. Although its point of origin and areas of distribution are somewhat variable, it usually courses laterally at the level of the pons to the region of the VIIth and VIIIth cranial nerves, often giving off small arteries into the pons and the middle cerebellar peduncle and more deeply to the proximal portion of the superior cerebellar peduncle. After passing close to this root entry zone, the main trunk most commonly divides into two branches. One branch travels laterally

toward the porus acusticus, where it gives off the labyrinthine artery and then continues to supply the lateral side of the middle cerebellar peduncle and cerebellum. The other branch courses inferiorly and laterally to supply the lower portion of the cerebellum and may also supply part of the middle and superior peduncles. Long pontine arteries arise directly from the basilar artery and variably supply the pons and middle cerebellar peduncle and the deep portions of the superior cerebellar peduncle.

From the perspective of the AN surgeon, the AICA possess two loops (Fig. 5). The first is formed by the main AICA trunk, which lies draped in a lazy C-shaped course on the pontine surface. The second, more lateral loop is formed from one of the distal branches, which lies near the porus acusticus (3). This secondary loop penetrates into the internal auditory canal in 40% of cases. Occasionally the labyrinthine artery arises directly from the basilar artery. Throughout its course within the CPA, the AICA gives off a variable number of small branches. In its proximal segment, AICA tributaries supply the pons. More distal branches supply the flocculus and middle cerebellar peduncle and the initial portion of the superior cerebellar peduncle.

The territory consistently supplied by the AICA and its tributaries includes the middle and parts of the superior cerebellar peduncles, the inferior portion of the cerebellum, the contents of the internal auditory canal, and the flocculus. The AICA gives a variable contribution to the lateral portion of the pons and upper lateral medulla (4). The lateral branch supplies small branches to the flocculus, the cerebellar peduncle, the adjacent pons and lateral medulla, and the middle cerebellar hemisphere (5,6). Although superficial anastomoses with the PICA and the superior cerebellar artery are not uncommon, penetrating vessels are regular in course, with few or no anastomoses. Thus, the variability of clinical sequelae arising from injury to the AICA is attributable to variability of AICA branch area distribution and frequent superficial arterial anastomotic networks (7).

Consequences of injury to the anterior inferior cerebellar artery

The lateral pontomedullary syndrome, or AICA syndrome, manifests as hearing loss, nausea, vertigo, ataxia, and contralateral beating nystagmus. Other concomitant deficits include ipsilateral facial numbness or weakness, ipsilateral Horner syndrome, abnormal saccadic gaze to the ipsilateral visual field, contralateral paresthesia of the body, and, less frequently, bulbar palsy (7,8) (Table 2). Variable clinical manifestations may result, depending on the degree of collateral flow supplying the ischemic areas (Fig. 6). Ischemia of the cochlear and vestibular nuclei within the anterolateral pons results in deafness, vertigo, and nystagmus. Ischemia of facial nerve fibers and/or the adjacent facial nucleus results in facial paresis. Ischemia of the cerebellar flocculus may produce gaze-evoked nystagmus.

Deafness, dizziness, and facial disfigurement are relatively common in AN, so this constellation of symptoms

TABLE 1. *Cerebellar peduncular infarction: clinical information*

| | Motor evaluation | Cerebellar evaluation | Ambulatory status | Activity |
|-----------------------------|------------------|--|----------------------|-------------|
| Case 1: 3.0 cm TL | | | | |
| Preoperatively | Normal | Normal | Normal gait | Independent |
| Immediately postoperatively | 4/5 | Severe dysmetria with dysarthria | Bed bound | Dependent |
| First visit | 4/5 | | Walker | Dependent |
| 4–6 month visit | Normal | | Cane | Dependent |
| 1 year | Normal | Mild tremor with dysdiadochokinesis | Wide-based gait | Dependent |
| Case 2: 2.0 cm TL | | | | |
| Preoperatively | Normal | Normal | Normal gait | Independent |
| Immediately postoperatively | Normal | Moderate dysmetria | Walker | Dependent |
| First visit | Normal | Mild dysmetria | Cane | Dependent |
| 4–6 month visit | Normal | Dysmetria resolved | Normal gait | Independent |
| 1 year | Normal | Normal | Normal gait | Independent |
| Case 3: 4.5 cm TL | | | | |
| Preoperatively | Normal | Normal | Unstable gait | Independent |
| Immediately postoperatively | 4/5 | Mild dysarthria | Walker | Dependent |
| First visit | 4/5 | Dysarthria resolved | Walker | Independent |
| 4–6 month visit | 4/5 | Normal | Cane | Independent |
| 1 year | Normal | Normal | Mildly abnormal gait | Independent |
| Case 4: 4.8 cm TL | | | | |
| Preoperatively | Normal | Normal | Normal gait | Independent |
| Immediately postoperatively | 3/5 | Severe dysmetria and dysarthria | Wheelchair | Dependent |
| First visit | 4/5 | | Wheelchair | Dependent |
| 4–6 month visit | 4/5 | | Wheelchair | Dependent |
| 1 year | 4/5 | Mild dysmetria, dysarthria, and dysdiadochokinesis | Walker | Dependent |
| Case 5: 4.0 cm RS | | | | |
| Preoperatively | Normal | Truncal sway | Normal gait | Independent |
| Immediately postoperatively | Normal | Mild dysmetria | Walker | Dependent |
| First visit | Normal | | Cane | Independent |
| 4–6 month visit | Normal | | Cane | Independent |
| 1 year | Normal | Normal | Cane | Independent |
| Case 6: 3.5 cm TL | | | | |
| Preoperatively | Normal | Normal | Normal gait | Independent |
| Immediately postoperatively | Normal | Mild dysmetria | Walker | Dependent |
| First visit | Normal | Mild dysmetria | Walker | Dependent |
| 4–6 month visit | Normal | Mild dysmetria | Cane | Dependent |
| 1 year | Normal | Mild dysmetria | Cane | Dependent |
| Case 7: 5.5 cm TL | | | | |
| Preoperatively | 4/5 | Mild dysmetria | Normal gait | Independent |
| Immediately postoperatively | 4/5 | Moderate dysmetria | Walker | Dependent |
| First visit | 4/5 | Moderate dysmetria | Walker | Dependent |
| 4–6 month visit | Normal | Mild dysmetria | Cane | Independent |
| 1 year | Normal | Mild dysmetria | Cane | Independent |
| Case 8: 2.9 cm RS | | | | |
| Preoperatively | Normal | Normal | Normal gait | Independent |
| Immediately postoperatively | Normal | Mild dysmetria | Walker | Independent |
| First visit | Normal | Mild dysmetria | Wide-based gait | Independent |
| 4–6 month visit | Normal | Mild dysmetria | Normal gait | Independent |
| 1 year | Normal | Mild dysmetria | Normal gait | Independent |
| Case 9: 3.5 cm TL | | | | |
| Preoperatively | Normal | Trace dysmetria | Normal gait | Independent |
| Immediately postoperatively | Normal | Severe dysmetria | Walker | Dependent |
| First visit | Normal | Severe dysmetria | Walker | Dependent |
| 4–6 month visit | Normal | Moderate dysmetria | Cane | Independent |
| 1 year | Normal | Moderate dysmetria | Occasional cane | Independent |
| Case 10: 4.5 cm TL | | | | |
| Preoperatively | Normal | Normal | Unstable gait | Independent |
| Immediately postoperatively | Normal | Mild dysmetria | Unstable gait | Independent |
| First visit | Normal | Dysmetria resolved | Normal | Independent |
| 4–6 month visit | Normal | Normal | Normal | Independent |
| 1 year | Normal | Normal | Normal | Independent |

(Table continues)

does not point to vascular injury. The distinguishing clinical finding is ipsilateral dysmetria, caused by ischemia of the cerebellar outflow tracts through the superior cerebellar peduncle. In addition, the loss of contralateral

pain and temperature sensation attributable to injury of the spinothalamic sensory tracts implicates AICA ischemia. Contralateral hemiplegia is occasionally seen when the pyramidal tracts are compromised. Severe brainstem

TABLE 1. *Continued*

| | Motor evaluation | Cerebellar evaluation | Ambulatory status | Activity |
|-----------------------------|------------------|-------------------------|-------------------|-------------|
| Case 11: 3.8 cm TL | | | | |
| Preoperatively | Normal | Mild dysmetria | Wide-based gait | Independent |
| Immediately postoperatively | Normal | Mild dysmetria | Wide-based gait | Independent |
| First visit | Normal | Dysmetria resolved | Normal gait | Independent |
| 4–6 month visit | Normal | Normal | Normal gait | Independent |
| 1 year | Normal | Normal | Normal gait | Independent |
| Case 12: 3.5 cm TL | | | | |
| Preoperatively | Normal | Mild dysdiadochokinesis | Broad-based gait | Independent |
| Immediately postoperatively | Normal | Severe dysmetria | Cane | Independent |
| First visit | Normal | Moderate dysmetria | Cane | Independent |

TL, translabyrinthine; RS, retrosigmoid.

and cerebellar deficits may require prolonged hospitalization and rehabilitation, or result in death. Acute vertigo improves over time, but positional nystagmus and cerebellar deficits are often permanent (1).

Early reports of AICA interruption highlight the ubiquitous cerebellar and vestibular findings, associated with variable watershed brainstem ischemia. In 1936, Goodhart and Davison (9) provided an early clinical description with pathologic confirmation of partial AICA occlusion. The patient's signs and symptoms included dizziness, vomiting, headaches, ataxia, ipsilateral extremity clumsiness and intention tremor, ipsilateral facial weakness, episodes of choking and dyspnea, and ocular signs of elevated intracranial pressure. Significant lateral cerebellar destruction was observed on postmortem review. In 1943, Adams (10) described a patient with tinnitus, nausea and vomiting, and positional vertigo, progressing to unilateral facial palsy, anacusis, Horner syndrome, and trigeminal nerve anesthesia. Ataxia, intention tremor, and dysmetria in the ipsilateral upper and lower extremities were observed. The patient died in congestive heart failure, and subsequent pathologic investigation revealed thrombotic occlusion of the AICA with infarction of the inferior cerebellum, peduncle, lateral middle and lower pons, and lateral upper medulla (small volume) (8,10). In 1949, Atkinson (11) illuminated the pathologic sequelae of intraoperative AICA disruption during AN surgery when he chronicled neurologic devastation and death in six patients. Before this thoughtful investigation, the typical clinical and pathologic changes of AICA disruption were widely believed to be caused by pontine laceration. Little consideration was given to maintaining the integrity of the AICA during AN surgery (11). This is exemplified in the treatise by Dandy (12) on AN surgery:

“As the capsule is cautiously retracted, several small blood vessels crossing from the brainstem or cerebellum are brought into view and doubly ‘clipped’ and the vessel divided. Practically all bleeding can be forestalled in this way....Naturally the vessels causing greatest concern are the arteries which cross from the brainstem to the tumor. There are usually three to six of these vessels in addition to two to three from the inferior surface of the cerebellum. Though constituting the greatest danger of the operation, there is, however, no great difficulty in either exposing or ligating these vessels” (12).

In 1981, Perneczky et al. (8) reported three clinical

presentations of caudolateral pontine ischemia caused by AICA occlusion. One case involved an iatrogenic AICA syndrome after AN surgery, which resolved after the application of papaverine to an AICA vessel in spasm at the time of reexploration. In 1993, Amarenco et al. (4) expanded the literature by describing 20 pathologic cases of atherosclerotic occlusion of the AICA. All cases involved the cerebellar peduncles. Infarction extended variably to the brainstem and cerebellum, with frequent compromise of the lateral aspect of the middle and lower pons. More recently, Biavati et al. (13) described MRI findings of a postischemic edematous focus involving the lateral inferior pons and cerebellar peduncle in a

TABLE 2. *Anterior inferior cerebellar artery: clinicopathologic correlates of ischemia*

| |
|---|
| Vascular territory |
| Brainstem (Lower pons and superior lateral medulla) |
| Pontine cranial nerve nuclei: V (motor and sensory), VII, VIII |
| Medullary cranial nerve nuclei: IX, X |
| Lateral reticular formation |
| Long tracts |
| Anterolateral spinothalamic (contralateral pain and temperature) |
| Medial lemniscus (ipsilateral motor) |
| Descending sympathetic pathways |
| Middle cerebellar peduncle |
| Pontocerebellar tract |
| Superior cerebellar peduncle |
| Efferent tracts from dentate and globose/emboliform cerebellar nuclei to red nucleus and ventrolateral thalamus |
| Cerebellum |
| Flocculus |
| Biventral lobes, lateral portion |
| Superior and inferior semilunar lobes |
| Clinical signs of ischemia |
| Cerebellar ataxia and dysmetria ^a |
| Hearing loss ^a |
| Vertigo ^a |
| Nystagmus ^a |
| Facial hypesthesia ^a |
| Dysarthria (ataxic) |
| Horner syndrome |
| Facial paralysis (peripheral pattern) |
| Dysphagia |
| Dysphonia |
| Palatal myoclonus |
| Hemiparesis (contralateral) |
| Hypesthesia (contralateral body) |

^aFrequent manifestation, ipsilateral except where noted.

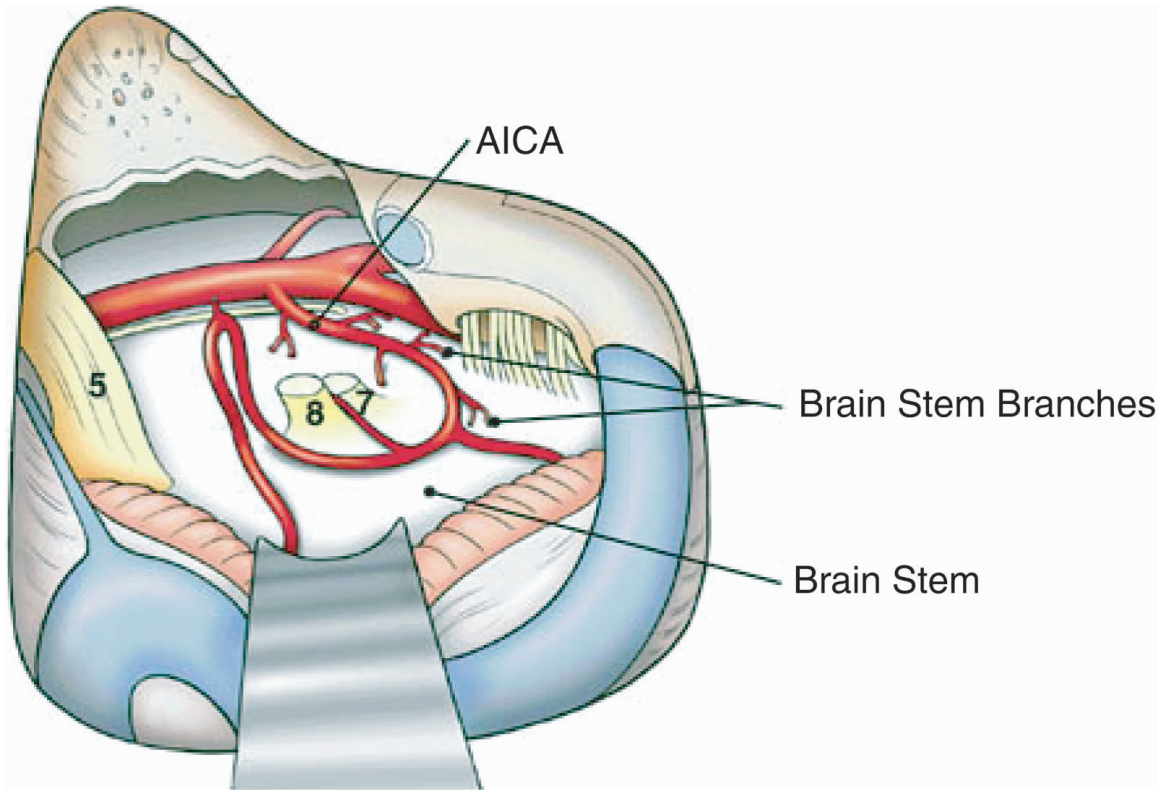


FIG. 5. Relationships of the two loops of the anterior inferior cerebellar artery encountered during surgery for acoustic neuroma. The first loop circumnavigates the root entry zones of the VIIth/VIIIth cranial nerve complex, and the second loop extends to and often enters the internal auditory canal.

patient with sudden sensorineural hearing loss and transient facial paralysis. They concluded that the clinical and radiographic findings were consistent with ischemia in the distribution of AICA (13).

Clinical manifestations of distal anterior inferior cerebellar artery syndrome

All 12 patients with MRI evidence for distal AICA vascular injury had cerebellar dysfunction. The most prominent symptom was dysmetria, which often resolved over months and without long-term (>1 yr) morbidity. Gait ataxia improved in roughly half the patients. By contrast, motor weakness, dysarthria, dysdiadochokinesia, and persistent gait dysfunction occurred in patients with multiple morbidities and persistent symptoms at 1 year.

Dysarthria and ataxia were often the result of flocculonodular lesions; dysmetria, motor weakness, terminal tremor, hypotonia (motor weakness), postural tremor, and dysdiadochokinesia all tended to localize to the cerebellar neocortex (14). Perioperative disruption of terminal AICA branches supplying the flocculus and the middle and superior cerebellar peduncles (Fig. 7) may account for all these symptoms. The clinical variation in postoperative morbidity may be related in part to superficial arterial anastomoses between the AICA and the long pontine arteries and known variations in the areal distribution of the AICA.

Radiographic features of distal anterior inferior cerebellar artery syndrome

The MRI signal appearance of brainstem ischemia evolves over the first 3 weeks after the initial insult (13). Postoperative MRI findings in the study population with persistent cerebellar dysfunction indicated a discrete, ischemic parenchymal lesion of the middle and superior cerebellar peduncles, extending from the lateral pial surface to the lateral wall of the fourth ventricle, which is the medial border of the peduncles. The volume of lateral to medial peduncular injury was variable, ranging from one third to full thickness.

Early postoperative MRI scans showed a discrete lesion of the peduncles. The signal characteristics of the infarction on T1 with gadolinium showed low or mixed (high/low) intensity, and T2 revealed high intensity. Late postoperative MRI scans showed a similar discrete lesion in the peduncles. Here, T1 with gadolinium had consistently high signal intensity. T2 signals were unchanged. Although several postoperative scans revealed encephalomalacia of the lateral third of the ipsilateral cerebellar hemisphere, this finding was often seen after retrosigmoid craniotomy and was usually of little clinical consequence. None of the MRI scans revealed pontine or medullary ischemia, although a small focal infarct in the territory of the vestibular nuclei beyond the resolution of MRI could not be entirely excluded. The radiographic

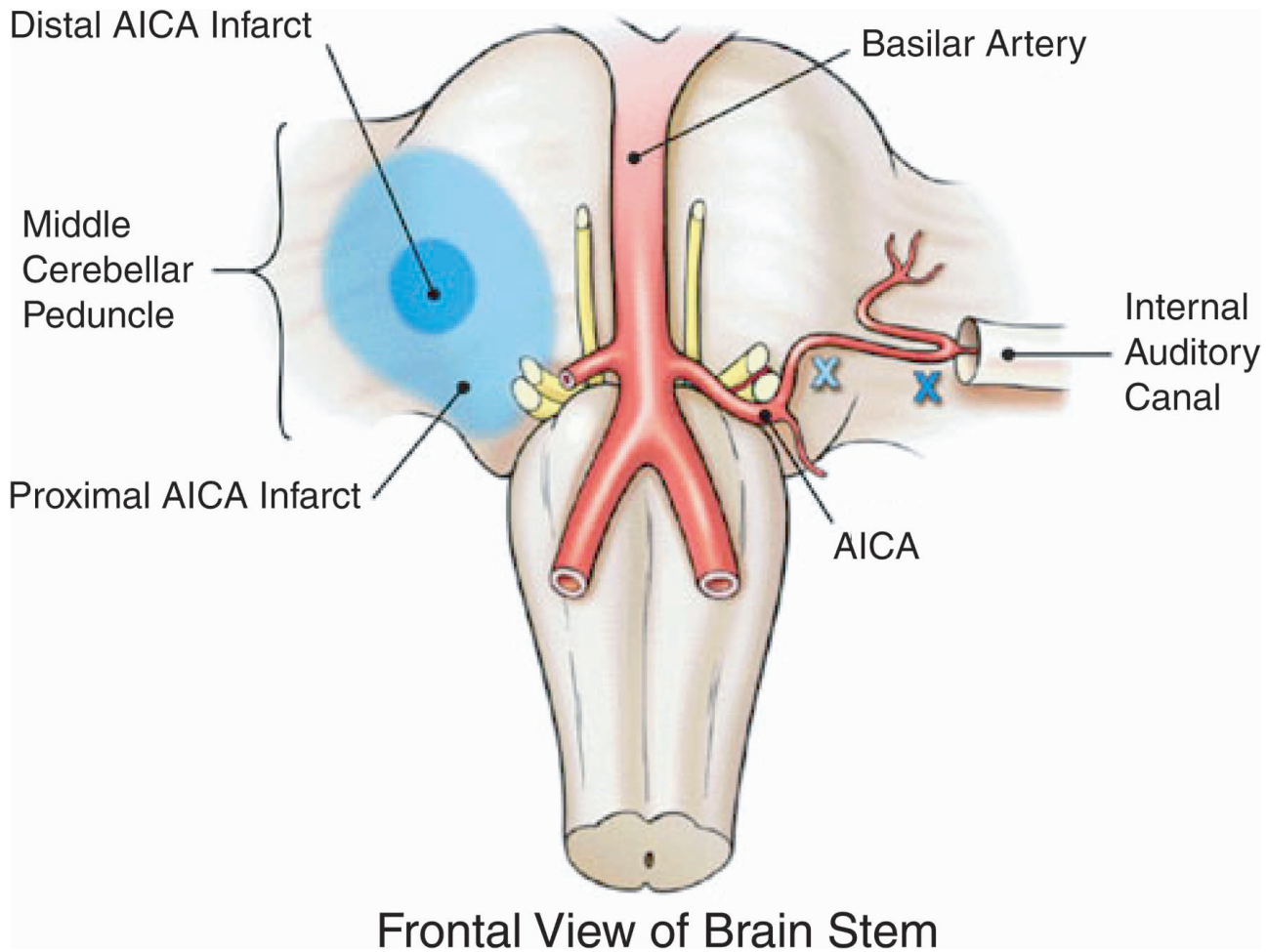


FIG. 6. The impact of injury to the anterior inferior cerebellar artery on neighboring cranial nerve nuclei, motor tracts, and sensory tracts.

findings were most consistent with a focal infarction in the middle and superior cerebellar peduncles.

Alternative explanations

Persistent cerebellar dysfunction after AN excision may occur, particularly after removal of large tumors. This has often been attributed to direct cerebellar injury resulting from brain retraction. Minimal retraction of the lateral cerebellum provides adequate exposure for the removal of even the largest ANs when the translabyrinthine approach is used. The postoperative scans shown in Figures 1 to 3 indicate a focal lesion well medial to the area of cerebellar retractor placement. It has long been known that injury to the lateral portion of a cerebellar hemisphere leads to little, or only transient, cerebellar dysfunction. Formerly, resection of the lateral one third of the cerebellum was common practice during AN surgery. Patients were reported to have minimal consequences from this exposure-enhancing maneuver. Successful compensation probably stems from new cerebellar learning (15,16). By contrast, injury to structures that provide afferent and efferent connections (e.g. cerebellar peduncles) or lie near the cerebellar midline

(e.g. dentate nuclei) is much more likely to result in lasting dysfunction with incomplete compensation. The likely cause remains arterial interruption rather than venous infarction, because even though small veins entering the tumor capsule often need to be cauterized and cut, abundant collaterals exist. ANs with large CPA components frequently derive some or all of their blood supply from superficial branches of the AICA. These branches often have a distal component that recurs to supply the end arteries of the cerebellum or brainstem. We propose that there is a small subset of patients with persistent vestibulocerebellar disability and characteristic MRI findings that result from disruption of these shared vessels at the time of surgery; main AICA blood flow is preserved.

Dissection techniques to avoid anterior inferior cerebellar artery branch injury

The arteries at greatest jeopardy are the AICA branches draped over the caudal portion of a large AN on the way to the middle and proximal superior cerebellar peduncles, or are enmeshed in arachnoid adhesions between a large tumor and adjacent peduncular surfaces. Injury to the draped branches most likely occurs when

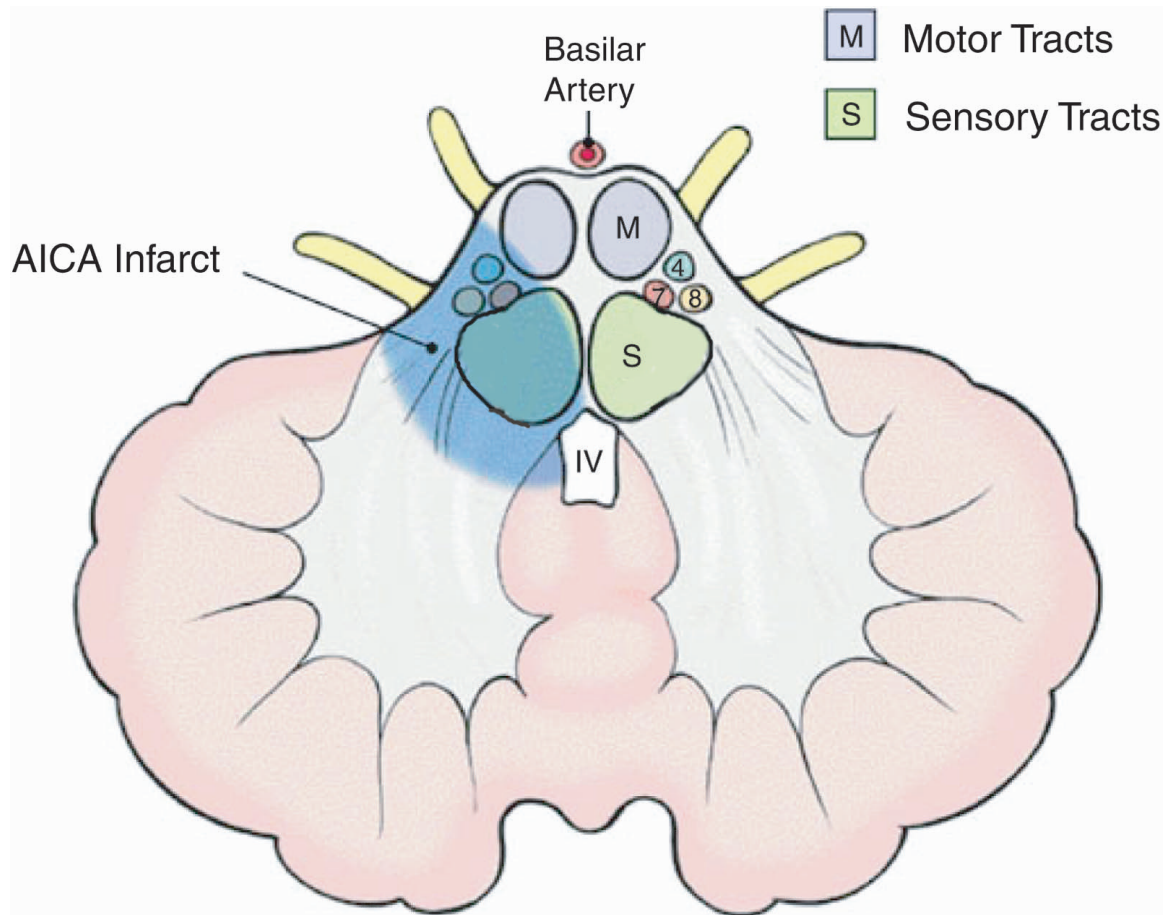


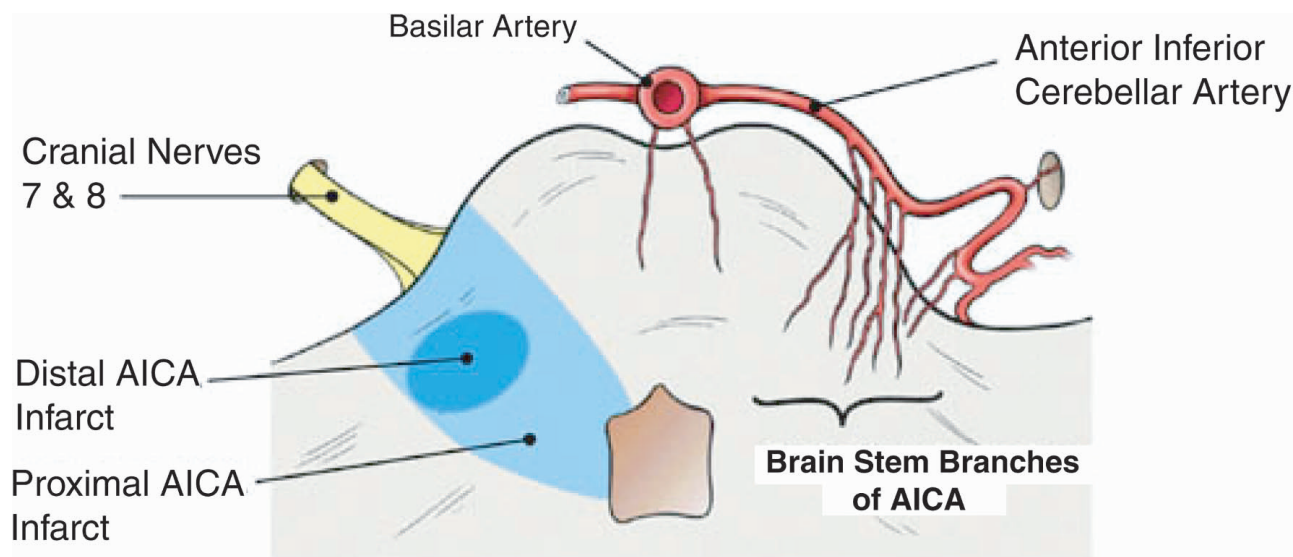
FIG. 7. Frontal view of the brainstem for comparing proximal versus distal anterior inferior cerebellar artery injury and the resultant area of peduncular ischemia.

the vessels are not readily visible, and they are cut as the caudal tumor capsule is opened to allow internal decompression of the tumor. This may be avoided by dissection of the arachnoid off and very careful inspection of the tumor surface for arteries before the tumor capsule is opened. It also may be helpful to dissect the tumor off the side of the peduncles at the caudal end of the tumor, carefully inspecting for and protecting vessels that seem to pass from the tumor surface onto the brain surface. In most instances, the vessel travels from the AICA proximally across the tumor surface and then passes onto the brain surface. Such vessels commonly can be dissected off the tumor surface and preserved. This careful caudal tumor-brain dissection also can identify those arterial branches that lie in the tumor-brain interface so that they can be separated from the tumor surface along the arachnoid planes and left to lie uninjured along the cerebellar peduncle surface. Tiny hairlike branches that supply the tumor from the traversing AICA branches can be cauterized and cut, facilitating separation and preservation of the traversing arteries. Because ANs are rarely very vascular, almost any artery that can be seen crossing the tumor surface likely goes on to supply the pons or the cerebellum, and the surgeon should make every attempt

to free those vessels from the tumor surface and preserve them. There is usually an arachnoid plane between these vessels and the AN, and once the tiny branches to the tumor are cauterized and cut, the crossing arteries can be usually dissected free. Very occasionally an AICA branch will lie in a shallow fold on the tumor surface and so seem to be “within” the tumor. Such a branch usually will have an arachnoid membrane around it and a cleft from the tumor surface, and it may be possible to remove the tumor from the vessel and thus preserve it. Although occlusion of these arteries does not always cause clinical damage, this may be caused by adequate collateralization on the brain surface, which is unknown a priori and cannot be relied upon to prevent infarction. Thus, attention to preserving these small arteries is very important, in our opinion.

CONCLUSIONS

In a series of 12 patients, the clinical and radiographic findings were consistent with cerebellar peduncular infarction or partial AICA syndrome after microsurgical removal of large ANs. The AICA and its tributaries are often displaced and stretched by tumors with significant CPA components. Although every effort is made to preserve all vessels, small perforating tributaries adherent to



Cross Section View of Brain Stem (from below)

FIG. 8. Cross-sectional view of the brainstem for comparing proximal versus distal anterior inferior cerebellar artery injury and the resultant area of peduncular ischemia. Interruption of the distal branches of the second loop of the anterior inferior cerebellar artery results in a much more focal infarction that typically does not extend to the fourth ventricle.

the tumor capsule may be disrupted during tumor removal. The middle and proximal portions of the superior cerebellar peduncles are supplied by one or more of these distal AICA tributaries and are at risk during AN surgery. Postoperative symptoms localized to the flocculonodular lobe and cerebellar neocortex, coupled with focal ischemic injury to the middle and superior cerebellar peduncles, can be explained by interruption of distal AICA tributaries.

The clinical course of these patients with distal AICA syndrome was significantly less morbid than historical reports of patients who had experienced the full AICA syndrome. The clinical course of the illustrative case (coma for 1.5 months, multiple persistent defects) contrasted with the significantly less morbid courses of cases 1 through 12. These cases highlight the importance of meticulous intraoperative preservation of vascular continuity when ANs are removed from the CPA, especially when these tumors are larger than 3 cm.

Patients with persistent cerebellar dysfunction after AN surgery should be evaluated with MRI. Patients with focal cerebellar peduncular infarction can be counseled that dysmetria without weakness is likely to improve over the first year. We postulate that interruption of distal branches of AICA is the cause of focal ischemia of the cerebellar peduncles and associated cerebellar dysfunction (Fig. 8).

REFERENCES

1. Rudge P. Vascular disease. In: *Clinical Neuro-otology*. Edinburgh, New York: Churchill Livingstone, 1983; 259–72.
2. Lang J. *Clinical Anatomy of the Posterior Cranial Fossa and its Foramina*. New York: Thieme Medical Publishers, 1991; 38–40.
3. Mazzoni A. Internal auditory canal arterial relations at the porus acusticus. *Ann Otol Rhinol Laryngol* 1969;78:797–814.
4. Amarenco P, Rosengart A, DeWitt LD, et al. Anterior inferior cerebellar artery territory infarcts: Mechanisms and clinical features. *Arch Neurol* 1993;50:154–61.
5. Amarenco P, Hauw JJ. Cerebellar infarction in the territory of the anterior and inferior cerebellar artery: A clinicopathological study of 20 cases. *Brain* 1990;113:139–55.
6. Carpenter M, Sutin J. Blood supply of the human nervous system. In: *Human Neuroanatomy*. 8th ed. Baltimore: Williams & Wilkins, 1983; 707–42.
7. Applebaum EL, Ferguson RJ. The latero-medial inferior pontine syndrome. *Ann Otol Rhinol Laryngol* 1975;84:379–83.
8. Perneczky A, Perneczky G, Tschabitscher M, et al. The relationship between the caudolateral pontine syndrome and the anterior inferior cerebellar artery. *Acta Neurochir* 1981;58:245–57.
9. Goodhart S, Davison C. Syndrome of the posterior inferior and anterior inferior cerebellar arteries and their branches. *Arch Neurol Psychiatry* 1936;35:501–24.
10. Adams R. Occlusion of the anterior inferior cerebellar artery. *Arch Neurol Psychiatry* 1943;49:765–70.
11. Atkinson W. The anterior inferior cerebellar artery: Its variations, pontine distribution, and significance in the surgery of the cerebello-pontine angle tumors. *J Neurol Neurosurg Psychiatry* 1949; 12:137–51.
12. Dandy W. An operation for the total removal of cerebellopontile (acoustic) tumors. *Surg Gynecol Obstet* 1925;41:129–48.
13. Biavati MJ, et al. Magnetic resonance imaging evidence of a focal pontine ischemia in sudden hearing loss and seventh nerve paralysis. *Am J Otol* 1994;15:250–3.
14. Miller D, Hahn JF. General methods of clinical examination. In: Youmans JR, ed. *Neurological Surgery*. 4th ed. Philadelphia: W. B. Saunders Company, 1996; 3–43.
15. Lisberger SG. Neural basis for motor learning in the vestibuloocular reflex of primates: III. Computational and behavioral analysis of the sites of learning. *J Neurophysiol* 1994;72:974–98.
16. Raymond JL, Lisberger SG, Mauk MD. The cerebellum: A neuronal learning machine? *Science* 1996;272:1126–31.