

# 'Moya-moya' Disease Caused by Cranial Trauma

Emilio Fernandez-Alvarez, MD, Mercedes Pineda, MD,  
Carlos Royo, MD, and Ramon Manzanares, MD

*A case of "moya-moya" disease of a 12-year-old boy is reported. The clinical history started at 3 years 2 months after cranial trauma. The patient developed mental retardation, hemiparesis and seizures.*

*Fernández-Alvarez E, Pineda M, Royo C, Manzanares R: "Moya-moya" disease caused by cranial trauma. Brain Dev 2:133-138, 1979*

"Moya-moya" disease [8, 9] is a cerebrovascular process characterized by stenosis or occlusion of the arteries of the circle of Willis with the development of collateral telangiectatic network involving principally the internal carotids, external carotids, ophthalmic artery, and leptomeningeal vessels.

One of the unanswered questions about moya-moya disease is its etiology [4]. We have observed a patient whose clinical and radiological characteristics are of moya-moya disease and that most probably was caused by cranial trauma. We think this case might help clarify the etiology of this syndrome.

## Case Report

The patient was a 12-year-old male admitted to the hospital of San Juan de Dios for observation of symptoms of convulsions and mental

retardation (Ref: 72,286). The parents, who are unrelated, denied the occurrence of related neurologic disorders in their families previously. The patient's 5-year-old sister showed slight mental retardation, but no signs of vascular anomalies were found when a carotid arteriography was done. The patient's two brothers, aged 14 and 7 years, were both of normal intelligence.

The patient weighed 3.2 kg at birth after a normal pregnancy and delivery. His psychomotor development was normal: he could hold up his head at 5 months, sit alone at 8 months and walk at 14 months.

At the age of 3 years 2 months, he was knocked down by a car and he hit his face on the curbstone of the pavement. He did not lose consciousness immediately, but he was hospitalized nevertheless. Three days later a convergent strabismus appeared in his right eye. The patient went into a coma in a few hours, and remained in this state for 24 hours, recovering slowly. Convulsions were not observed during this time. In the following weeks, aphasia and a right hemiparesis developed. The patient was able to eat without difficulty six weeks later.

The patient began physiotherapy at the age of four years. At that time his right Achilles tendon and right calf muscle were elongated due to spasticity. He suffered his first seizures

---

From the Departments of Pediatric Neurology (EF, MP, CR), Pediatric Radiology (RM), Hospital Infantil de San Juan de Dios, Barcelona.

Received for publication: August 6, 1979.

Accepted for publication: September 18, 1979.

**Key words:** *Moya-moya disease, multiple vascular occlusions, circle of Willis, head trauma, hemiparesis.*

Correspondence address: Dr. Emilio Fernández-Alvarez, Department of Pediatric Neurology, Hospital Infantil de San Juan de Dios, Servicio Neurología, Carretera de Esplugas s/n Barcelona-17, Spain.

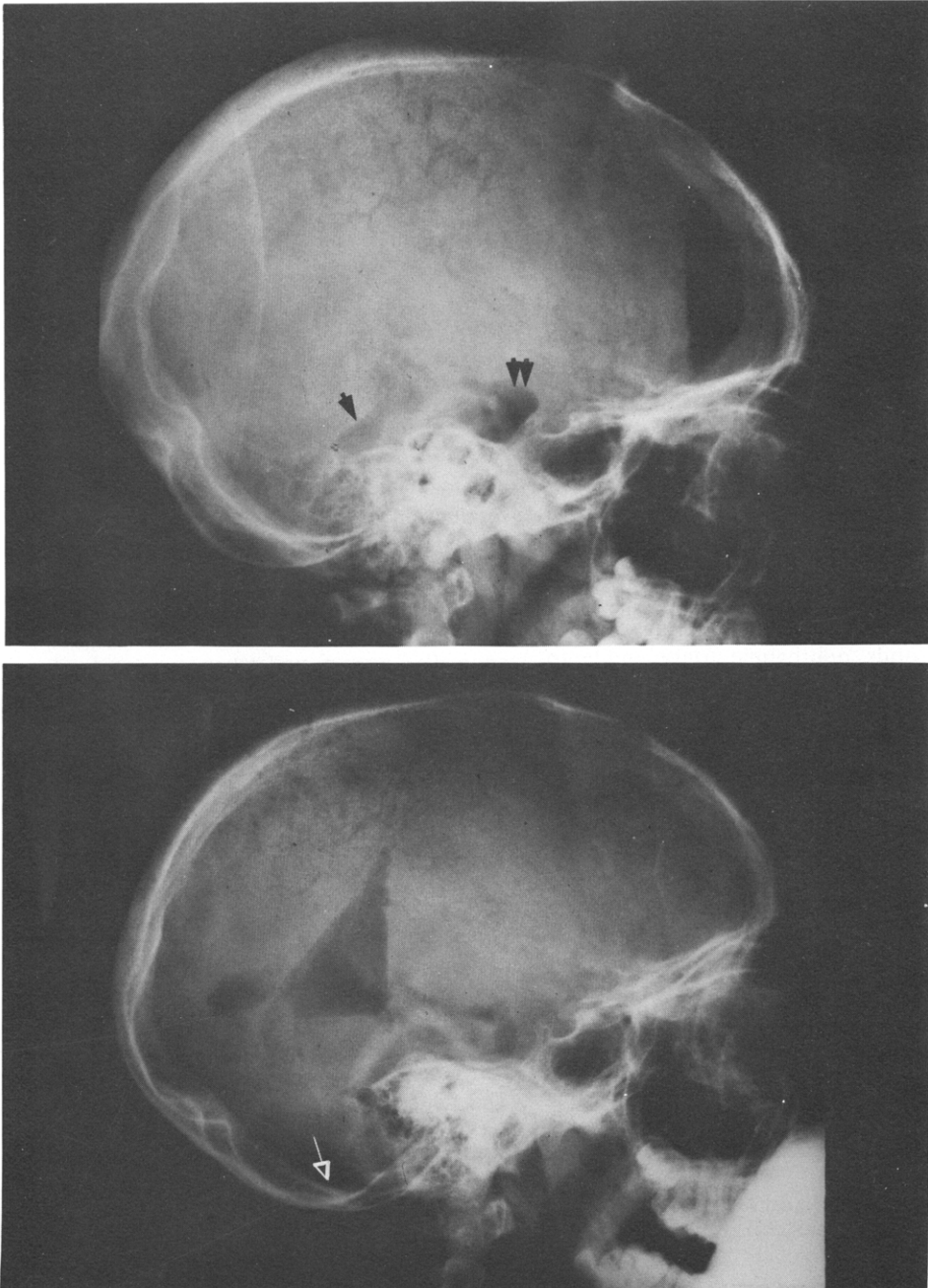


Fig 1 PEG: The fourth ventricle was slightly dilated (solid arrow). The magna (open arrow) and interpeduncularis (double solid arrows) cisterns were filled up with air but no air passed to the sub-arachnoid spaces of the convexity.

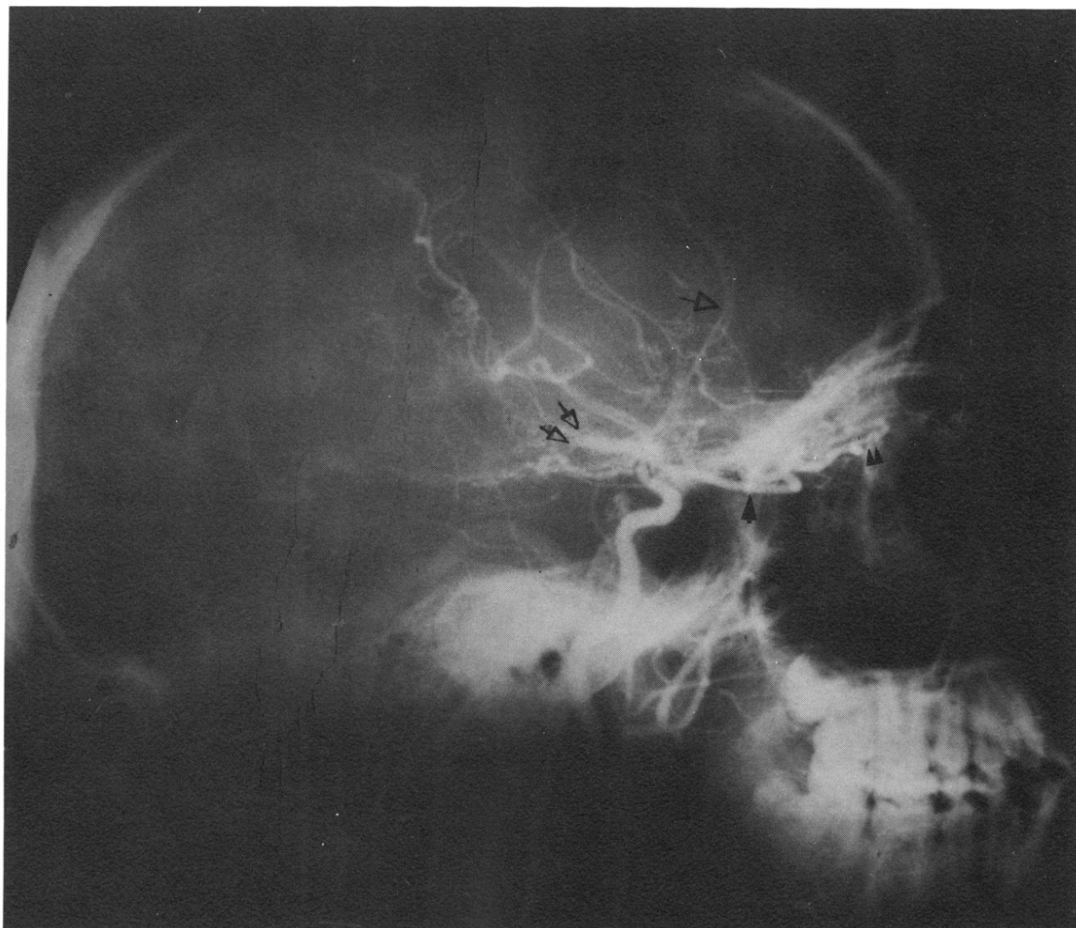

Fig 2 Right carotid angiography: Enlarged ophthalmic artery (solid arrow). Network of ethmoidal arteries (small solid arrowheads). Obstruction of anterior (open arrow) and middle (double open arrows) cerebral arteries.

at the age of four; it consisted of a right tonic-clonic hemiconvulsion with sphincter incontinence. Since then he has received uninterrupted treatment with phenobarbital, hydantoins, and diazepoxides. The seizures did not recur until the age of nine, but since then the patient has had right-sided tonic convulsions with oculoccephalic torsion to the right two or three times every month. The passage of years has produced mental retardation, and at the age of 11 the patient's IQ was 20 (Terman-Merrill test). The right hemiparesis has evolved unfavorably, the retractions and the spasticity continued to worsen, and growth in the right half of the body has been retarded.

### Clinical Examination

We first saw the patient when he was 12 years old. His head circumference was normal (54 cm). There were operation scars in the back of the calf and in the region of the Achilles tendon of the right foot, corresponding to the orthopedic operations. No abnormal pigmentation nor cardiac palpitations were detectable.

Physical examination revealed paresis of the VI right cranial nerve. Right spastic hemiparesis with the shoulder turned forward and retraction of the right major pectoralis muscle. The right arm was held in pronation and flexion. Hands clawed, and luxation of the thumb. The right leg showed popliteal retraction with the foot at right angle. The patient's right hand was

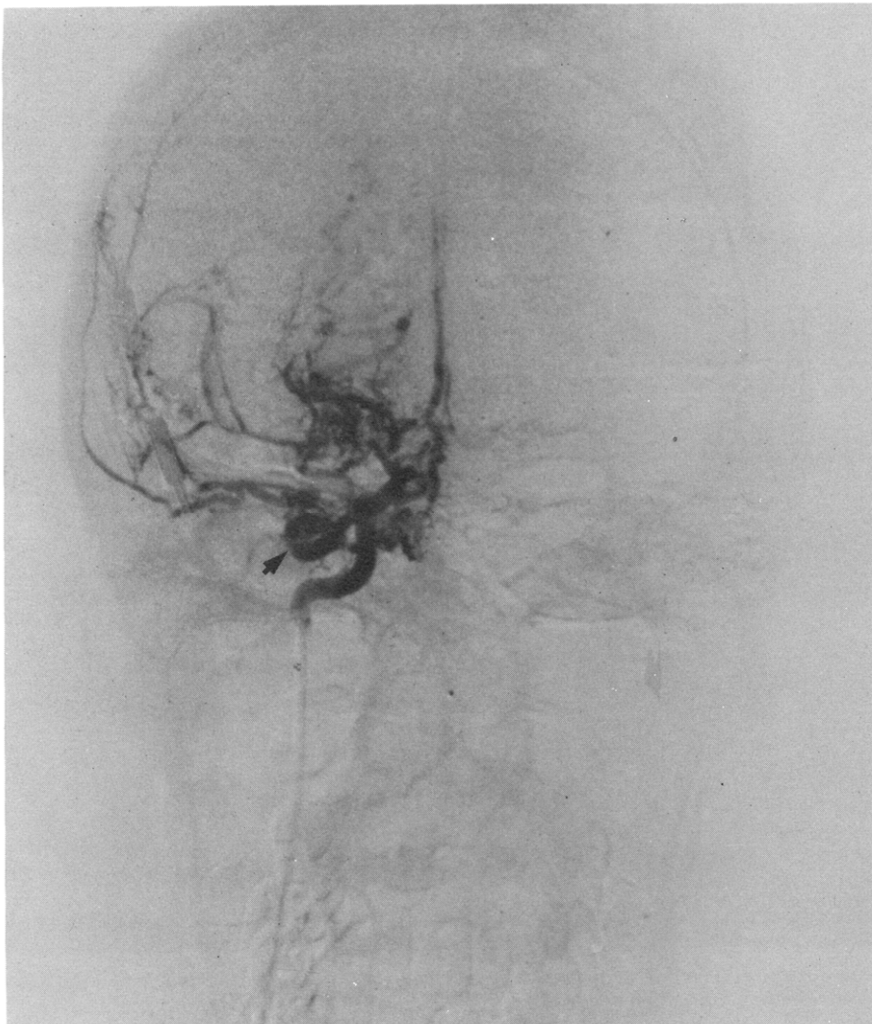


Fig 3 *Right carotid angiography: Shows enlarged ophthalmic artery (solid arrow).*

smaller than the left one. The right lower extremity was 0.7 cm shorter than the left, and the big toe was in a hammered position. There was right sided hyperreflexia. His vision was mal. His pupils were isocoric. Blood pressure was 110/80. The patient was able to understand only very simple instructions. He knew some vowels, was very sociable and of a very happy disposition. He was unable to control his sphincters.

He was admitted to the Hospital de San Juan de Dios for observation and study due to an increase in convulsions and spasticity and failure to progress intellectually.

#### **Laboratory Data**

Routine laboratory analysis was normal. Normal values were obtained for hemogram, WBC formula, coagulation tests, urine analysis, aminoacids, chest X-rays, and CSF (proteins: 13.5 mg%). EEG showed signs of marked disorganization in basic rhythms, but not significant focal activity was observed.

#### **Radiological Data**

Plain skull X-ray showed thickening of the calvaria, most marked on the left side. The left frontal sinus was larger than the right. Neither calcifications, digital markings nor abnormal grooves were seen.

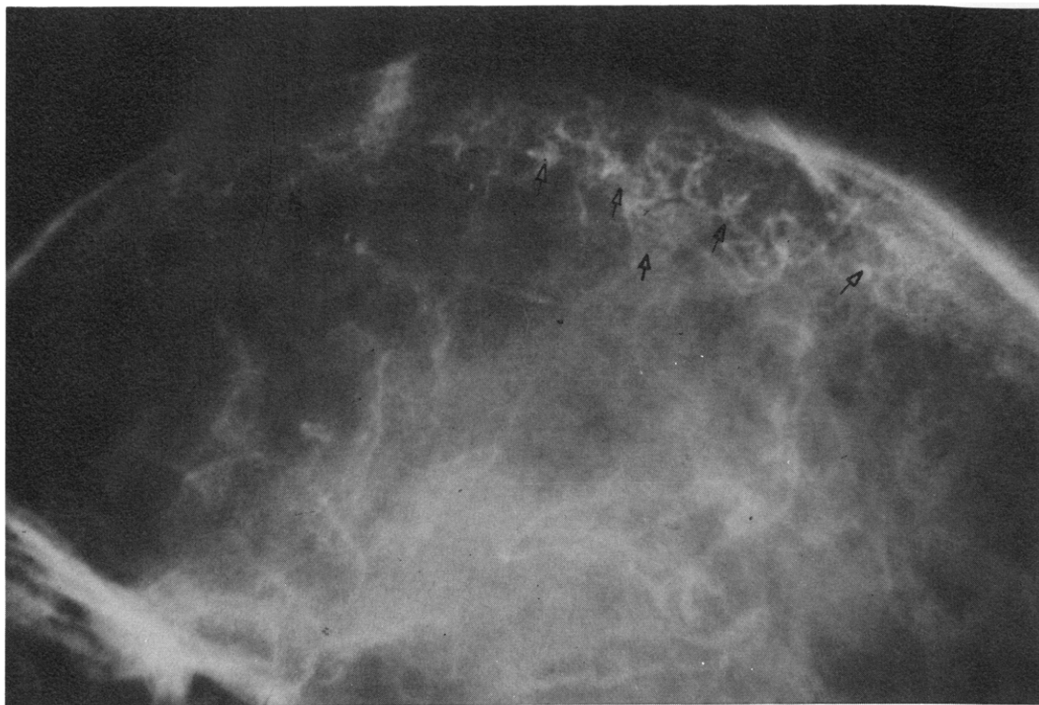


Fig 4 Left carotid angiography: Shows the "rete mirabile" of the anterior two thirds of the calvaria (open arrows).

Pneumoencephalography (Fig 1) showed a pronounced ventricular dilatation that was most severe in the frontal area where the distance from the frontal horn to the inner table was 11 mm. The distance between the occipital horn and the inner table was of 38 mm. The fourth ventricle was slightly dilated. The magna and interpeduncularis cisterns filled up with air but no air passed into the subarachnoid spaces of the convexity.

Bilateral carotid and vertebral angiography were performed (Figs 2 and 3). They rendered the following findings:

1. Both ophthalmic arteries were enlarged and feed a large network of ethmoidal arteries and the distal portion of the anterior cerebral artery.
2. The proximal portion of both anterior cerebral arteries was occluded and the distal portion filled through collateral circulation. The pericallosal arteries were thin and stretched around the dilated ventricles.
3. There was complete obstruction of both middle cerebral arteries with profuse local collaterals around the occluded vessels. The distal portion of the sylvian vessels seemed

to fill through the posterior cerebral arteries.

4. An important network of collateral vessels at the level of the basal ganglia and through the rete mirabile (Fig 4) of the anterior two thirds of the calvaria.

#### Comment

There is agreement that moyo-moya disease consists of a progressive arterial process in which the normal collateral circulation of the circle of Willis is obstructed and telangiectases arise as an atypical consequence of the arterial occlusion [6, 11]. However, the etiology of moyo-moya disease is unsettled. The causes seem to be manifold [4] and genetic factors may be evoked in familial cases [2, 5, 9, 10].

The occurrence of intracranial vascular occlusions after the head injury and the apparent relation between the trauma and the development of the symptoms in our patient strongly suggest that cranial trauma was the determining factor in this case. In spite of the fact that Suzuki and Takaku [10] reported head injury in three out of the 20 cases, we were able to find only another report of moyo-moya disease

ascribed to cranial trauma [7]. On the other hand, there are some reports of thrombosis of the cerebral arteries after cranial or cervical trauma [1, 3]. The report of Frantzen et al [3] is of special interest. They observed that cranial trauma in a child led to occlusion of the right middle cerebral artery one centimeter from the bifurcation of the internal carotid. Fifteen months later, as symptoms reappeared, another occlusion of the anterior cerebral artery appeared on the right side a few millimeters above the previous one. Their observations as well as ours suggest that non-penetrating cranial or cervical trauma in children may cause disorders in cerebral circulation. Thus, cranial trauma should be considered in the etiology of this type of disorder including moya-moya disease.

### Summary

A case report of a patient with a clinical history of hemiparesis, convulsions and mental retardation dating back to cranial trauma is presented. Angiography showed the characteristics of the so-called "moya-moya" disease in the patient. It is argued that cranial trauma could be an etiological factor in this disease.

### References

1. Duman S, Stephens JW: Post-traumatic middle cerebral artery occlusion. *Neurology* 13: 613, 1963.
2. Evrard P: Forme familiale du syndrome de sténose progressive des artères du cercle de Willis (moya-moya). Réunion de la Section Méditerranéenne du Groupement de Études Européen de Neurologie Infantile, Paris, 1971.
3. Frantzen E, Jacobsen HH, Therkelsen J: Central artery occlusions in children due to trauma to the head and neck. *Neurology* 11: 695, 1961.
4. Halonen H, Halonen V, Donner M, et al: Occlusive disease of intracranial main arteries with collateral networks in children. *Neuropædiatrie* 4: 187, 1973.
5. Hassan M, Levesques M: Le moyo-moya cérébral de l'enfant. *J Parisiennes de Pédiatrie*, p 335, 1973.
6. Hilal SK, Solomon GE, Gold AP, et al: Primary cerebral-arterial occlusive disease in children. *Radiology* 99: 71, 1971.
7. Isler W: Acute Hemiplegias and Hemisyndromes in Childhood. *William Heineman Med Books*, London, 1971, p 50.
8. Kudo T: Spontaneous occlusion of the circle of Willis. *Neurology (Minneapolis)* 18: 485, 1968.
9. Nishimoto A, Takeuchi S: Abnormal cerebrovascular network related to the internal carotid arteries. *J Neurosurg* 29: 225, 1968.
10. Suzuki J, Takaku A: Cerebrovascular "moya-moya" disease. *Arch Neurol* 20: 288, 1969.
11. Taveras JM: Multiple progressive intracranial occlusions. A syndrome of children and young adults. *AJR* 106: 235, 1969.