

Stroke and Pediatric Human Immunodeficiency Virus Infection

Case Report and Review of the Literature

Prithvi Narayan Owen B. Samuels Daniel L. Barrow

Emory University School of Medicine, Atlanta, Ga., USA

Key Words

Stroke · Cerebrovascular accidents · HIV · AIDS

Abstract

Stroke is an uncommon complication in pediatric patients with acquired immunodeficiency syndrome (AIDS). However, with the increasing life span of this patient population, more cases of stroke are being reported. We report the case of a 13-year-old girl with a known history of AIDS who presented with new-onset seizures and right hemiparesis. Serial imaging studies revealed progressive occlusion of the left middle cerebral artery and both anterior cerebral arteries with development of collateral circulation. The workup for other etiologies of stroke was negative. This nonatherosclerotic occlusive disease is most likely secondary to vasculopathy caused by the human immunodeficiency virus (HIV). HIV infection should be included in the differential diagnosis of children who present with seizures, mental status change or focal neurological deficits. Treatment options are limited. The different prognoses associated with the etiologies of stroke in this patient population mandate a careful and thorough evaluation.

Copyright © 2002 S. Karger AG, Basel

Introduction

As the life expectancy of children infected with the human immunodeficiency virus (HIV) increases, various patterns of neurological dysfunction are being reported [1–4]. Central nervous system (CNS) involvement may be due to acquired immunodeficiency syndrome (AIDS) or HIV-related encephalopathy or secondary to complications related to the immunodeficiency. The latter category includes CNS infections, CNS neoplasms and strokes. Ischemic or hemorrhagic stroke is a well-recognized complication of HIV infection in adults [5, 6] but is an uncommon occurrence in children. This report describes the case of a 13-year-old child with AIDS who suffered a stroke. The etiology of strokes in this group of patients is discussed along with a review of the pertinent literature.

Case Report

A 13-year-old girl with a known history of AIDS and a low CD-4 count presented with new onset of partial complex seizures. On examination, the patient was awake, alert and dysphasic, with a right facial palsy and right hemiparesis. There were brisk deep tendon reflexes and an extensor plantar response on the right. A computed tomography (CT) scan of the head revealed subacute hemorrhage involving the left basal ganglia (fig. 1a) and edema of the left tempo-

KARGER

Fax +41 61 306 12 34
E-Mail karger@karger.ch
www.karger.com

© 2002 S. Karger AG, Basel
1016-2291/02/0373-0158\$18.50/0

Accessible online at:
www.karger.com/journals/pne

Daniel L. Barrow, MD, Chairman
Department of Neurological Surgery
Emory University School of Medicine
1365-B Clifton Road, NE, Ste. 6400, Atlanta, GA 30322 (USA)
Tel. +1 404 778 5770, Fax +1 404 778 4472, E-Mail daniel_barrow@emoryhealthcare.org

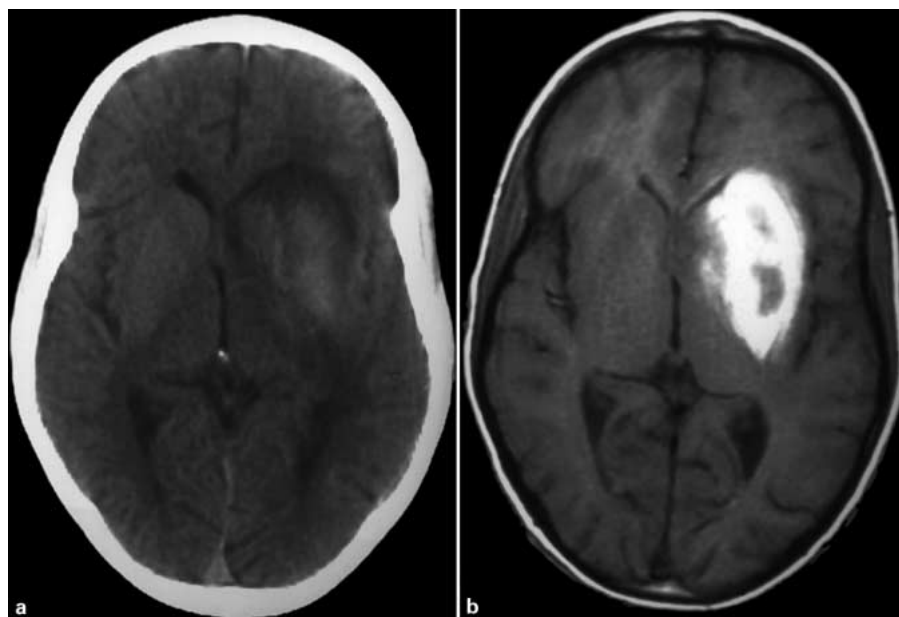


Fig. 1. CT of the head (a) and axial T1-weighted MRI of the brain (b) showing a lesion in the left basal ganglia most likely representing a subacute hemorrhage.

ral lobe (not shown). Magnetic resonance imaging (MRI) of the brain confirmed the findings on the head CT but was negative for other structural lesions (fig. 1b). A 4-vessel cerebral angiogram showed a complete occlusion of the left middle cerebral artery (MCA) with fusiform dilatation of the left internal carotid artery proximal to the ophthalmic artery and extending into the left A1 segment (fig. 2). There was retrograde filling of some of the larger branches of the distal Sylvian region of the MCA. The laboratory and clinical workup revealed no evidence of acute infection or coagulopathy. The patient had an uneventful hospital course. At the time of discharge, her right hemiparesis had improved and the patient was ambulating with a cane. The patient presented 2 weeks after discharge with sudden worsening of her right hemiparesis. An MRI and magnetic resonance angiography (MRA) of the brain were obtained and showed a new large left frontal lobe nonhemorrhagic infarction with occlusion of both anterior cerebral arteries (ACAs) (fig. 3). The patient's condition remained stable for the remainder of the hospital stay.

Discussion

Stroke is a complication of HIV infection in approximately 1% of affected children [7] and can be the initial presentation of HIV infection in some cases [8]. Autopsy studies have documented a cerebral infarction in 10–30% of children with HIV or AIDS [4]. Due to the lack of well-designed case-control studies, the association between stroke and HIV infection is unclear [9]. To address this issue, Qureshi et al. [10] conducted a retrospective review of 236 adult patients with stroke. Among patients with stroke, cerebral infarction was more common in HIV-positive patients than in HIV-negative patients (80 vs. 56%,

$p = 0.04$). Their findings suggest an increased risk of stroke associated with HIV infection [10].

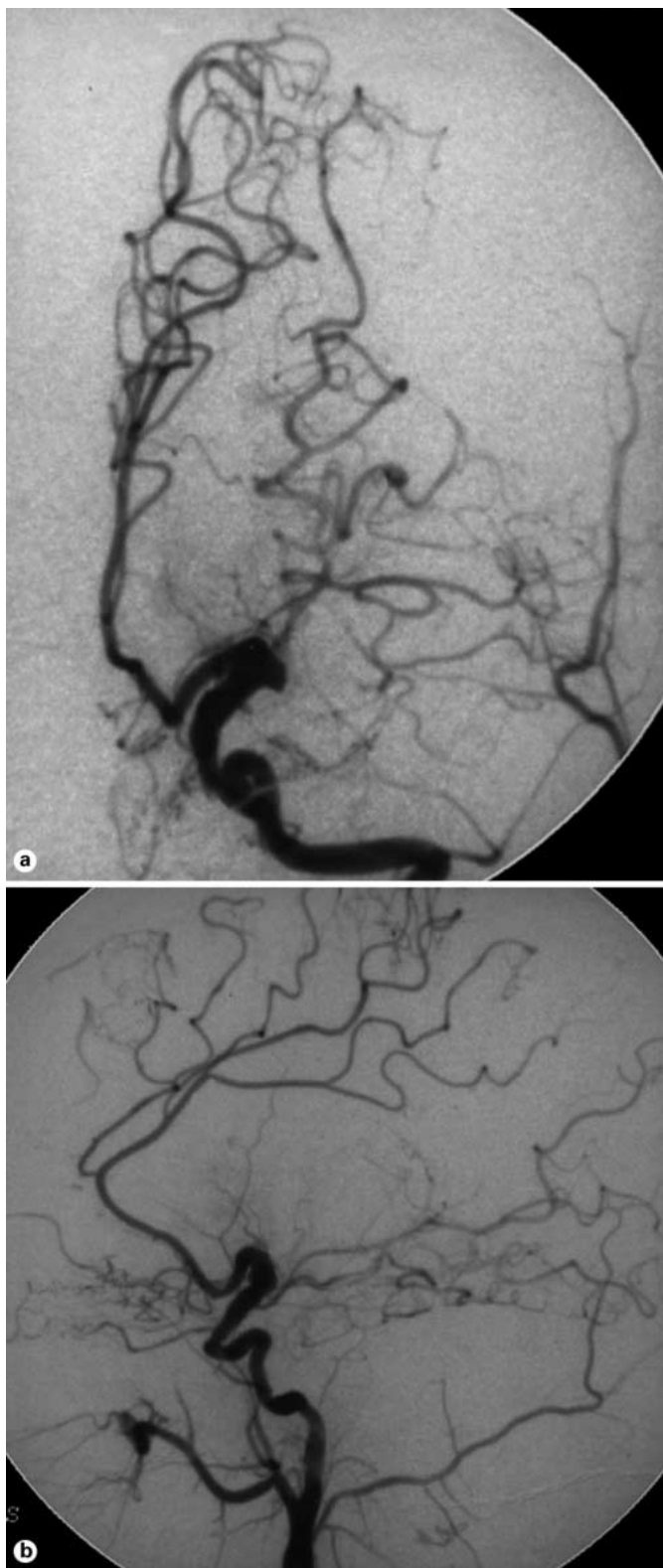The major causes of stroke in HIV-infected patients include cardioembolism, infection, coagulopathy, thrombocytopenia and vasculitis. However, the etiology is unknown in a number of cases, and a vasculopathy of some form has been implicated [4, 11]. Table 1 summarizes the characteristics of stroke in HIV-infected children reported in the literature.

Cardiac disease is commonly associated with cerebral embolism. This may include rheumatic heart disease, prosthetic heart valve, bacterial endocarditis, atrial myxoma and myocarditis [12].

Opportunistic infections can cause vasculopathy and subsequently lead to cerebral infarction [7, 13]. Pathogens that have a propensity for angioinvasion and secondary thrombosis of the infected vessels include *Candida albicans*, cytomegalovirus and varicella-zoster virus. Opportunistic infections of the CNS are less common in children compared to adults [14].

Fulmer et al. [13] reported two cases of fusiform cerebral aneurysms in HIV-positive children and the first reported case of an aneurysm associated with varicella-zoster vasculitis.

Lymphoma is a known neoplastic cause of vasculopathy in AIDS patients. The tumor can invade blood vessels, causing vascular injury and occlusion [7]. As with opportunistic infections, primary CNS lymphoma is unusual in children.



A number of coagulopathies have been associated with HIV infection. Thrombocytopenia can follow HIV seroconversion, resulting in intracranial hemorrhage [15]. During the course of AIDS, thrombocytopenia may result from thrombotic thrombocytopenic purpura or disseminated intravascular coagulation [16]. Hemorrhagic infarcts are reported to be less frequent than nonhemorrhagic infarcts, but when they do occur, it is usually in association with thrombocytopenia [4]. Other mechanisms of coagulopathy that may be associated with HIV infection include increased susceptibility to protein S deficiency [10] and antiphospholipid antibodies, including anticardiolipin antibodies [17].

In the absence of an identifiable cause of stroke, vasculitis may be an important etiology for cerebral infarction in AIDS patients [2, 3, 11, 18]. Different types have been described in the literature, including eosinophilic vasculitis, granulomatous angiitis and necrotizing vasculitis [19–21]. Other mechanisms may also be responsible for this association. Increased deposition of circulating immune complexes is known to occur frequently in AIDS [11, 22, 23]. In addition, HIV may indirectly mediate vascular injury by the reaction of elastases from repeated infections, leading to disruption of the elastic lamina [24]. Another possible mechanism is the toxic effect of the HIV on vascular endothelium. Philippet et al. [2] found dilation and thrombosis of major cerebral arteries in two children with HIV infection resembling a vasculitis. Supporting this hypothesis, a major HIV transmembrane glycoprotein, gp41, has been found in the walls of such aneurysmal arteries of the circle of Willis [4, 25], but others have failed to detect gp41 in similar lesions [26].

Finally, other unusual causes of strokes not directly associated with HIV infection, such as sickle cell disease, moyamoya disease or syndrome, homocystinuria and mitochondrial cytopathies such as mitochondrial encephalopathy, lactic acidosis and stroke-like episodes, should be included in the differential diagnosis.

Fig. 2. Anterior-posterior (a) and lateral (b) angiogram with left common carotid injection, showing complete occlusion of the left MCA and dilatation of the left internal carotid artery just proximal to the origin of the ophthalmic artery extending to the proximal left ACA. Note the collateral flow with some hypertrophied small vessels fed by the distal ACA and the posterior cerebral artery via the posterior communicating artery.

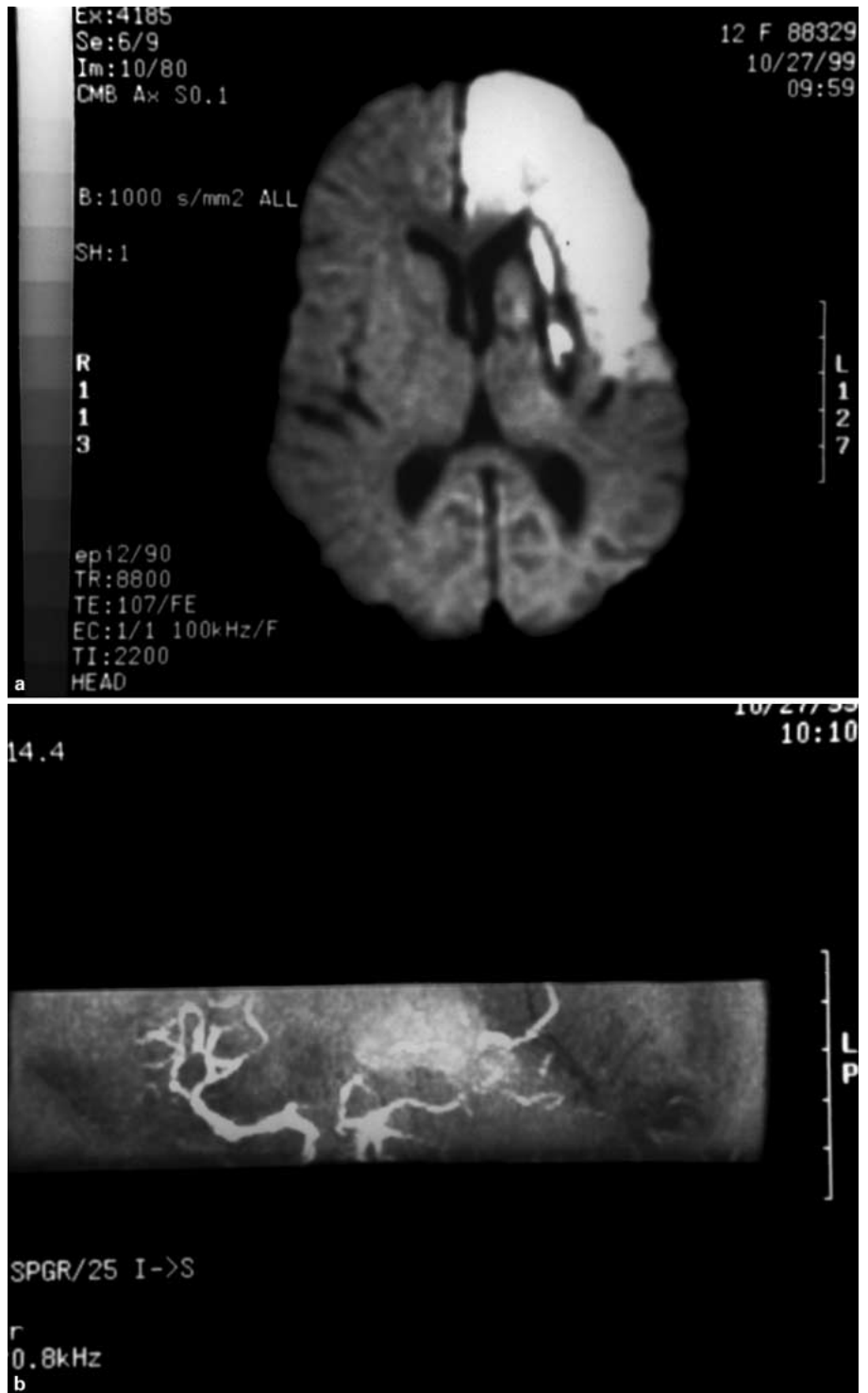

Fig. 3. Diffusion-weighted MRI (a) and MRA (b) obtained 3 weeks after the initial angiogram showing a new large left frontal lobe infarction and occlusion of both ACAs not present on the initial angiogram.

Table 1. Review of the literature: HIV infection and stroke in pediatric patients

Author	Year	Type of study	Cases	Type of stroke	Imaging/pathological characteristics	Presumptive etiology	Comments
Cho et al. [28]	1987	autopsy study	4	CI (4)	intimal proliferation of leptomeningeal vessels (4) HIV encephalitis (3)	HIV (4)	two adults included in this report
Frank et al. [30]	1989	case report	1	CI (1)	aneurysmal dilatation and vascular thickening (1)	VZV, HIV (1)	-
Park et al. [4]	1990	case series	7	CI (5) ICH (1)	aneurysmal dilatation (1) arteriopathy (1) SNE (2)	HIV (4) VZV, HIV (1) lymphoma, IT, HIV (1) IT, HIV (1)	all ICH in patients with immune thrombocytopenia; 2 children with cardiomyopathy and SNE
Kugler et al. [29]	1991	case report	1	CI (1)	cortical gyral enhancement and basal ganglia calcifications on CT, SPECT abnormalities (1)	HIV (1)	-
Philippot et al. [2]	1994	case series	4	CI (4) ICH (1)	aneurysmal dilatation and thrombosis (2) thrombosis (1) focal necrosis (1)	HIV (4)	history of frequent infections in the 2 patients with aneurysmal dilatation and thrombosis
Moriarty et al. [3]	1994	case series	3	CI (3)	thrombosis (1)	HIV (3)	-
Fulmer et al. [30]	1998	case series	2	CI (1) SAH (1)	aneurysmal dilatation (2)	HIV (1) VZV, HIV (1)	-
Visudtibhan et al. [8]	1999	case series	2	CI (1) ICH (1)	Arterial narrowing (2)	HIV (2)	Stroke and seizure were initial presentation of HIV infection
Present study	2002	case report	1	ICH (1)	aneurysmal dilatation and thrombosis (1)	HIV (1)	-

Number in parentheses represent the number of cases. CI = Cerebral infarction; ICH = intracerebral hemorrhage; SAH = subarachnoid hemorrhage; SNE = subacute necrotizing encephalopathy; VZV = varicella-zoster virus; IT = immune thrombocytopenia; SPECT = single-photon emission computed tomography.

HIV-positive patients presenting with a stroke should undergo an exhaustive workup including tests to rule out cardiac, infectious or immunological etiologies and coagulopathy. A cerebral angiogram or MRA may be indicated if there is evidence of an infarction or hemorrhage on CT or MRI. Regional cerebral blood flow techniques may be useful to demonstrate appropriate reduction in cerebral blood flow and reduction of cerebrovascular reserve with acetazolamide challenge to identify candidates for a bypass procedure.

The effectiveness of medical therapy such as corticosteroids, vasodilators, low-molecular-weight dextran, antiplatelet agents and anticoagulants in the setting of HIV-associated vasculopathy is unproven. Also, the use of neuroprotective agents such as adenosine in the treatment of stroke has been questioned [27]. Patients with angiographically proven moyamoya-like patterns refractory to medical therapy may benefit from bypass procedures.

The patient in this report had a known history of AIDS and presented with new-onset seizures and hemiparesis. Imaging studies confirmed cerebral infarctions in the anterior cerebral artery (ACA) and MCA distribution. The angiographic characteristics at the circle of Willis sug-

gested an occlusive vasculopathy with development of moyamoya-like collateral vessels. There was no clinical or radiological evidence of infection, CNS malignancy or vascular malformations. The workup for other causes of stroke such as coagulopathy, hypercoagulable states or sources of cardio-emboli were negative. Therefore, a proposed or suspected etiology of this chronic, progressive, nonatherosclerotic occlusive process is an HIV-associated vasculopathy. Treatment options in this case are limited. The presence of hemorrhage precludes the use of anticoagulation or an urgent bypass procedure. The progressive nature of this process portends a poor prognosis.

References

- 1 Belman AL: Acquired immunodeficiency syndrome and the child's central nervous system. *Pediatr Clin North Am* 1992;39:691-714.
- 2 Philippet P, Blanche S, Sebag G, Rodesch G, Griscelli C, Tardieu M: Stroke and cerebral infarcts in children infected with human immunodeficiency virus. *Arch Pediatr Adolesc Med* 1994;148:965-970.
- 3 Moriarty DM, Haller JO, Loh JP, Fikrig S: Cerebral infarction in pediatric acquired immunodeficiency syndrome. *Pediatr Radiol* 1994;24:611-612.
- 4 Park YD, Belman AL, Kim TS, Kure K, Llana JF, Lantos G, Bernstein L, Dickson DW: Stroke in pediatric acquired immunodeficiency syndrome. *Ann Neurol* 1990;28:303-311.
- 5 Anders KH, Guerra WF, Tomiyasu U, Verity MA, Vinters HV: The neuropathology of AIDS. UCLA experience and review. *Am J Pathol* 1986;124:537-556.
- 6 Snider WD, Simpson DM, Nielsen S, Gold JW, Metroka CE, Posner JB: Neurological complications of acquired immune deficiency syndrome: Analysis of 50 patients. *Ann Neurol* 1983;14:403-418.
- 7 Kiebertz KD, Eskin TA: Opportunistic cerebral vasculopathy and stroke in patients with the acquired immunodeficiency syndrome. *Arch Neurol* 1993;50:430-432.
- 8 Visudtibhan A, Visudhiphan P, Chiemchanya S: Stroke and seizures as the presenting signs of pediatric HIV infection. *Pediatr Neurol* 1999; 2:588-592.
- 9 Pinto AN: AIDS and cerebrovascular disease. *Stroke* 1996;27:538-543.
- 10 Qureshi AI, Janssen RS, Karon JM, Weissman JP, Akbar MS, Safdar K, Frankel MR: Human immunodeficiency virus infection and stroke in young patients. *Arch Neurol* 1997;54:1150-1153.
- 11 Engstrom JW, Lowenstein DH, Bredesen DE: Cerebral infarctions and transient neurological deficits associated with acquired immunodeficiency syndrome. *Am J Med* 1989;86:528-532.
- 12 Riela AR, Roach ES: Etiology of stroke in children. *J Child Neurol* 1993;8:201-220.
- 13 Fulmer BB, Dillard SC, Musulman EM, Palmer CA, Oakes J: Two cases of cerebral aneurysms in HIV+ children. *Pediatr Neurosurg* 1998;28:31-34.
- 14 Belman AL, Diamond G, Dickson D, Horoupian D, Llana J, Lantos G, Rubinstein A: Pediatric acquired immunodeficiency syndrome. Neurologic syndromes. *Am J Dis Child* 1988;142:29-35.
- 15 Ratner L: Human immunodeficiency virus-associated autoimmune thrombocytopenic purpura: A review. *Am J Med* 1989;86:194-198.
- 16 Leaf AN, Laubenstein LJ, Raphael B, Hochster H, Baez L, Karpatkin S: Thrombotic thrombocytopenic purpura associated with human immunodeficiency virus type 1 (HIV-1) infection. *Ann Intern Med* 1988;109:194-197.
- 17 Gold JE, Haubenstoc A, Zalusky R: Lupus anticoagulant and AIDS. *N Engl J Med* 1986; 314:1252-1253.
- 18 Levy RM, Bredesen DE: Central nervous system dysfunction in acquired immunodeficiency syndrome. *J Acquir Immune Defic Syndr* 1988;1:41-64.
- 19 Vinters HV, Guerra WF, Eppolito L, Keith PE 3rd: Necrotizing vasculitis of the nervous system in a patient with AIDS-related complex. *Neuropathol Appl Neurobiol* 1988;14:417-424.
- 20 Schwartz ND, So YT, Hollander H, Allen S, Fye KH: Eosinophilic vasculitis leading to amaurosis fugax in a patient with acquired immunodeficiency syndrome. *Arch Intern Med* 1986;146:2059-2060.
- 21 Yankner BA, Skolnik PR, Shoukimas GM, Gabuzda DH, Sobel RA, Ho DD: Cerebral granulomatous angiitis associated with isolation of human T-lymphotropic virus type III from the central nervous system. *Ann Neurol* 1986;20: 362-264.
- 22 Schuman JS, Orellana J, Friedman AH, Teich SA: Acquired immunodeficiency syndrome (AIDS). *Surv Ophthalmol* 1987;31:384-410.
- 23 Newsome DA, Green WR, Miller ED, Kiessling LA, Morgan B, Jabs DA, Polk BF: Microvascular aspects of acquired immunodeficiency syndrome retinopathy. *Am J Ophthalmol* 1984;98:590-601.
- 24 Joshi VV, Pawel B, Connor E, Sharer L, Oleske JM, Morrison S, Marin-Garcia J: Arteriopathy in children with acquired immune deficiency syndrome. *Pediatr Pathol* 1987;7:261-275.
- 25 Kure K, Park Y, Kim T, Lyman WD, Lantos G, Lee S, Cho S, Belman AL, Weidenheim KM, Dickson DW: Immunohistochemical localization of an HIV epitope in cerebral aneurysmal arteriopathy in pediatric acquired immunodeficiency syndrome (AIDS). *Pediatr Pathol* 1989;9:655-667.
- 26 Lang C, Jacobi G, Kreuz W, Hacker H, Herrmann G, Keul HG, Thomas E: Rapid development of giant aneurysm at the base of the brain in an 8-year-old boy with perinatal HIV infection. *Acta Histochem Suppl* 1992;42:83-90.
- 27 von Lubitz DK: Adenosine in the treatment of stroke: Yes, maybe, or absolutely not? *Expert Opin Investig Drugs* 2001;10:619-632.
- 28 Cho ES, Sharer LR, Peress NS, Little B: Intimal proliferation of leptomeningeal arteries and brain infarcts in subjects with AIDS (abstract). *J Neuropathol Exp Neurol* 1987;46:385.
- 29 Kugler SL, Barzilai A, Hodes DS, Stollman A, Kim CK, Hyatt AC, Aron AM: Acute hemiplegia associated with HIV infection. *Pediatr Neurol* 1991;7:207-210.
- 30 Frank Y, Lim W, Kahn E, Farmer P, Gorey M, Pahwa S: Multiple ischemic infarcts in a child with AIDS, varicella zoster infection, and cerebral vasculitis. *Pediatr Neurol* 1989;5:64-67.

Copyright: S. Karger AG, Basel 2002. Reproduced with the permission of S. Karger AG, Basel. Further reproduction or distribution (electronic or otherwise) is prohibited without permission from the copyright holder.

Copyright: S. Karger AG, Basel 2002. Reproduced with the permission of S. Karger AG, Basel. Further reproduction or distribution (electronic or otherwise) is prohibited without permission from the copyright holder.