

Mary Murphy
Joan P. Grieve
Simon R. Stapleton

Presentation of a choroid plexus papilloma mimicking an extradural haematoma after a head injury

Received: 16 April 2002
Revised: 27 May 2002
Published online: 26 July 2002
© Springer-Verlag 2002

M. Murphy (✉) · J.P. Grieve
S.R. Stapleton
Department of Neurosurgery,
Atkinson Morley's Hospital, Copse Hill,
Wimbledon, London, SW20 0NE, UK
e-mail: mmmurphy@sghms.ac.uk
Tel.: +44-20-87254175
Fax: +44-20-89478389

Abstract *Introduction:* Choroid plexus papillomas are rare, benign tumours of childhood. They usually present with subacute symptoms of raised intracranial pressure (ICP) commonly due to overproduction of CSF. Less common presentations include focal neurological deficits and epilepsy. *Case report:* This is the first reported case of any intracranial tumour mimicking a traumatic extradural haematoma in presentation.

Keywords Choroid plexus papilloma · Extradural haematoma · Head injury · Trauma · Presentation

Introduction

Choroid plexus tumours are rare tumours of childhood and are usually benign [10, 11]. They often present with symptoms of hydrocephalus, although some more unusual presentations are reported in the literature [6, 8, 14, 15]. We describe the first presentation of a choroid plexus papilloma of the lateral ventricle mimicking a head injury.

Case report

A previously well 4-year-old girl presented with a depressed conscious level and a history suggestive of an extradural haematoma. She had experienced a head injury without loss of consciousness after running into a wall in the school playground during games. She continued playing and appeared completely normal until 1 h later when she started to vomit and became drowsy in the classroom. Her conscious level declined and at the district hospital she was localising and eye-opening to pain and making incomprehensible sounds. The CT scanner at the local hospital was under repair so she was accepted at the regional neurosurgical centre.

She was intubated, ventilated and sedated when she arrived at the neurosurgical unit. Her pupils were equal and reactive but constantly changing in size and shape. Systemic examination was normal. A cranial CT scan with and without contrast failed to demonstrate any evidence of trauma but did reveal a small irregular, en-

hancing mass in the region of the left foramen of Monro, suggestive of a small choroid plexus papilloma with concomitant asymmetrical hydrocephalus. The sedation was removed and the patient's best motor response was localising. Therefore, a left frontal external ventricular drain was inserted. The CSF pressure was low and its composition was normal. An MRI scan further characterised the lesion (Fig. 1).

Her conscious level fluctuated until a craniotomy was performed 2 days later. A frontal interhemispheric approach was used and the lesion was excised transcallosally. At operation the papilloma had a pedicle from the lateral ventricular choroid plexus extending as a free frond, which had prolapsed through the foramen of Monro and was wedged into the third ventricle. Histopathology confirmed the diagnosis of choroid plexus papilloma. After the craniotomy she made a complete neurological recovery and was discharged 5 days post-operatively.

Discussion

Tumours of the third ventricle, in particular colloid cysts, have a reputation for causing sudden death [1, 2, 3, 4, 5, 7, 9, 12, 13, 16, 17] or coma [4] secondary to a "ballcock" effect when the lesion impacts at either foramen of Monro, causing a sudden surge in intracranial pressure (ICP). This phenomenon has never previously been reported in the literature in association with a lesion originating in the lateral ventricle.

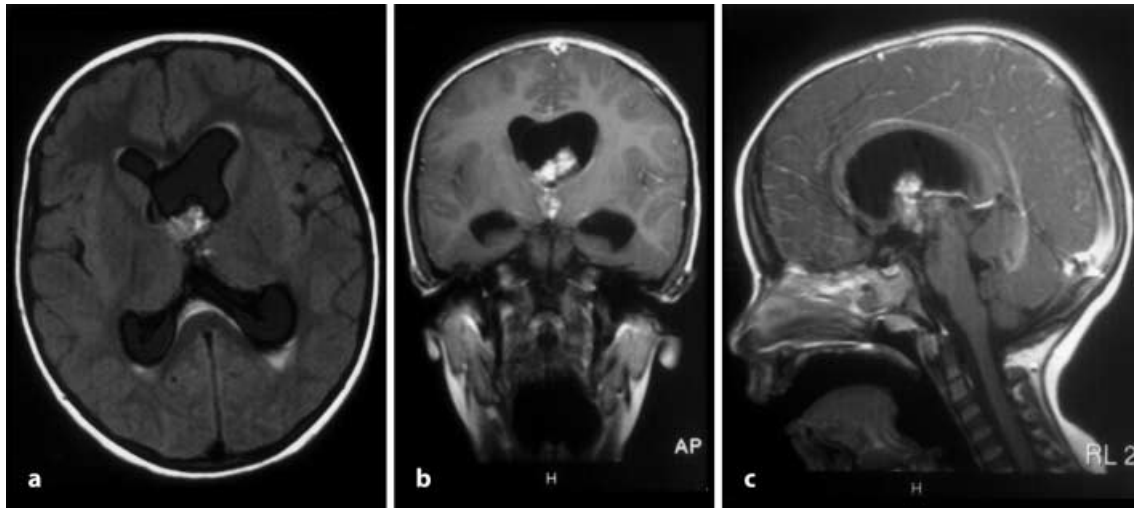


Fig. 1a-c T1 contrast-enhanced **a** axial, **b** coronal and **c** sagittal MRI sequences showing the tumour prolapsing from the lateral ventricle, through the Foramen of Monro into the third ventricle

Choroid plexus papillomas in childhood are most commonly located in the lateral ventricles and usually present subacutely with signs and symptoms of raised ICP secondary to excessive CSF production by the tumour [10, 11] or repeated microhaemorrhages blocking CSF absorption at the arachnoid villi or, unusually, encysting of the ventricles [6]. Less commonly they may present with seizures, subarachnoid haemorrhage or focal neurological deficits [10, 11]. Rare reported presentations include CSF rhinorrhoea [8], intraventricular haemorrhage into an encysted occipital horn [6], bobble-head doll syndrome with drop attacks [15] and as a mimicker

of degenerative brain disease in childhood [14]. Choroid plexus papillomas mimicking a traumatic intracranial haematoma have never previously been reported. We postulate that the head injury precipitated mechanical obstruction of the foramen of Monro by the tumour, which in turn caused a surge in ICP and this caused the patient's depressed conscious level. Alternatively the "head injury" may have been secondary to the tumour impaction in the foramen of Monro.

Conclusion

We report the first case of a lateral ventricular tumour prolapsing through the foramen of Monro into the third ventricle mimicking a significant head injury in presentation.

References

1. Aronica PA, Ahdab-Barmada M, Rozin L, Wecht CH (1998) Sudden death in an adolescent boy due to a colloid cyst of the third ventricle. *Am J Forensic Med Pathol* 19:119–122
2. Buttner A, Winkler PA, Eisenmenger W, Weis S (1997) Colloid cysts of the third ventricle with fatal outcome: a report of two cases and review of the literature. *Int J Legal Med* 110:260–266
3. Byard RW, Moore L (1983) Sudden and unexpected death in childhood due to a colloid cyst of the third ventricle. *J Forensic Sci* 38:210–213
4. Chan RC, Thompson GB (1983) Third ventricular colloid cysts presenting with acute neurological deterioration. *Surg Neurol* 19:358–362
5. DiMaio SM, DiMaio VJ, Kirkpatrick JB (1980) Sudden, unexpected deaths due to primary intracranial neoplasms. *Am J Forensic Med Pathol* 1:29–45
6. Gainer JV Jr, Nugent GR, Chou SM (1975) Unusual presentation of a choroid plexus papilloma. *Surg Neurol* 3:337–339
7. Janisch W, Schreiber D, Martin H, Gerlach H (1984) Primary intracranial tumours as cause of death in the fetus and infant. *Zentralbl Allg Pathol* 129:75–89
8. Lamberts AE (1984) Choroid plexus papilloma with cerebrospinal fluid rhinorrhoea. *Surg Neurol* 22:576–578
9. Mathiesen T, Grane P, Lindgren L, Lindquist C (1997) Third ventricle colloid cysts: a consecutive 12-year series. *J Neurosurg* 86:5–12
10. McEvoy AW, Harding BN, Phipps KP, Ellison DW, Elsmore AJ, Thompson D (2000) Management of choroid plexus tumours in children: 20 years experience at a single neurosurgical centre. *Pediatr Neurosurg* 32:192–199
11. Nagib MG, O'Fallon MT (2000) Lateral ventricle choroid plexus papilloma in childhood: management and complications. *Surg Neurol* 54:366–372

-
12. Nitta M, Symon L (1985) Colloid cysts of the third ventricle. A review of 36 cases. *Acta Neurochir (Wien)* 76:99–104
 13. Opeskin K, Anderson RM, Lee KA (1993) Colloid cyst of the third ventricle as a cause of acute neurological deterioration and sudden death. *J Paediatr Child Health* 29:476–477
 14. Platt M, Rosmann NP (1972) Choroid plexus papilloma mimicking degenerative brain disease in childhood. *J Paediatr* 80:483–484
 15. Pollack IF, Schor NF, Martinez AJ, Towbin R (1995) Bobble-head doll syndrome and drop attacks in a child with a cystic choroid plexus papilloma of the third ventricle. Case report. *J Neurosurg* 83:729–732
 16. Ryder JW, Kleinschmidt-DeMasters BK, Keller TS (1986) Sudden deterioration and death in patients with benign tumours of the third ventricle area. *J Neurosurg* 64:216–223
 17. Shemie S, Jay V, Rutka J, Armstrong D (1997) Acute obstructive hydrocephalus and sudden death in children. *Ann Emerg Med* 29:524–528