

N. Barisic^{1,2}
G. Bernert¹
O. Ipsiroglu¹
C. Stromberger¹
T. Müller¹
S. Gruber³
D. Prayer⁴
E. Moser^{3,4}
R. E. Bittner⁵
S. Stöckler-Ipsiroglu¹

Effects of Oral Creatine Supplementation in a Patient with MELAS Phenotype and Associated Nephropathy

Abstract

An 18-year-old male patient with MELAS phenotype and 2 previous episodes of cerebral stroke, recurrent seizures and nephropathy, was treated with creatine monohydrate after the acute onset of psychomotor regression and changing states of somnolence and aggressive and agitated behaviour. These symptoms disappeared completely after 4 weeks of treatment with creatine after which the patient regained all his previous mental abilities. Brain (white matter) proton magnetic resonance spectroscopy (chemical shift imaging) performed at 6 and 12 months of treatment showed lactic acid (Lac) accumulation and high creatine (Cr) levels in relation to choline-containing compounds (Cho). Urinary creatinine excretion as an indicator of the muscle and brain creatine pool increased upon short-term (12 days) high-dosage creatine supplementation (20 g per day) while plasma creatinine concentrations as possible indicators both of increasing creatine pool and of renal insufficiency increased during the course (28 months) of low-dosage creatine supplementation (5 g per day). Deterioration of renal function was finally indicated by urea retention and by impairment of renal creatinine clearance. These observations suggest that creatine supplementation may have a neuroprotective effect in patients with MELAS and episodes of acute mental deterioration. Adverse effects of creatine supplementation on renal function must be considered especially in patients with preexisting nephropathy.

Key words

Creatine Monohydrate · Mitochondrial Encephalopathy · Stroke · Renal Insufficiency

Abbreviations

MELAS	mitochondrial encephalopathy
Lac	lactic acid
Cr	creatine
Cho	choline-containing compounds
NAA	N-acetylaspartic acid
2 D CSI	2 dimensional chemical shift imaging

Introduction

MELAS phenotype is a multisystem mitochondrial disorder characterized by encephalomyopathy with progressive mental deterioration, lactic acidosis and stroke-like episodes. Various hormonal deficits (e.g., growth hormone deficiency), and nephropathy may be associated [5]. 80% of patients with MELAS have the characteristic A3243G point mutation of mitochondrial (mt) DNA which is frequently associated with complex I deficiency [2]. Single cases with mitochondrial cytochrome c oxidase (complex IV) deficiency as the underlying biochemical defect have been reported [2,5]. Supplementation of cofactors of the respiratory chain (vitamin K3, nicotinamide, riboflavin, ascorbic acid, and coenzyme Q) is recommended in order to improve mitochondrial electron transfer, but a clear-cut improvement of clinical symptoms and long term prognosis has not been reported with this treatment.

Affiliation

- ¹ Department of Pediatrics, University of Vienna, Austria
² Department of Pediatrics, University Medical Center Rebro, Zagreb, Croatia
³ Institute of Medical Physics, University of Vienna, Austria
⁴ Department of Radiology, University of Vienna, Austria
⁵ Neuromuscular Research Department, Institute of Anatomy, University of Vienna, Austria

Correspondence

Prof. Dr. Sylvia Stöckler-Ipsiroglu · Department of Pediatrics, University Hospital and General Hospital of Vienna · Waehringer Guertel 18–20 · 1090 Vienna · Austria · E-mail: stoeckler@metabolic-screening.at

Received: December 1, 2000 · Accepted after Revision: March 3, 2002

Bibliography

Neuropediatrics 2002; 33: 157–161 © Georg Thieme Verlag Stuttgart · New York · ISSN 0174-304X

Table 1 Parameters characteristic of creatine metabolism and renal function in a male patient with MELAS before and during a 28 month period of oral supplementation with creatine monohydrate.

Creatine dosage g/d	Pretreatment	Treatment with creatine monohydrate			
	0	20	5	5	5
Time periods	Before creatine 24–0.5 m	Upon creatine + 12 d	Upon creatine 2 w–6 m	Upon creatine 6–16 m	Upon creatine 16–28 m
Urinary creatinine excretion (g/day)	0.8–1 (n = 3)	1.1–1.5 (n = 7)	0.7–0.9 (n = 4)	0.9–1.1 (n = 4)	0.8–1 (n = 3)
Plasma creatinine (mg/100 ml) rv: 0.2–1.0	1.1–2.1 (n = 3)	1.5–1.8 (n = 3)	1.8–2.4 (n = 4)	1.9–2.4 (n = 4)	2.8–3.1 (n = 3)
Plasma urea (mg/dl) rv: 6–22	16–22 (n = 4)	nd	18–25 (n = 4)	20–26 (n = 4)	35–40 (n = 3)
Creatinine clearance (ml/min/1.73 m) rv: 80–120	54–70 (n = 3)	50–65 (n = 3)	40–50 (n = 4)	40–55 (n = 4)	23–31 (n = 3)
Proteinuria	+ –	+	++	++	++

m = months; w = weeks; nd = not determined, rv = reference values

We report on the effects of creatine monohydrate supplementation in an 18 year-old male patient with MELAS phenotype starting during an acute episode of psychomental deterioration.

Case Report

In this 18-year-old male patient exercise intolerance, developmental delay, and growth retardation were noticed since the age of 5 years. His family history was unremarkable for similar symptoms and signs. At 13 years of age, he experienced a stroke-like episode with aphasia, right hemiparesis and hemianopsia. Neurologic symptoms were reversible within a few days. Brain MRI showed signs of cerebrovascular ischemic insult in the left parieto-occipital region. MR angiography was normal while SPECT showed hypoperfusion of the left parietooccipital region and thalamus. Plasma lactic acid concentrations were constantly elevated (3.3–6.2 mmol/L; normal: 0.6–2.4).

Muscle biopsy showed numerous ragged red fibers and an almost complete lack of histochemical cytochrome-c-oxidase reactivity and diminished reactivity for NADH-tetrazolium reductase-stain. Accordingly, biochemical assessment of mitochondrial respiratory chain enzymes revealed a dramatic decrease of cytochrome-c-oxidase (complex IV) activity (2.9 U/g NCP [non collagenous protein]; normal range: 105–280), associated with a moderate decrease of complex I activity (8.4 U/g NCP; normal range: 11.4–48.0). Measurement of the citrate synthase as mitochondrial reference enzyme revealed high values (231.9 U/g NCP; normal: 43.2–132) reflecting a compensatory proliferation of sarcoplasmic mitochondria (which was also seen by electron microscopy). Mitochondrial (mt) DNA isolated from the muscle biopsy and from peripheral blood was directly sequenced (ABI 377). Neither the most common 3243 MELAS point mutation nor the other known MELAS mutations at positions 583, 1642, 3252, 3256, 3271, 3291, 8356 and 9957 were found. Nuclear SURF 1 gene mutations which may be associated

with autosomal recessive Cox deficiency have not been investigated.

Despite supplementation of cofactors (coenzyme Q, riboflavin, vitamin K3, ascorbic acid) and L-carnitine, he manifested a second stroke-like episode with similar neurologic deficits a few months later. Due to pathologic EEG findings (paroxysmal spike and waves and focal discharges), antiepileptic treatment with carbamazepine was introduced.

Echocardiography showed left ventricular hypertrophy. Endocrinological investigations revealed secondary hypothyroidism and growth hormone deficiency. As a consequence, the patient was substituted with L-thyroxine and with growth hormone. Growth hormone supplementation was stopped after 24 months due to insufficient response of growth velocity.

Moderate renal insufficiency was diagnosed at the age of 15 years by elevation of plasma creatinine concentrations and low renal creatinine clearance (Table 1). Ultrasound showed small, hypotrophic kidneys with multiple parenchymal lesions but without anatomical abnormalities of the ureterovesical tract. At the age of 18 years, crone-EDTA single-shot isotope clearance showed a reduction of glomerular filtration rate (28 mL/min/1.73 m²; normal: 100–140) and of effective renal plasma flow (211 mL/min/1.73 m²; normal 500) with normal calculated tubular function (333 mL/min, normal 300–400), thus indicating main glomerular damage. Total urinary protein excretion was 2.3 g per day consisting mainly of albumin and larger molecules and also pointing towards glomerular damage. Renal biopsy was not performed.

At the age of 17, during intercurrent viral illness, the patient became increasingly confused with loss of major psychomental abilities and changing states of somnolence and aggressive and agitated behaviour. EEG showed slow theta-delta background activity with bilateral temporal focal discharges. Brain MRI

showed no signs of acute cerebral stroke, and plasma lactic acid concentrations remained within the usual range of elevation (3.8–4.8 mmol/L). Antipsychotic treatment with fluoxetine, sertraline, piracetam and chlorpromazine did not result in clinical improvement and thus was discontinued. After 2 weeks he manifested a generalized tonic clonic seizure. Antiepileptic treatment with lamotrigine was introduced and continued throughout the entire follow-up period. Although he remained seizure-free under this medication, EEG abnormalities and psychotic symptoms did not improve.

Under the assumption that intake of high amounts of creatine results in an increase of the mitochondrial high energy creatine-phosphate pool, creatine monohydrate (Chemie Linz AG) was supplemented orally beginning with a saturation dosage of 20 g per day, given in 4 single dosages for 12 days, and followed by a maintenance dosage of 5 g per day (i.e. 2.5–5 times the physiological daily creatine turnover in healthy adults), given in two single dosages. Loading dose was used in order to achieve rapid increase of total body creatine stores [3]. As patients with mitochondrial cytopathies in general have low cellular creatine phosphate levels [4] a maintenance dose of 5 g was chosen in order to keep the intracellular creatine store constant.

Results

After 7 days of creatine supplementation, the symptoms of psychomotor regression and aggressive behaviour improved significantly and they had disappeared completely after 4 weeks of treatment when the patient had regained all his previous mental abilities. He was able to work with textiles in a special workshop for handicapped persons and to support himself in everyday life activities as before. Neuropsychologic testing (visual organisation and visual motor integration test) at 6 weeks after the psychotic crisis revealed an IQ of <65. 6 months later there was a clear improvement of his vocabulary, his concentration and alertness, while his IQ remained unchanged. EEG improved after 4 weeks of creatine treatment. The patient remained without seizures during the 28 month period of treatment.

In vivo proton magnetic resonance spectroscopy (MRS) of the brain, performed after 6 months of treatment, showed increased Cr as related to Cho and high Lac levels in most brain voxels studied. Levels of N-acetyl-aspartate (NAA) as a neuronal marker are low in most voxels (Fig. 1). Similar results were obtained at a second measurement 12 months later. Plasma lactate levels remained in the usual range of mild elevation during the creatine treatment period.

Various parameters characteristic for creatine metabolism and renal function are shown in Table 1. Plasma creatine was determined by an HPLC method as described. Creatinine was determined by a dry chemistry method (Kodak Ektachem). Determination of plasma and urinary creatinine in single samples obtained during the supplementation period both by dry chemistry and HPLC method did not show significant differences between the values obtained with both methods, thus excluding coreaction of plasma creatine and artificially high creatinine values on dry chemistry during creatine supplementation.

Discussion

The rationale for creatine therapy in this patient was mainly based on experimental and clinical reports showing that high dosages of creatine result in an increase of total creatine and of creatine phosphate in brain and muscle [4,8]. Furthermore, in patients with mitochondrial disorders, brain and muscle creatine are decreased, and creatine supplementation might be of substantial benefit in such patients [10]. Finally, creatine acts as an inhibitor of collagen-induced in vitro thrombocyte aggregation [7] and therefore might be beneficial in the prevention of vascular incidents especially in patients with MELAS. A favorable response to creatine monohydrate supplementation at a dose 20 g/day/2 weeks and 2 g thereafter has recently been reported in one MELAS patient, with increased exercise performance and decrease in headache intensity [3]. In our patient, the most striking clinical observation was the prompt improvement of psychotic symptoms, aggressive behaviour and mental deterioration. Additionally, an improvement of pathologic EEG findings was registered after 2 weeks of creatine supplementation while antiepileptic treatment alone had not been effective. The onset of improvement coincides with creatine supplementation persisting during the whole 28-month observation period. We therefore assume that the favourable outcome in our patient is causally related to creatine supplementation, although it remains unclear if there was also some spontaneous remission.

Creatinine is the conversion product of intracellular creatine and creatine phosphate [9]. Therefore, the significant increase of the urinary creatinine excretion during the saturation phase with 20 g creatine monohydrate per day indicated cellular uptake and metabolic utilisation of the supplemented creatine. Proton MRS of the brain showed low absolute creatine concentrations in a series of MELAS patients who were not on creatine supplementation [11]. In our patient, MRS data prior to treatment are not available, but brain MRS performed during creatine supplementation showed high creatine levels in relation to choline-containing compounds. Although our chemical shift imaging (CSI) approach allows only qualitative estimation of metabolite ratios, this finding might reflect creatine accumulation in the brain in response to oral supplementation.

As possible side effects of creatine monohydrate, renal insufficiency and impairment of renal creatinine clearance have been reported in a subject with a history of focal glomerulosclerosis and in one healthy athlete upon a daily intake of 15–20 g creatine monohydrate, respectively [6]. Both side effects were reversible upon reduction of the daily creatine dosage. In our patient with preexisting renal disease, plasma creatinine concentrations and renal creatinine clearance were already abnormal prior to creatine supplementation. During the 28-month period of supplementation, there was slow progression of the renal insufficiency with increasing plasma creatinine concentrations and moderate urea retention. In contrast to the cases described in the literature, in our patient creatine was supplemented in a comparatively low dose. Therefore, we believe that the deterioration is due rather to the natural course, than to the creatine supplement.

In conclusion, the observations in this patient with MELAS and associated nephropathy suggest that creatine supplementation

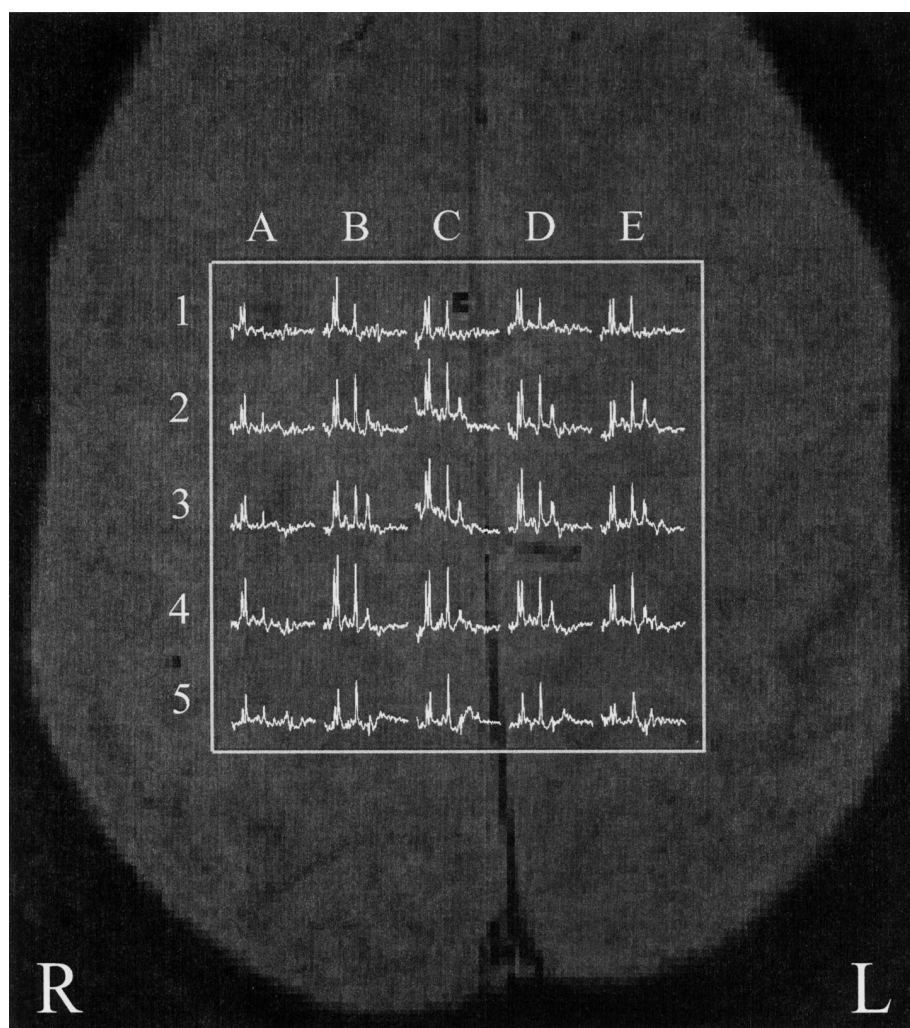
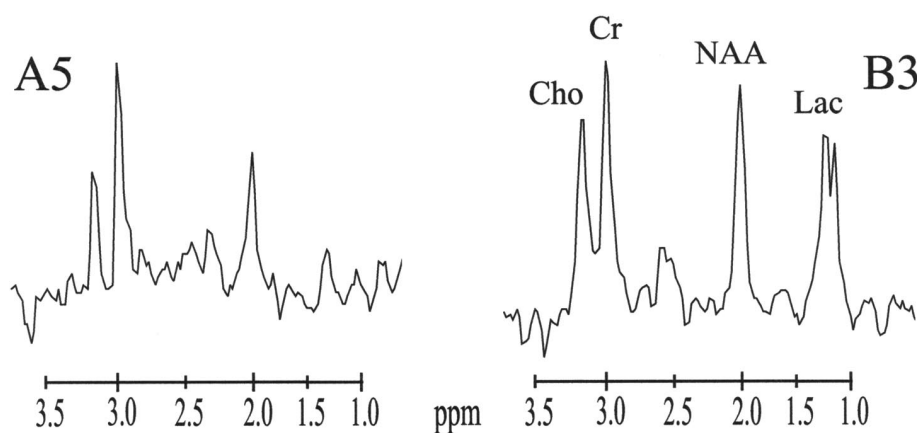


Fig. 1 In vivo 2 D CSI with a 6 cm × 6 cm point resolved spectroscopy (PRESS) excitation in the brain of patient with MELAS after 6 months oral creatine supplementation (slice thickness 1.8 cm, 16 × 16 CSI-encoding, 20 cm × 20 cm field of view, 1.6 s repetition time, 144 ms echo time, 2 averages, 17 min measurement time). CSI slice in the parietooccipital white brain matter (horizontal section) showed lactic acid (Lac) accumulation and high creatine (Cr) levels in relation to choline containing compounds (Cho). Two types of voxels could be distinguished: Type 1 with with extremely low Cho and NAA and relatively high Cr (e.g. A5); type 2 with low NAA, high Cr (related to Cho) and pronounced Lac elevation (e.g. B3).



may have a neuroprotective effect preventing psychomotor deterioration and epileptic seizures. Careful monitoring both of creatine metabolism and of renal function parameters are of importance in the evaluation of creatine utilisation and of possible side effects. Follow-up of creatine uptake in brain tissue may be performed using proton MRS.

Acknowledgments

N. Barisic and S. Gruber were supported by grants from the American Austrian Society and the Fonds zur wissenschaftlichen Förderung des Bürgermeisters der Stadt Wien.

References

- ¹ Delanghe J, Buyzere de M, Baele G. Creatine inhibits adenosine diphosphate and collagen-induced thrombocyte aggregation. In: de Deyn PP, Marescau B, Stalon V, Qureshi IA (Eds). *Guanidino compounds in biology & medicine*. London: John Libbey & Company, 1992: 207–211
- ² Goto Y, Horai S, Matsuoka T, Koga Y, Nihei K, Kobayashi M, Nonaka I. Mitochondrial myopathy, encephalopathy, lactic acidosis, and stroke-like episodes (MELAS): A correlative study of the clinical features and mitochondrial DNA mutation. *Neurology* 1992; 42: 545–550
- ³ Hagenfeldt I, Dobein U, Solders G, Kaijser L. Creatine treatment in MELAS. *Muscle & Nerve* 1994; 17: 1236–1237
- ⁴ Harris RC, Soderland K, Hultman E. Elevation of creatine in resting and exercised muscle of normal subjects by creatine supplementation. *Clin Sci* 1992; 83: 367–372
- ⁵ Hirano M, Pavlakis SG. Mitochondrial myopathy, encephalopathy, lactic acidosis, stroke like episodes (MELAS): current concepts. *J Child Neurol* 1994; 9: 4–13
- ⁶ Pritchard NR, Kalra PA. Renal dysfunction accompanying oral creatine supplements. *Lancet* 1998; 351: 1252–1253
- ⁷ Radda GK, Odoom J, Kemp G, Taylor DJ, Thompson C, Styles P. Assessment of mitochondrial function and control in normal and diseased states. *Biochim Biophys Acta* 1995; 1271: 15–19
- ⁸ Stöckler S, Hanefeld F, Frahm J. Creatine replacement therapy in guanidinoacetate methyltransferase deficiency, a novel inborn error of metabolism. *Lancet* 1996; 348: 789–790
- ⁹ Stöckler S, Marescau B, Deyn de PP, Trijbels JMF, Hanefeld F. Guanidino compounds in guanidinoacetate methyltransferase deficiency, a new inborn error of creatine synthesis. *Metabolism* 1997; 46: 1189–1193
- ¹⁰ Tarnopolsky MA, Roy BD, McDonald JR. A randomized, controlled trial of creatine monohydrate in patients with mitochondrial cytopathies. *Muscle Nerve* 1997; 20: 1502–1509
- ¹¹ Wilichowski E, Pouwels PJW, Frahm J, Hanefeld F. Quantitative proton magnetic resonance spectroscopy of cerebral metabolic disturbances in patients with MELAS. *Neuropediatrics* 1999; 30: 256–263