



Videotape Brief

Levodopa-Responsive Rubral (Holmes') Tremor

Miriam Vélez, MD, Carlos Cosentino, MD,* and Luis Torres, MD

Movement Disorders Unit, Instituto de Ciencias Neurológicas "Oscar Trelles Montes" Lima, Peru

Case Report

A 25-year-old, right-handed man, previously in good health, suddenly developed drowsiness and left hemiparesis. This was followed by disturbance of consciousness, which rapidly progressed to coma. A computed tomography scan performed some hours later showed right-midbrain hemorrhage. Two weeks later, he regained consciousness but had complete right-lid ptosis; diplopia; right hemiataxia; left hemiparesis; and an involuntary movement characterized by dystonia-like postures in the left hemibody, most apparent in the upper left limb. This movement was not present during sleep and lasted for a few weeks. Two months after the hemorrhage, a mild-intensity, large-amplitude resting tremor arose in the left hemibody. Tremor was also present during posture and action and was worsened by emotional stress. Dystonic posture of the distal upper limb with ulnar deviation was also noted. At that time, gait was very difficult. MRI obtained 2 years posthemorrhage showed a small right-midbrain T1 hyposignal corresponding to hemorrhage sequel (Fig. 1). The patient was given a single oral dose of levodopa-carbidopa (250/25); this resulted in excellent improvement in his tremor that persisted for about 3 hours. In view of this, he was started on levodopa-carbidopa 250/25 3 times a day. He has received levodopa in the same dose for more than 6 months, and the treatment has maintained the same clinical efficacy.

A videotape accompanies this article.

*Correspondence to: Carlos Cosentino, Movement Disorders Unit, Instituto de Ciencias Neurológicas "Oscar Trelles Montes," Jr. Ancash 1271, Lima 1, Peru. E-mail: cosenti@terra.com.pe

Received 3 July 2001; Revised 8 January 2002; Accepted 22 February 2002

Published online 25 April 2002 in Wiley InterScience (www.interscience.wiley.com). DOI 10.1002/mds.10224

Discussion

Rubral or midbrain tremor (RT) was classically described by Gordon Holmes in 1904. It usually arises as a delayed manifestation of lesions in the upper brainstem, such as stroke or trauma. This kind of tremor is predominantly unilateral and occurs not only at rest but also in posture and during movement, and disappears during sleep. It has a low frequency of 3 to 5 Hz and is often exacerbated by goal-directed movements. RT cannot be voluntarily controlled, and any attempt to inhibit the tremor often results in its enhancement.

RT is caused by lesions near the red nucleus; however, as isolated lesions in this nucleus do not necessarily in-

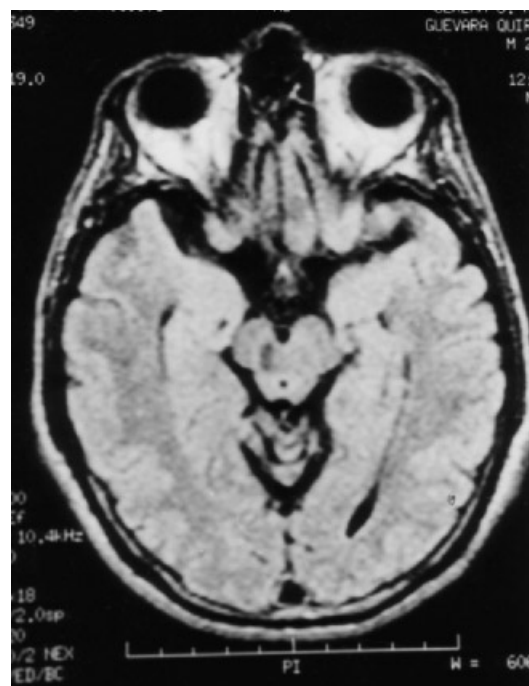


FIG. 1. Axial T₁-weighted image showing a post-hemorrhagic lesion in the right midbrain near the red nucleus.

duce tremor, it might be preferable to use the term *midbrain tremor*. Indeed, clinicopathological correlations demonstrate that RT does arise from ipsilateral lesions of the dentate nucleus or the superior cerebellar peduncle or from contralateral inferior olivary involvement.

It has been suggested that RT is a combined parkinsonian rest tremor associated with cerebellar postural and action tremor. Remy and colleagues¹ found a marked decrease in ¹⁸F-dopa reuptake in the caudate and putamen of patients with RT due to midbrain lesions, likely reflecting ipsilateral severe striatal dopaminergic denervation. The finding that levodopa improves RT in some patients supports the suggestion that the dopaminergic pathway is involved (the substantia nigra, nigrostriatal fibers, or both).^{1,2} The postural component of RT could be related to disruption of the cerebellar outflow pathway (the dentatohalamic and dentatorubral tracts) at the superior cerebellar peduncle and the rubro-olivary tract in the central tegmentum.

Although the tremor may lessen or resolve spontaneously within 1 year after onset, the natural course in most patients is characterized by persistence of violent shaking movements. The treatment of RT has been notoriously disappointing, and only isolated cases of partial or complete relief have been reported with the use of several drugs.³⁻⁵ Surgical treatments, such as stereotaxic thalamotomy⁶ or thalamic stimulation,⁷ may have an important place in the management of medical refractory tremor. Although there are some reports of worsening or no response of RT with levodopa, our patient had a marked improvement of his tremor, as have a small number of other patients in the literature. The beneficial re-

sponse to levodopa in patients with RT supports the theory of impairment of the dopaminergic pathway by the midbrain vascular lesion in an area adjacent to or also involving the red nucleus, the subthalamus, or both, where the ventral rubrospinal tract, the dopaminergic pathway, and the cerebellofugal system are principally affected.

Legends to the Videotape

Segment 1. This segment demonstrates a left-sided rest, posture, and action tremor during sitting and hemiparesis. The patient, who was not receiving any treatment, was unable to stand or walk.

Segment 2. This segment was recorded 1 hour after a single 250-mg dose of levodopa.

REFERENCES

1. Remy P, de Recondo A, Defer G, Loc'h C, Amarencu P, Plante-Bordeneuve V, Dao-Castellana MH, Bendriem B, Crouzel C, Clanet M, et al. Peduncular 'rubral' tremor and dopaminergic denervation: a PET study. *Neurology* 1995;45:472-477.
2. Defer G, Remy P, Malapert D, Ricolfi F, Samsom Y, Degos J. Rest tremor and extrapyramidal symptoms after midbrain haemorrhage: clinical and ¹⁸F-dopa PET evaluation. *J Neurol Neurosurg Psychiatry* 1994;57:987-989.
3. Jacob PC, Pratap Chand R. Posttraumatic rubral tremor responsive to clonazepam. *Mov Disord* 1998;13:977-978.
4. Ellison PH. Propranolol for severe post-head injury action tremor. *Neurology* 1978;28:197-199.
5. Findley LJ, Gresty MA. Suppression of "rubral" tremor with levodopa. *Br Med J* 1980;281:1043.
6. Krauss JK, Mohadjer M, Nobbe F, Munding F. The treatment of posttraumatic tremor by stereotaxic surgery. *J Neurosurg* 1994;80:810-919.
7. Kudo M, Goto S, Nishikawa S, Hamasaki T, Soyama N, Ushio Y, Mita S, Hirata Y. Bilateral thalamic stimulation for Holmes' tremor caused by unilateral brainstem lesion. *Mov Disord* 2001;16:170-174.