

Successful treatment of acute promyelocytic leukaemia during pregnancy

D. CARRADICE*, *Department of Haematology, Christchurch Hospital, New Zealand
N. AUSTIN†, †Department of Neonatology, Women's Hospital, Christchurch, New Zealand
K. BAYSTON‡, ‡Southland Hospital, Kew Road, Invercargill, New Zealand
P. S. GANLY§ §Department of Haematology, Christchurch Hospital, New Zealand

Summary A case is reported of a pregnant 16-year-old-woman diagnosed with Acute promyelocytic leukaemia (APL) at 25 weeks gestation and treated with all-*trans* retinoic acid (ATRA) (45 mg/m²) for 25 days in combination with chemotherapy. She achieved a complete cytogenetic and molecular remission. Clinical course was complicated, with an intracerebral bleed, respiratory failure requiring ventilation and prolonged pancytopenia following initial chemotherapy. A live female infant was born at 28 weeks gestation who survived to discharge with significant pulmonary complications. She remains oxygen dependent at 6 months of age. ATRA has been used from the 3rd week of gestation, but fetal malformations are common during the first trimester. In contrast it seems to be safe in the second and third trimesters with regard to teratogenesis but can cause other side-effects. Most successful outcomes in treatment of APL during pregnancy are seen after treatment with ATRA and delivery of the baby at as late a stage as possible. Pregnancies terminated before remission has been obtained or those treated in the first trimester have a poor maternal outcome.

Keywords Promyelocytic, leukaemia, pregnancy, all trans retinoic acid, complications

Introduction

Leukaemia during pregnancy is rare, reported in approximately 350 cases since 1845 (Caligiuri & Mayer, 1989). Of these, 39 have been acute promyelocytic leukaemia (APL) (Celo *et al.*, 1994; Tsuda *et al.*, 1994; Hoffman *et al.*, 1995; Delgado-Lamas & Garces-Ruiz, 2000; Giagounidis *et al.*, 2000; Breccia *et al.*, 2001), and of these, three were treated with a combination of all trans retinoic acid (ATRA) and conventional chemotherapy (Breccia *et al.*, 2001; Delgado-Lamas & Garces-Ruiz, 2000; Giagounidis *et al.*, 2000). We report a case of APL diagnosed in pregnancy and treated with both ATRA and chemotherapy.

Case report

A 16-year-old-woman, gravida 1, para 0, presented in the 25th week of pregnancy with easy bruising, epistaxis, haematuria and lethargy. The patient had concealed pregnancy until the 20th week and she had received no antenatal care. On arrival she was febrile, bruising was noted over both lower legs and there were petechiae in the oral cavity. There were bilateral retinal haemorrhages. Cardiovascular and respiratory systems were normal and abdominal examination revealed an enlarged uterus compatible with dates.

Laboratory data showed a haemoglobin of 74 g/l (after transfusion of 4 units of packed red cells), white cell count $1.9 \times 10^9/l$, neutrophils $0.04 \times 10^9/l$, myelocytes $0.04 \times 10^9/l$, promyelocytes $1.0 \times 10^9/l$, nucleated RBC 0.48×10^9 , platelets $23 \times 10^9/l$. Coagulation parameters are shown (Table 1). Other laboratory investigations revealed normal renal and hepatic profiles and serum

Accepted for publication 17 July 2002

Correspondence: Duncan Carradice, Department of Haematology, Canterbury Health Laboratories, PO Box 151, Christchurch, New Zealand.

E-mail: duncancarradice@doctors.org.uk

Table 1. Laboratory values on admission, after 3 days and at time of intracranial haemorrhage. Values outside normal ranges in bold

Day following admission	0	3	8
Prothrombin ratio	1.6	1.3	1.1
APTT (s) (control range 26–36)	33	37	31
TCT (s) (control range 18–25)	49	37	25
Fibrinogen (g/l)	0.6	1.8	2.4
Platelet count ($10^9/l$)	24	71	51
D-dimers (mg/l)	> 1000	> 1000	> 1000
Clinical haemorrhagic features	Skin bruising		Intracranial
	Oral petechiae		haemorrhage
	Bilateral retinal haemorrhages		Haematuria
	Bleeding from bone marrow aspirate site	Bleeding from bone marrow site stopped	
	Epistaxis	Epistaxis stopped	Epistaxis

lactate dehydrogenase of 659 U/l. Blood film showed frequent promyelocytes and occasional Auer rods. Bone marrow aspirate was hypercellular with 90% hypergranular promyelocytes with occasional Auer rods. Immunophenotyping was consistent with APL and cytogenetics revealed t (15:17) in all 17 metaphases studied. RT-PCR was positive for a type B PMR/RAR- α transcript.

Ultrasound scan revealed a live, normal fetus at 25 weeks gestation with an approximate weight of 370 g. A diagnosis of APL was made and discussion ensued with the patient regarding termination, the possible adverse effects of the chemotherapy on the fetus and the risks to her of continuing with the pregnancy. She decided to continue with the pregnancy and received induction chemotherapy with Idarubicin and ATRA as per the PETHEMA protocol for treatment of APL (Sanz *et al.*, 1999).

The obstetric and neonatal teams were involved and regular fetal heart rate checks and ultrasound scans organized.

Following treatment with fresh frozen plasma, platelets and cryoprecipitate the coagulation parameters were improved by the 3rd day of admission (See Table 1). Commencement of ATRA and chemotherapy was complicated by febrile neutropenia, respiratory impairment with hypoxia and bilateral pulmonary infiltrates, haemorrhagic features including bleeding from the bone marrow aspirate site for 96 h, epistaxis, haematuria and subconjunctival as well as retinal haemorrhages.

On day 8 of admission despite relatively normal coagulation parameters and platelet count of $51 \times 10^9/l$ she developed sudden onset of dense left-sided weakness. CT scan of the head revealed a 55×32 mm haemorrhage in the right frontal lobe with rupture into the right lateral ventricle, but no signs of raised intracranial pressure (Figure 1).

She was unable to move the left arm or leg and unable to weight bear or walk. She was treated conservatively with high dose dexamethasone as the combination of neutropenia, thrombocytopenia and haemorrhagic features precluded operative decompression. Tranexamic acid was commenced, having been avoided earlier due to persistent haematuria. Further complications ensued including tonic-clonic seizures, severe headache requiring morphine, continuing haematuria, severe oral mucositis and poor nutritional intake requiring total parenteral nutrition.

Despite this the fetus remained viable and ultrasound scan done on day 13 showed satisfactory growth with an estimated weight of 1000 g and a small pericardial effusion. The patient developed a left sixth cranial nerve palsy and repeat CT scan of the head done on day 19 showed persisting haemorrhage with marked surrounding oedema and slight midline shift but no distortion of the brainstem. Despite an initial response to broad-spectrum antibiotics, temperature again rose and amphotericin was started for persistent neutropenic fever. Sudden deterioration occurred 26 days after admission with dyspnoea, chest pain, tachypnoea, hypoxia and bilateral pulmonary infiltrates on chest radiograph.

She was transferred to the intensive care unit and ventilation was required. Repeat fetal ultrasound showed continued growth but fetal ascites, oligohydramnios and high umbilical artery resistance indicating placental insufficiency and intrauterine growth retardation. Therapy continued with amphotericin and broad spectrum antibiotics. G-CSF was commenced. Bronchoscopy and lavage was performed but no pathogenic organisms were seen on microscopy or culture. ATRA was stopped due to the possibility of ATRA syndrome.

At this time, clinical suspicion and ultrasound confirmed spontaneous membrane rupture and breech presentation,

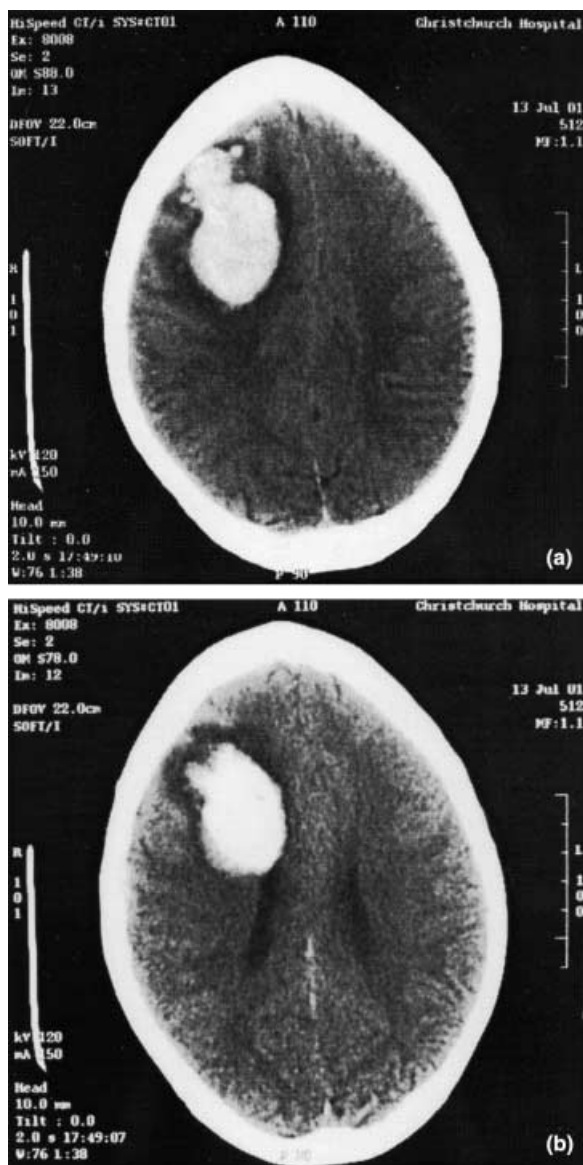


Figure 1. CT scan done on day 8 of admission showing extensive haemorrhage in the right frontal lobe with intraventricular extension.

and in view of the concerns regarding the patient and her baby with continuation of the pregnancy, Caesarean section was performed in the 28th week.

By day 32, the patient's clinical status was markedly improved, her blood counts recovered and she was extubated. Recovery continued but was complicated further with diplopia secondary to the sixth nerve palsy, neutropenic fever following the second course of consolidation treatment and a second seizure. She convalesced at a unit specializing in brain injury treatment. RT-PCR on peripheral blood 7 weeks after commencement of induction treatment was negative for the PML/RAR α transcript detected at diagnosis.

Currently at 9 months following diagnosis she is well, and has returned to school, the only residual neurological deficit being slight weakness of the grip in the left hand. Additional anticonvulsant therapy has been required to control focal seizures. She remains negative on RT-PCR for the PML-RAR α transcript in peripheral blood and bone marrow and continues with maintenance chemotherapy.

A live female infant of 1475 g was born at 28 weeks in poor condition. Her Apgars were 2 at 1 minute, 4 at 5 min and 6 at 10 min. The lung volumes appeared low suggesting a degree of pulmonary hypoplasia. Her initial ventilation was complicated by bilateral pneumothoraces. On day 3 her patent ductus arteriosus was large and haemodynamically significant. This closed after indomethacin was given. By day 5 she had deteriorated while on maximal ventilation. A 10-day Dexamethasone course was given with significant improvement and she was able to be extubated on day 10 onto continuous positive pressure oxygen. She continued to be tachypnoeic until day 54 following which she needed low flow oxygen at 0.9–1.3 l/min. Head ultrasound did not show any haemorrhages although she did develop some mild ventricular dilatation on the left. At last follow up the baby continues on nasal oxygen and diuretics with significant respiratory effort and poor overall growth. Her developmental progress remains under review.

Discussion

Leukaemia in pregnancy is not more common than the incidence expected in women of childbearing age of 0.9–1.2 cases per 100,000 women-years (Catanzarite & Ferguson, 1984). APL has been reported in approximately 10% of cases of leukaemia in pregnancy, similar to the percentage in nonpregnant leukaemia. Prompt treatment of leukaemia in the mother is necessary as delaying treatment leads to a poor prognosis both for the mother and foetus. Thus, five of six mothers with untreated leukaemia at the time of delivery died within eight weeks, mainly from haemorrhage (Catanzarite & Ferguson, 1984). Following treatment, remission rate and long-term survival are similar to those seen in nonpregnant patients (Caligiuri & Mayer, 1989).

Management of APL in pregnancy cannot currently be based on evidence from well-designed trials so relies on data from historical cases and discussion with the individual patient. Our patient presented in the second trimester and, after informed discussion, elected to continue with the pregnancy and receive induction chemotherapy for her leukaemia.

Concerns are often raised about administration of ATRA during pregnancy because of retinoid embryopathy, leading to fetal malformations in 20% of children if given during the first trimester (Lammer *et al.*, 1985; Rosa, 1993). ATRA has been given to treat APL in all stages of pregnancy, but appears to be reasonably safe and well tolerated if given outside the first trimester. A review of 13 cases of APL in pregnancy treated with ATRA did not reveal any fetal malformations that could be attributed to ATRA (Giagounidis *et al.*, 2000). Conventional chemotherapy given to treat leukaemia during pregnancy is not associated with a marked increase in rate of malformations or long-term sequelae (Reynoso *et al.*, 1987; Aviles & Niz, 1988).

Haemostasis as measured by laboratory tests was impaired at presentation with hypofibrinogenaemia and prolongation of the PT and APTT. APL is associated with primary fibrinolysis thought to be mediated by increased Annexin II expression on the surface of the malignant promyelocytes. Resolution of the coagulopathy usually occurs within a few days of commencing ATRA due to reduction in surface expression of Annexin II (Menell *et al.*, 1999). However in this case disastrous intracranial bleeding occurred 8 days after commencement of treatment and with relatively normal coagulation parameters and platelet count. Prothrombin time, APTT and fibrinogen do not give an accurate estimation of the amount of systemic fibrinolysis in APL (Falanga & Barbui, 2001). A previously described case had a prolonged bleeding time 2 weeks after ATRA was started (Lipovsky *et al.*, 1996). Clinical bleeding problems were much more marked before the introduction of ATRA (Visani *et al.*, 2000) but continued vigilance is needed to monitor and prevent fatal haemorrhage during induction treatment.

The ATRA syndrome occurs in 10% of patients treated with ATRA (Visani *et al.*, 2000). Although in our case the sudden onset of respiratory distress, fever and bilateral pulmonary infiltrates on chest X-ray was considered most likely due to an infectious agent, ATRA was withdrawn as 3½ weeks of therapy had already been given. The late onset, the low white blood cell count at the time and already being on systemic steroids made ATRA syndrome unlikely.

Despite a presentation and clinical course that initially appeared grave, once initial chemotherapy had been given and a remission obtained, the subsequent course was more straightforward. Continued remission is likely with maintenance chemotherapy and ATRA (89% complete remission rate during induction and 92% disease free survival at 2 years for those achieving CR) (Sanz *et al.*, 1999). Recovery has been astonishing considering the

neurological deficit produced by the intracranial bleed. Despite the adverse features and stormy clinical course outlined in this case, APL is a leukaemia of good prognosis using current treatments.

References

- Aviles A. & Niz J. (1988) Long-term follow-up of children born to mothers with acute leukemia during pregnancy. *Medical-pediatrics Oncology* **16**, 3–6.
- Breccia M., Cimino G., Alimena G., Carolis S.D., Lo Coco F. & Mandelli F. (2001) AIDA treatment for high-risk acute promyelocytic leukaemia in a pregnant woman at 21 weeks of gestation. *Haematologica* **86**, E37.
- Caligiuri M.A. & Mayer R.J. (1989) Pregnancy and leukemia. *Semin Oncology* **16**, 388–396.
- Catanzarite V.A. & Ferguson J.E. (1984) Acute leukemia and pregnancy: a review of management and outcome, 1972–82. *Obstetrics and Gynecological Survey* **39**, 663–678.
- Celo J.S., Kim H.C., Houlihan C., Canavan B.F., Manzullo G.P. & Saidi P. (1994) Acute promyelocytic leukemia in pregnancy: all-trans retinoic acid as a newer therapeutic option. *Obstetrics and Gynecology* **83**, 808–811.
- Delgado-Lamas J.L. & Garces-Ruiz O.M. (2000) Malignancy: Case Report: Acute Promyelocytic Leukemia in Late Pregnancy. Successful Treatment with All-Trans-Retinoic Acid (ATRA) and Chemotherapy. *Hematology* **4**, 415–418.
- Falanga A. & Barbui T. (2001) Coagulopathy of acute promyelocytic leukemia. *Acta Haematologica* **106**, 43–51.
- Giagounidis A.A., Beckmann M.W., Giagounidis A.S., Aivado M., Emde T., Germing U., Riehs T., Heyll A. & Aul C. (2000) Acute promyelocytic leukemia and pregnancy. *European Journal of Haematology* **64**, 267–271.
- Hoffman M.A., Wiernik P.H. & Kleiner G.J. (1995) Acute promyelocytic leukemia and pregnancy. A case report. *Cancer* **76**, 2237–2241.
- Lammer E.J., Chen D.T., Hoar R.M., Agnish N.D., Benke P.J., Braun J.T., Curry C.J., Fernhoff P.M., Grix A.W. Jr & Lott I.T. & (1985) Retinoic acid embryopathy. *N Engl Journal of Medy* **313**, 837–841.
- Lipovsky M.M., Biesma D.H., Christiaens G.C. & Petersen E.J. (1996) Successful treatment of acute promyelocytic leukaemia with all-trans- retinoic-acid during late pregnancy. *British Journal of Haematology* **94**, 699–701.
- Menell J.S., Cesarman G.M., Jacovina A.T., McLaughlin M.A., Lev E.A. & Hajjar K.A. (1999) Annexin II and bleeding in acute promyelocytic leukemia. *New England Journal of Medicine* **340**, 994–1004.
- Reynoso E.E., Shepherd F.A., Messner H.A., Farquharson H.A., Garvey M.B. & Baker M.A. (1987) Acute leukemia during pregnancy: the Toronto Leukemia Study Group experience with long-term follow-up of children exposed in utero to chemotherapeutic agents. *Journal of Clinical Oncology* **5**, 1098–1106.
- Rosa F. (1993) 'Retinoids in Clinical Practice. *The Risk-Benefit Ratio*'. In: G.Koren, ed. M Dekker, New York, pp. 77–109.
- Sanz M.A., Martin G., Rayon C., Esteve J., Gonzalez M., Diaz-Mediavilla J., Bolufer P., Barragan E., Terol M.J., Gonzalez J.D., Colomer D., Chillon C., Rivas C., Gomez T., Ribera J.M.,

- Bornstein R., Roman J., Calasanz M.J., Arias J., Alvarez C., Ramos F. & Deben G. (1999) A modified AIDA protocol with anthracycline-based consolidation results in high antileukemic efficacy and reduced toxicity in newly diagnosed PML/RAR-alpha-positive acute promyelocytic leukemia. PETHEMA group. *Blood* **94**, 3015–3021.
- Tsuda H., Doi H., Inada T. & Shirono K. (1994) [Successful treatment of acute promyelocytic leukemia in a pregnant woman by using all-trans retinoic acid]. *Rinsho Ketsueki* **35**, 717–719.
- Visani G., Gugliotta L., Tosi P., Catani L., Vianelli N., Martinelli G., Ottaviani E., Testoni N., Nocentini F., Pastano R., Piccaluga P., Isidori A., Grafone T. & Tura S. (2000) All-trans retinoic acid significantly reduces the incidence of early hemorrhagic death during induction therapy of acute promyelocytic leukemia. *European Journal of Haematology* **64**, 139–144.