

CASE REPORT

Angiokeratoma corporis diffusum in a Spanish patient with aspartylglucosaminuria

E. VARGAS-DÍEZ, A. CHABÁS,* M. J. COLL,* J. SÁNCHEZ-PÉREZ, A. GARCÍA-DÍEZ AND J. M. FERNÁNDEZ-HERRERA

Department of Dermatology, Hospital Universitario de la Princesa, C/Diego de León 62, 28006 Madrid, Spain

*Institut de Bioquímica Clínica, Barcelona, Spain

Accepted for publication 31 January 2002

Summary

Angiokeratoma corporis diffusum (ACD), initially considered to be synonymous with Fabry's disease, represents a well-known cutaneous marker of some other lysosomal enzyme disorders. Aspartylglucosaminuria (AGU) is a rare hereditary disorder mostly affecting the Finnish population, with only a few sporadic patients of non-Finnish origin. To date, only three patients with AGU have been reported with cutaneous lesions of ACD. A 19-year-old Spanish woman presented with a 10-year history of progressive ACD affecting the limbs, buttocks and trunk. After the age of 6 years she had developed progressive mental deterioration, coarse facies and macroglossia with a scrotal appearance. Peripheral blood smears showed many vacuolated lymphocytes. Enzyme analysis in cultured fibroblasts revealed a decreased activity of aspartylglucosaminidase. By the age of 31 years the patient had developed a bipolar psychosis, polycystic ovarian disease and severe impairment of cognitive skills. This is the first case of AGU detected in a Spanish patient presenting with cutaneous lesions of ACD. To our knowledge, macroglossia with a scrotal appearance and polycystic ovarian disease have not been reported in previous cases of AGU.

Keywords: angiokeratoma corporis diffusum, aspartylglucosaminuria, aspartylglucosaminidase, enzyme deficiency

Aspartylglucosaminuria (AGU) represents a rare, recessively inherited, disorder of glycoprotein metabolism caused by a deficiency of the lysosomal enzyme 1-aspartamido- β -N-acetylglucosamine-aminohydrolase (aspartylglucosaminidase, AGA).¹ This enzyme deficiency results in accumulation of aspartylglucosamine as the main biochemical compound in various tissues. The clinical picture was first described by Autio in 1972 in 34 Finnish patients, including 13 children.² AGU is characterized by dysfunction of the central nervous system including delayed speech development and mild motor clumsiness in childhood and severe mental retardation in adulthood. This psychomotor impairment is associated with coarse facial features and degenerative changes in connective tissue. To date, most patients with AGU have been diagnosed in Finland, with the exception of a few sporadic cases

reported from elsewhere. The calculated incidence of AGU in the Finnish population is 1 : 18 000 in newborns, with more than 200 patients reported to date, and about 40 in other countries.³ Angiokeratoma corporis diffusum (ACD) is a well-known feature of some lysosomal storage diseases. Nevertheless, it has only been reported to occur as a dermatological manifestation in three cases of AGU.^{4,5} We describe the first case of AGU diagnosed in a Spanish patient with cutaneous lesions of ACD.

Case report

A 19-year-old Spanish woman was seen in 1988 with a 10-year history of progressive appearance of tiny red to blue-black papules initially affecting the right buttock, but progressively extending to the right leg. Over the previous few months, some of the lesions had become larger and bled easily after minor trauma. The patient was born by normal delivery after an uncomplicated

Correspondence: Erich Vargas-Díez.
E-mail: erichvargas@jazzfree.com

full-term pregnancy. Perinatal history was normal except for an umbilical hernia and a history of recurrent upper respiratory and ear infections from the first month of life until the age of 13 years. After the age of 12 months, her motor and mental development began to deteriorate and a diagnosis of non-specific psychomotor retardation and bilateral clubfoot was made by a child neurologist. The initial neurological deterioration was suspected to be related to measles infection. At the age of 6 years she was diagnosed as having lumbar scoliosis, with a shorter left leg. Her mental status was greatly impaired and she was transferred to a special school for the mentally handicapped. She was the eldest of three sisters, two of whom were unaffected. Her parents were second cousins.

On examination, she had multiple 2–10-mm red to blue-black papular and tuberous lesions affecting the right buttock and the flexor aspect of the right thigh (Fig. 1). Very few similar isolated lesions were seen on the upper chest. Some of the larger papules were hyperkeratotic. Individual lesions did not blanch with pressure. Her facial features were slightly coarse, with a broad face and macroglossia with a scrotal appearance (Fig. 2). No acne lesions were seen and she had no history of photosensitivity. Liver and spleen were not palpable. No ophthalmological abnormalities were detected. Cardiopulmonary function was normal. Neurological examination revealed an oligophrenic dementia, generalized hypotonia with joint laxity, hyporeflexia, bilateral clubfoot and dislalia. Routine laboratory data were normal except for the presence of many vacuolated lymphocytes in peripheral blood smears. Radiology demonstrated lumbar scoliosis with a shorter left leg and thickening of the cortex of the skull. Histopathological examination revealed numerous dilated, thin-walled, congested capillaries in the papillary dermis with an overlying mildly acanthotic epidermis with elongation of the rete ridges.

Urinary oligosaccharide screening was performed as follows: urine samples were adjusted to a creatinine content of 10 μg and spotted on to a precoated silica gel 60 thin-layer chromatography plate (Merck) and developed three times in butanol/acetic acid/water (2 : 1 : 1 by vol.).⁶ The plate was stained using orcinol reagent, which is a general stain for sugars. The chromatogram revealed abnormal excretion of oligosaccharides (Fig. 3).

Lysosomal enzyme assays were performed in cultured fibroblasts and leucocytes from the patient. Fibroblast cultures obtained from unaffected skin were

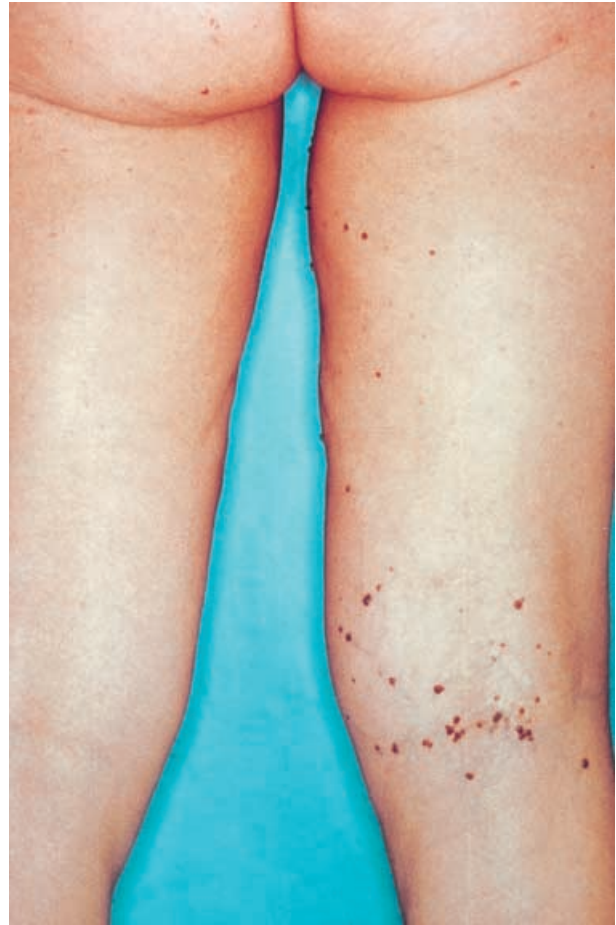

Figure 1. Angiokeratoma corporis diffusum affecting the right leg.

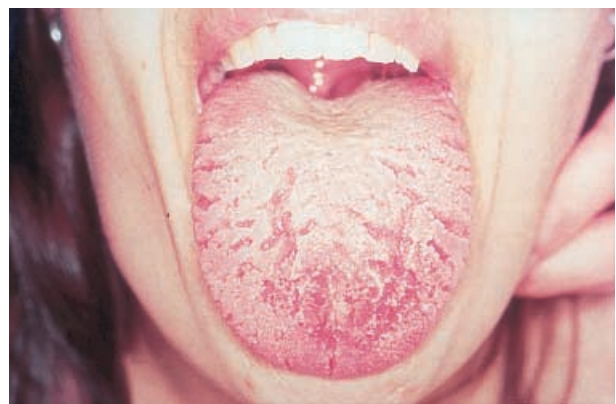

Figure 2. Macroglossia with a scrotal appearance.

established in Ham's F-10 medium according to routine procedures. Leucocytes were isolated according to Skoog and Beck.⁷ AGA activity was assayed with 1.5 mmol L⁻¹ L-aspartic acid- β -7-amido-methylcoum-

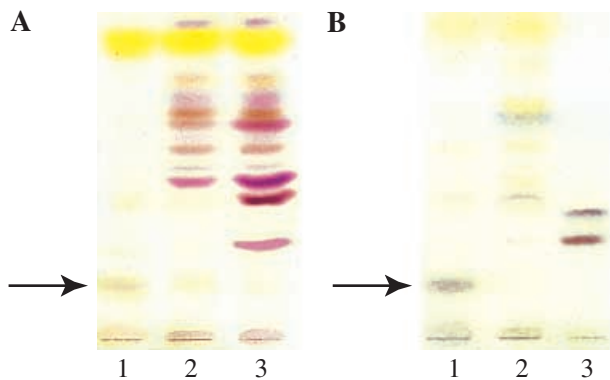


Figure 3. Thin-layer chromatography of urinary oligosaccharides. Lane 1, patient; lane 2, age-matched control; lane 3, control + glucose + lactose + raffinose + sialyl lactose. Plate was stained using the orcinol reagent, which stains sugars in general. Arrow indicates abnormal band.

arin in McIlvain's phosphate-citrate buffer at pH 6.5.⁸ Other lysosomal enzyme activities, i.e. α -*N*-acetylgalactosaminidase, α - and β -mannosidase, α -fucosidase, α - and β -galactosidase, neuraminidase and β -*N*-acetylglucosaminidase, were assayed in fibroblasts using appropriate 4-methylumbelliferyl derivatives as described elsewhere.⁹ These activities were all normal.

AGA activity was decreased to $0.185 \text{ nmol h}^{-1} \text{ mg}^{-1}$ protein (control mean \pm SD 18.9 ± 8.5) in the patient's cultured fibroblasts, and to $0.27 \text{ nmol h}^{-1} \text{ mg}^{-1}$ protein (control mean \pm SD 9.5 ± 1.2) in her leucocytes. Intermediate AGA activity levels in leucocytes from her parents (2.6 and $6.1 \text{ nmol h}^{-1} \text{ mg}^{-1}$ protein) confirmed heterozygosity for the mutant gene.

Four years later, in 1992, the patient developed a bipolar psychosis that was treated with lithium, a lithium-induced hypothyroidism and a polycystic ovarian disease requiring a left adnexectomy. By the age of 31 years, her cognitive skills were severely impaired, while cutaneous lesions of ACD had spread over the extensor and inner aspects of the right thigh, popliteal fossa and left buttock.

Discussion

ACD was initially considered to represent a unique and pathognomonic cutaneous feature of Fabry's disease. Subsequent reports of ACD have shown its association with six other well-known lysosomal storage diseases (adult-onset GM1 gangliosidosis,¹⁰ β -mannosidosis,^{11–13} fucosidosis type II,^{14,15} sialidosis type II,¹⁶ Kansaki disease^{17–19} and AGU^{4,5}) as well as in patients with normal enzyme activities.^{20–22} These metabolic disor-

ders are usually suspected on the basis of progressive neurological dysfunction, visceromegaly, skeletal dysostosis and other more specific phenotypic manifestations for each disease (see Table 1). To date, only four individuals, including the present patient, have been reported to develop ACD in association with AGU (Table 2).^{4,5}

The predominant clinical findings in our patient agree with those reported for AGU. Affected children are healthy for the first months of life, with hernias and recurrent infections appearing during the first year of life. Recurrent episodes of diarrhoea do not seem to be as frequent as previously thought. Our patient did not have this symptom. The disease becomes apparent later, with slowly progressive mental deterioration between the ages of 6 and 15 years, and with adult patients being severely or profoundly retarded. In a series of 43 Finnish children, the diagnosis of AGU was made by a child neurologist or paediatrician in most cases, with the most common suspicious symptoms being delayed speech and attention deficit.³ Aggression or other behavioural problems are not unusual, and one-third of patients with AGU have episodic psychiatric problems. However, mental retardation was not diagnosed in any patient before the diagnosis of AGU. Our patient presented with psychomotor retardation that was initially ascribed to neurological damage secondary to an infectious agent (i.e. measles virus), and she later developed a bipolar psychosis that required lithium therapy. As in our patient, typical facial features usually described as coarse facies are very mild in early childhood and more obvious thereafter. Thus, a high degree of awareness of the disease is mandatory for initial suspicion of a diagnosis, which is clearly established through demonstration of deficiency of AGA activity. Dysmorphic orofacial features that have been reported include macroglossia, dental malocclusions, limited mouth opening, small maxillary sinuses, thick lips, gingival hyperplasia, low nasal bridge and broad face.^{2,23,24} Other phenotypic features are multiple and variable in their presentation and include organomegaly, crystal-like lens opacities, skeletal dysplasia, cardiac valvular involvement and vacuolization of peripheral lymphocytes. In a recent review of 66 Finnish AGU patients, several cutaneous and mucosal lesions were reported to occur including angiokeratoma, facial angiofibromas, oral fibromatosis, leucokeratosis and acne lesions.²⁵ Our patient had polycystic ovarian disease, and her tongue was enlarged and had a scrotal appearance, two features that have not previously been described in the AGU

Table 1. Lysosomal storage disorders with angiokeratoma corporis diffusum

Disorder	Enzyme deficiency	Mental retardation	Organo-megaly	Dysostosis multiplex	Facial dysmorphism	Ocular signs	Haematological signs	Other
GM1 gangliosidosis	β -galactosidase	+/-	+/-	+/-	+	+/-	+	Mucopolysacchariduria
β -mannosidosis	β -mannosidase	+	-	Not usual	+	-	-	Hearing loss
Fucosidosis II	α -fucosidase	+	+	+	+	-	Vacuolated lymphocytes	Hearing loss, anhidrosis
Sialidosis II	Neuraminidase	+	-	+	Mild	+	Vacuolated lymphocytes	Myoclonus
Fabry's disease	α -galactosidase A	-	-	-	-	+	-	Neuropathy, thrombosis, hypohidrosis, cardiac, renal
Kanzaki disease	α -N-acetylgalactosaminidase	+	-	-	+	+	-	Hearing loss, neuropathy, cardiac
AGU	AGA	+	+	+	+	-	Vacuolated lymphocytes	Recurrent infections, hernia, acne, photosensitivity

AGU, aspartylglucosaminuria; AGA, aspartylglucosaminidase.

Table 2. Aspartylglucosaminuria patients with angiokeratoma corporis diffusum

Reference	Patient sex/age (years) at examination	Ethnic origin	Location of lesions
Gehler <i>et al.</i> ⁴	F/20	Italian	Left forearm
Yoshida <i>et al.</i> ⁵	F/41	Japanese	Hip and lower extremities
Yoshida <i>et al.</i> ⁵	M/45	Japanese	Trunk, lower extremities
Present case	F/19	Spanish	Buttocks, right leg

phenotype. In contrast, she had no history of acne lesions or photosensitivity, which have been described as part of the phenotype of AGU (Table 1).

More than 400 patients with lysosomal and peroxysomal storage diseases have been successfully treated with bone marrow transplantation (BMT). These diseases include globoid cell and metachromatic leucodystrophy, adrenoleucodystrophy, α -mannosidosis, fucosidosis, certain types of mucopolysaccharidosis and Gaucher disease.²⁶ Treatment involves the re-establishment of deficient enzymatic activity from a newly acquired monocyte/macrophage system in the recipient. In recent years there have been reports of BMT for treatment of AGU patients, with controversial results. Autti *et al.* reported two patients who demonstrated improvement in both myelination and other laboratory parameters (AGA activity and aspartylglucosamine in urine) after BMT.²⁷ In a more recent

report from Arvio *et al.*, two young patients of five who received BMT and were mentally retarded, became more severely mentally affected after a follow-up period of 7 and 5 years when compared with the non-transplanted group.²⁸ Enzyme replacement therapy with recombinant human AGA has recently been tested in a mouse model of AGU.²⁹ Quantitative biochemical analysis along with histological and immunohistochemical studies demonstrated a metabolic correction in non-neuronal tissues as well as in brain tissue. Although AGU mice serve as a good disease model for AGU, clinical manifestations seem to be milder and the life span normal, in contrast with humans with the disease who die at 35–45 years of age.³

As developmental expression of AGA in the brain appears to be highest during embryogenesis,³⁰ it seems plausible that any treatment involving either BMT or enzyme replacement therapy in AGU patients should be introduced at a very early age, before neurological damage has occurred. Screening to detect heterozygous carriers by enzymatic determination of AGA and prenatal diagnosis of at-risk pregnancies by enzyme analysis of cultured amniotic fluid cells or chorionic villus samples could be helpful in this sense. Further information will become available as the length of follow-up increases in AGU patients receiving treatments based on deficient enzyme activity replacement.

References

- 1 Pollitt RJ, Jenner FA, Merskey H. Aspartylglucosaminuria an inborn error of metabolism associated with mental defect. *Lancet* 1968; **ii**: 253–5.
- 2 Autio S. Aspartylglucosaminuria. Analysis of thirty-four patients. *J Ment Defic Res* 1972; **1**: 1–93.
- 3 Arvio M, Autio S, Louhiala P. Early clinical symptoms and incidence of aspartylglycosaminuria in Finland. *Acta Paediatr* 1993; **82**: 587–9.
- 4 Gehler J, Sewell AC, Becker C *et al.* Clinical and biochemical delineation of aspartylglycosaminuria as observed in two members of an Italian family. *Helv Paediatr Acta* 1981; **36**: 179–89.
- 5 Yoshida K, Ikeda SI, Yanagisawa N *et al.* Two Japanese cases with aspartylglycosaminuria: clinical and morphological features. *Clin Genet* 1991; **40**: 318–25.
- 6 Tsai MY, Marshall JG. Screening for urinary oligosaccharides and simple sugars by thin-layer chromatography. *Med Lab Sci* 1979; **36**: 85–90.
- 7 Skoog WA, Beck WS. Studies in the fibrinogen, dextran and phytohemagglutinin methods of isolating leukocytes. *Blood* 1956; **11**: 436–54.
- 8 Voznyi YA, Keulemans JLM, Kleijer WJ *et al.* Applications of a new fluorimetric enzyme assay for the diagnosis of aspartylglucosaminuria. *J Inher Metab Dis* 1993; **16**: 929–34.
- 9 Chabás A, Coll MJ, Aparicio M, Rodríguez Diaz E. Mild phenotypic expression of α -N-acetylgalactosaminidase deficiency in two adult siblings. *J Inher Metab Dis* 1994; **17**: 724–31.
- 10 Wenger DA, Sattler M, Mueller T *et al.* Adult GM1 gangliosidosis. *Clin Genet* 1980; **17**: 323–34.
- 11 Cooper A, Sarharwalla IB, Roberts MM. Human β -mannosidase deficiency. *N Engl J Med* 1986; **315**: 1231.
- 12 Cooper A, Hatton C, Thornley M, Sarharwalla IB. Human β -mannosidase deficiency: biochemical findings in plasma, fibroblasts, white cells and urine. *J Inher Metab Dis* 1988; **11**: 17–29.
- 13 Rodríguez-Serna M, Botella-Estrada R, Chabás A *et al.* Angiokeratoma corporis diffusum associated with β -mannosidase deficiency. *Arch Dermatol* 1996; **132**: 1219–22.
- 14 Patel V, Watanabe I, Zeman W. Deficiency of α -L-fucosidase. *Science* 1972; **176**: 420–7.
- 15 Epinnette WW, Norins AL, Drew AL *et al.* Angiokeratoma corporis diffusum with α -L-fucosidase deficiency. *Arch Dermatol* 1973; **107**: 754–7.
- 16 Miyatake T, Atsumi T, Obayashi T *et al.* Adult type neuronal storage disease with neuraminidase deficiency. *Ann Neurol* 1978; **6**: 232–44.
- 17 Kanzaki T, Yokota M, Irie F *et al.* Angiokeratoma corporis diffusum with glycopeptiduria due to deficient lysosomal α -N-acetylgalactosaminidase activity: clinical, morphologic, and biochemical studies. *Arch Dermatol* 1993; **129**: 460–5.
- 18 Keulemans JLM, Reuser AJJ, Kroos MA *et al.* Human α -N-acetylgalactosaminidase deficiency: new mutations and the paradox between genotype and phenotype. *J Med Genet* 1996; **33**: 458–64.
- 19 Kodama K, Kobayashi H, Abe R *et al.* A new case of α -N-acetylgalactosaminidase deficiency with angiokeratoma corporis diffusum, with Ménière's syndrome and without mental retardation. *Br J Dermatol* 2001; **144**: 363–8.
- 20 Holmes RC, Fensom AH, McKee P *et al.* Angiokeratoma corporis diffusum in a patient with normal enzyme activities. *J Am Acad Dermatol* 1984; **10**: 384–7.
- 21 Crovato F, Revora A. Angiokeratoma corporis diffusum and normal enzyme activities. *J Am Acad Dermatol* 1985; **12**: 885–6.
- 22 Calzavara-Pinton PG, Colombi M, Carlino A *et al.* Angiokeratoma corporis diffusum and arteriovenous fistulas with dominant transmission in the absence of metabolic disorders. *Arch Dermatol* 1995; **131**: 57–62.
- 23 Arvio P, Arvio M, Pirinen S. Characteristic dental arches and dental occlusion in patients with aspartylglucosaminuria. *J Craniofac Genet Dev Biol* 1997; **17**: 133–40.
- 24 Arvio P, Arvio M, Wolf J *et al.* Impaired oral health in patients with aspartyl glucosaminuria. *Oral Surg Oral Med Oral Pathol Oral Radiol Endod* 1998; **86**: 562–8.
- 25 Arvio P, Arvio M, Kero M *et al.* Overgrowth of oral mucosa and facial skin, a novel feature of aspartylglycosaminuria. *J Med Genet* 1999; **36**: 398–404.
- 26 Krivit W, Peters C, Shapiro EG. Bone marrow transplantation as effective treatment of central nervous system disease in globoid cell leukodystrophy, metachromatic leukodystrophy, adrenoleukodystrophy, mannosidosis, fucosidosis, aspartylglucosaminuria, Hurler, Maroteaux-Lamy, and Sly syndromes, and Gaucher disease type III. *Curr Opin Neurol* 1999; **12**: 167–76.
- 27 Autti T, Rapola J, Santavuori P *et al.* Bone marrow transplantation in aspartylglucosaminuria – histopathological and MRI study. *Neuropediatrics* 1999; **30**: 283–8.
- 28 Arvio M, Sauna-Aho O, Peippo M. Bone marrow transplantation for aspartylglucosaminuria: follow-up study of transplanted and non-transplanted patients. *J Pediatr* 2001; **138**: 288–90.
- 29 Dunder U, Kaartinen V, Valtonen P *et al.* Enzyme replacement therapy in a mouse model of aspartylglycosaminuria. *FASEB J* 2000; **14**: 361–7.
- 30 Uusitalo A, Tenhunen K, Heinonen O *et al.* Toward understanding the neuronal pathogenesis of aspartylglucosaminuria: expression of aspartylglucosaminidase in brain during development. *Mol Genet Metab* 1999; **67**: 294–307.