

Complete Superior and Inferior Sagittal Sinus Thromboses With Multiple Cranial Nerve Pareses and Transient Ischemic Attack

—Case Report—

Cahide TOPSAKAL, Mutlu CIHANGIROGLU*, Metin KAPLAN,
Ismail AKDEMIR, and Murat TIFTIKCI

*Departments of Neurosurgery and *Radiology, Firat University School of Medicine, Elazig, Turkey*

Abstract

A 27-year-old woman with headache and right peripheral facial nerve paresis persisting for over 25 days, and left hemiparesis for 2 days, which had all been gradually improving, was admitted to our hospital as she suddenly developed horizontal and vertical diplopia. She had right fourth and sixth cranial nerve pareses, papilledema, and right orbital venous congestion, and also experienced a seizure on the day of admission. Magnetic resonance (MR) imaging and MR venography revealed complete superior and inferior sagittal sinus thromboses and significant collateral venous channels, but no parenchymal lesion. Fourth and seventh cranial nerve pareses and the left hemiparesis resolved completely within 2 days, but she concurrently developed an episode of right hemiparesis, which lasted for 30 minutes. The patient recovered with medical therapy. MR venography showed recanalization of both sinuses. She was neurologically intact except for minimal right abducens nerve paresis at discharge, 40 days after admission. Multiple cranial nerve pareses with transient ischemic attack is an extremely rare manifestation of superior sagittal sinus thrombosis. Transient functional disturbance due to temporary reduction of tissue perfusion caused by overload of the collateral channels is more likely to be responsible for the transient ischemic attack and reversible ischemic neurological deficit.

Key words: cranial nerve paresis, reversible ischemic neurological deficit, sagittal sinus, sinus thrombosis, transient ischemic attack

Introduction

Dural sinus thrombosis is a rare but life-threatening pathology which requires special care for correct diagnosis and treatment. The clinical manifestations of superior sagittal sinus (SSS) thrombosis are non-specific but characterized by the symptoms of either isolated intracerebral hemorrhage (ICH), i.e., headache, papilledema, blurred vision,^{2,9,12,16)} or ICH symptoms together with seizures, focal deficits, progressive coma, and death.^{6,10,12,14)} Sporadic cases of cranial nerve pareses associated with SSS thrombosis are rare,^{1,4,6,15)} and only three cases with transient ischemic attack (TIA) have been reported since 1966.^{3,5)}

We describe a case of multiple cranial nerve pareses associated with TIA due to complete SSS

and inferior sagittal sinus thromboses.

Case Report

A 27-year-old woman with complaints of headache and right facial nerve paresis persisting for over 25 days, and left hemiparesis for 2 days, which had all been gradually improving, was admitted to our hospital on May 30, 2000 as she suddenly developed horizontal and vertical diplopia. On the same day, she suffered vomiting and generalized convulsion. Neurological examination found she was somnolent and disoriented (Glasgow Coma Scale score 9) with neck stiffness, right fourth, sixth, and mild seventh cranial nerve pareses, papilledema, right orbital venous congestion, and mild left hemiparesis (Fig. 1). Lumbar puncture revealed increased intracranial pressure (ICP) (31 cmH₂O) and xanthochromia. Computed tomography (CT) had previ-

Received January 18, 2002; Accepted June 8, 2002

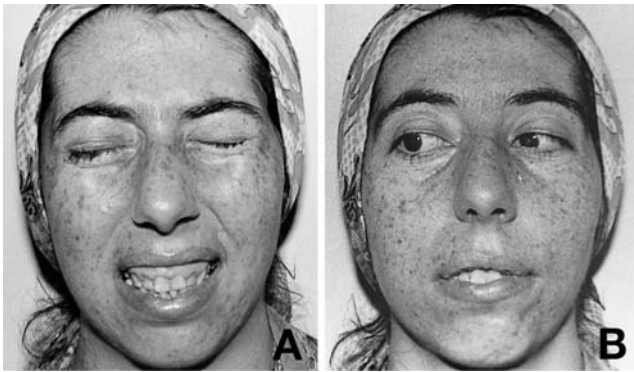

Fig. 1 Photographs showing peripheral facial (A) and abducens nerve pareses (B) on the right.

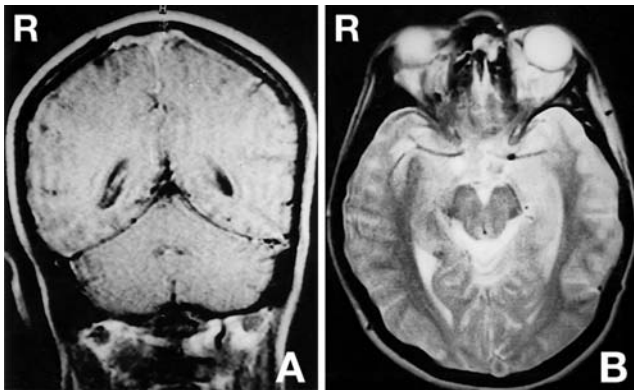


Fig. 2 Coronal T₁-weighted (A) and axial T₂-weighted (B) magnetic resonance images showing the signal changes consisted with indolent flow in the sagittal sinus.

ously been evaluated as normal, but magnetic resonance (MR) imaging on the day of admission revealed sagittal sinus thrombosis (Fig. 2). Carotid angiography and MR venography demonstrated complete SSS and inferior sagittal sinus thromboses and prominent collateral venous circulation (Fig. 3).

Fourth and seventh cranial nerve pareses and the left hemiparesis resolved completely within 2 days. However, she suffered an episode of right hemiparesis, which lasted for 30 minutes, and depression of consciousness, so she was monitored in the intensive care unit until she recovered within 3 days. Detailed hematological and biochemical profiles, including serum protein C, protein S, and anti-thrombin III levels, were investigated. Coagulation profiles and collagen assays were measured. Focal or systemic sepsis was excluded. Medical therapy included heparin and warfarin administration with repeated prothrombin time controls, anticonvulsant

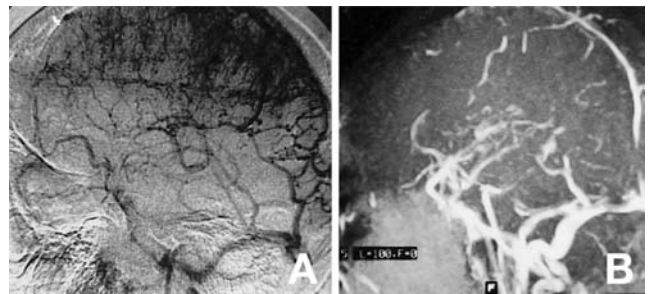


Fig. 3 Right carotid angiogram, venous phase (A) and magnetic resonance venogram (B) showing no filling of the superior and inferior sagittal sinuses, and dilation of the vein of Labbé and other anastomotic veins together with a large number of collateral veins.

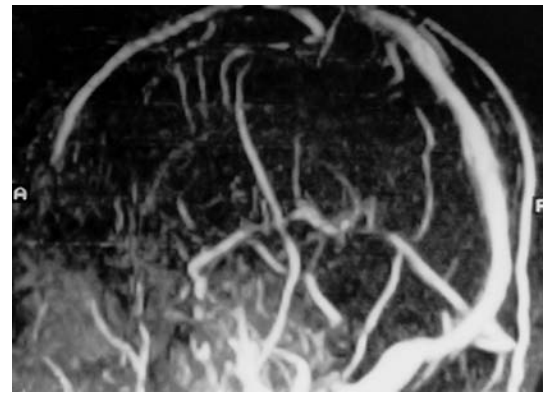


Fig. 4 Magnetic resonance venogram after treatment clearly showing both sagittal sinuses due to recanalization.

and isotonic hydration therapies, and cerebrospinal fluid (CSF) drainage by lumbar puncture.

MR venography 18 days later displayed good recanalization of both sinuses (Fig. 4). Lumbar puncture findings and CSF pressure were within the physiological ranges. She was neurologically intact except for minimal right abducens nerve paresis at discharge 40 days later.

Discussion

SSS thromboses are identified at autopsy in 50% of cases, and the mortality is 56%. Thromboses of large dural sinuses may be spontaneous or follow direct infection, either systemic or of the adjacent epidural or subdural spaces. Aseptic (primary) intracranial venous occlusive disease tends to favor unpaired sinuses and is associated with pregnancy and puer-

perium, malignancy, hypercoagulable state (thrombophilia), lupus erythematosus, Behçet's disease, familial Mediterranean fever, oral contraceptives, intracranial surgery, trauma, dehydration, cachexia, cardiac diseases, diabetes mellitus, and homocysteinuria.^{2,6,9,12} In our case, no etiological factor could be found. The ratio of women to men is 2:1. The mean age at the time of diagnosis was 27 years.¹⁴ Our female patient was also 27 years old.

Sinus thrombosis can only be identified by MR imaging, angiography, or MR venography. CT shows multiple irregular high dense foci mainly in the parietal lobes and the ventricular shift to one side, and the so-called "empty triangle" sign and gyral enhancement may be observed after administration of contrast medium.¹⁰ However, CT was not helpful in our case. MR imaging demonstrated the sinus thrombosis. Carotid angiography reveals delayed circulation, poor filling of the cortical veins, and absent or narrow SSS with a zigzag-shaped margin.¹⁰ In our case, the absence of both sagittal sinuses and presence of disseminated collateral venous circulation on angiography were confirmed by MR venography, which is the most reliable and noninvasive method for evaluating the venous sinuses.

Thromboses of the transverse and sigmoid sinuses are usually asymptomatic if the thrombosed sinus is nondominant or associated with rich collateral circulation.⁹ Furthermore, the clinical manifestation remains silent in chronic cases as good collateral venous circulation can develop. However, acute venous outflow obstruction leads to venous hypertension and resultant acute ICP increase. SSS thrombosis either occurs as isolated ICH, i.e., pseudotumor cerebri,^{2,9,12,16} which manifests as headache, papilledema, and/or blurred vision. The only presenting symptom in 53–66.7% of cases is persistent headache of variable duration, location, and severity.^{12,14} Papilledema occurs in 33% of cases,^{10–12,14} whereas visual loss in 25% of cases may progress to optic atrophy.^{12,14} CSF pressure usually increased to over 20 cmH₂O.² SSS thrombosis does not usually occur as isolated ICH, but manifests as seizures, focal deficits, progressive coma, and death (38%). Seizure is the second commonest sign (49%) after headache, which may progress to status epilepticus.^{12,14} In our patient, the headache suggestive of ICH preceded the focal neurological disturbance by 1–3 days.¹² Hemiparesis, quadriparesis, or paraparesis is the third most common symptom (19–48%).^{6,10,12,14}

SSS occlusion alone will not cause cranial nerve findings except for visual obscuration and abducens nerve paresis due to increased ICP. Thus, the clinical findings may be due to increased ICP. Pseu-

dotumor cerebri is known to be associated with ocular motility deficits, most commonly sixth cranial nerve paresis as a false-localizing sign.^{1,10} Very seldom fourth cranial nerve paresis¹⁵ and facial nerve involvement^{1,4,6} have been reported as false-localizing signs. In our case, fourth, sixth, and seventh cranial nerve pareses occurred together and were reversible. Fourth cranial nerve paresis was a reversible ischemic neurological deficit (RIND) which lasted for 2 days. The right hemiparesis lasted 30 minutes occurred as a TIA.

Fourth, sixth, and seventh cranial nerve pareses are individually reported to be false-localizing signs of intracranial hypertension. However, multiple cranial nerve pareses are hard to attribute only to intracranial hypertension. Venous thrombosis reduces the venous outflow from the brain and diminishes the effective blood flow to the involved area. Such venous engorgement causes white matter edema. The increased venous pressure may also cause hemorrhage. These processes may all contribute to ICP increase, but focal findings can be expected due to edema, hemorrhage, and/or venous infarction. In our patient, no edema, infarction, or hemorrhage could be identified, with the xanthochromic blood providing only evidence of minimal hemorrhage. The more likely mechanism of RIND and TIA in this patient is thought to be a transient functional disturbance due to a temporary reduction of tissue perfusion caused by the overload of the collateral channels.⁵

A better outcome can be achieved with earlier diagnosis and treatment, particularly in patients with identifiable disorders causing SSS thrombosis, as well as thrombosis with relatively minimal extension.¹⁴ Systemic heparin administration remains the best treatment. Hydration with intravenous administration of isotonic fluids should be maintained to avoid an increase in ICH. If the presentation is delayed, treatment with acetazolamide and nonsteroid anti-inflammatory drugs, and lumbar puncture (possibly shunt placement) can avoid the ophthalmologic complications of pseudotumor cerebri.⁹ Papilledema and visual disturbances should improve immediately after venous drainage is established from the retina and head of the optic nerve. If the diagnosis is established shortly after the thrombosis occurs, direct endovascular thrombolysis with urokinase, streptokinase, or tissue plasminogen activator may be the best therapeutic option but should only be considered in a selective group of patients, probably those worsening under medical therapy.^{7,8,13} Long-term treatment after resolution of the acute phase consists of heparin and/or warfarin for over 3–6 months. In our case, no

surgical intervention was needed since almost complete cure was achieved with medical therapy.

References

- 1) Bakshi SK, Oak JL, Chawla KP, Kulkarni SD, Apte N: Facial nerve involvement in pseudotumor cerebri. *J Postgrad Med* 38: 144-145, 1992
- 2) Biousse V, Ameri A, Bousser MG: Isolated intracranial hypertension as the only sign of cerebral venous thrombosis. *Neurology* 53: 1537-1542, 1999
- 3) Bousser MG, Chiras J, Bories J, Castaigne P: Cerebral venous thrombosis: a review of 38 cases. *Stroke* 16: 199-213, 1985
- 4) Capobianco DJ, Brazis PW, Cheshire WP: Idiopathic intracranial hypertension and seventh nerve palsy. *Headache* 37: 286-288, 1997
- 5) Chang DI, Yoon SS, Chung KC: Superior sagittal sinus thrombosis and transient ischemic attacks: possible mechanism. *J Korean Med Sci* 13: 566-568, 1998
- 6) Dickins JR, Graham SS: Neurotologic presentation of sagittal sinus thromboses associated with oral contraceptive usage. *Am J Otol* 14: 544-547, 1993
- 7) Di Rocco C, Iannelli A, Leone G, Moschini M, Valori VM: Heparin-urokinase treatment in aseptic dural sinus thrombosis. *Arch Neurol* 38: 431-435, 1981
- 8) Horowitz M, Purdy P, Unwin H, Cartens G, Greenlee R, Hise J, Kopitnik T, Batjer H, Rollins N, Samson D: Treatment of dural sinus thrombosis using selective catheterization and urokinase. *Ann Neurol* 38: 58-67, 1995
- 9) Keiper GL, Sherman JD, Tomsick TA, Tew JM: Dural sinus thrombosis and pseudotumor cerebri: unexpected complications of suboccipital craniotomy and translabyrinthine craniectomy. *J Neurosurg* 91: 192-197, 1999
- 10) Kubota C, Kawamura Y, Yamanouchi Y, Kurimoto T, Morita K, Matsumura H: [A case report of superior sagittal sinus thrombosis — evaluation of computed tomographic findings in diagnosis and comprehension of this sinus thrombosis]. *No Shinkei Geka* 9: 961-966, 1981 (Jpn, with Eng abstract)
- 11) Mohamed A, McLeod JG, Hallinan J: Superior sagittal sinus thrombosis. *Clin Exp Neurol* 28: 23-36, 1991
- 12) Najim al-Din AS, Mubaidin A, Wriekat AL, Alqam M: Risk factors of aseptic intracranial venous occlusive disease. *Acta Neurol Scand* 90: 412-416, 1994
- 13) Perkin GD: Cerebral venous thrombosis: Developments in imaging and treatment. *J Neurol Neurosurg Psychiatry* 59: 1-3, 1995
- 14) Schell CL, Rathe RJ: Superior sagittal sinus thrombosis. Still a killer. *West J Med* 149: 304-307, 1988
- 15) Speer C, Pearlman J, Phillips PH, Cooney M, Repka MX: Fourth cranial nerve palsy in pediatric patients with pseudotumor cerebri. *Am J Ophthalmol* 127: 236-237, 1999
- 16) Thron A, Wessel K, Linden D, Schroth G, Dichgans J: Superior sagittal sinus thrombosis: neuroradiological evaluation and clinical findings. *J Neurol* 233: 283-288, 1986

Address reprint requests to: C. Topsakal, M.D., Department of Neurosurgery, Firat University School of Medicine, 23100, Elazig, Turkey.
e-mail: cdtopsakal@yahoo.com.