

## Case Report

# Transfemoral, Transvenous Embolisation of Dural Arteriovenous Fistula Involving the Isolated Transverse-Sigmoid Sinus from the Contralateral Side

M. Komiyama<sup>1</sup>, T. Ishiguro<sup>1</sup>, Y. Matsusaka<sup>1</sup>, T. Yasui<sup>1</sup>, and A. Nishio<sup>2</sup>

<sup>1</sup>Department of Neurosurgery, Osaka City General Hospital, Osaka, Japan

<sup>2</sup>Department of Neurosurgery, Osaka City University Hospital, Osaka, Japan

Published online October 10, 2002

© Springer-Verlag 2002

## Summary

**Background.** A dural arteriovenous fistula (AVF) involving the transverse-sigmoid (T-S) sinus which is occluded at its proximal and distal ends i.e., an isolated sinus, runs the risk of haemorrhaging or causing serious neurological deficits as a result of its retrograde leptomeningeal venous drainage. While lesions of this type have not been considered to be treatable by percutaneous, transvenous embolisation, this paper challenges this view.

**Case Presentation.** Two middle-aged men with dural AVFs involving the isolated left T-S sinus presented with motor aphasia due to focal brain edema or haemorrhage. Under local anaesthesia, transfemoral, transvenous embolisation was performed with a microcatheter that was passed through the occluded proximal transverse sinus from the right (contralateral) side. The isolated sinus was then occluded with platinum coils. This embolisation resulted in angiographic and clinical cure of dural AVFs in both patients.

**Interpretation.** Transfemoral, transvenous embolisation is a therapeutic alternative for the treatment of dural AVFs involving the isolated T-S sinus. Embolisation obviates the need for craniotomy and general anaesthesia, which are required for the established modes of treatment, i.e., direct surgery or direct percutaneous sinus packing.

**Keywords:** Dural arteriovenous fistula; isolated sinus; transfemoral approach; transvenous embolisation; transverse-sigmoid sinus.

## Introduction

Patients with dural arteriovenous fistulas (AVFs) involving the transverse-sigmoid (T-S) sinuses may present with subjective pulse-synchronous tinnitus, bruit, insomnia, headache, visual decline, seizure, and/or altered mental status, including dementia. Dural AVFs can also result in life-threatening brain edema,

haemorrhage, and venous infarction [6, 9, 12, 15–17, 19, 20, 22, 23]. Those with a retrograde leptomeningeal venous drainage are regarded as high-risk, having the potential to haemorrhage and result in serious neurological complications requiring urgent treatment [1, 3, 4, 6, 17].

Endovascular treatment of dural AVFs may employ either a transarterial or transvenous approach [7, 13, 14, 18–21, 23]. In dural AVFs with dural sinus occlusion at the proximal and distal ends, i.e., an isolated sinus, a transvenous approach is hampered by the occlusion of the sinus, making catheter navigation nearly impossible [3, 9, 12]. We herein report transfemoral, transvenous embolisation of an isolated sinus from the “contralateral” side in 2 patients, resulting in clinical and angiographic cure. To our knowledge, use of a “contralateral” transvenous approach has not been previously reported.

## Case Presentation

### Case 1

A 50-year-old man developed transient ischaemic attacks of motor aphasia three times within the span of 4 days. Each episode lasted about 10 minutes and was followed by complete recovery. Coincident with aphasia, the patient experienced occipitalgia. Patient and family histories were unremarkable. The patient had no neurological deficits at admission, and was not experiencing tinnitus or bruit. Magnetic resonance imaging (MRI) showed a long T1 and T2 lesion in the left temporo-occipital region consistent with focal brain edema and flow void on the cortical surface near the lesion. Digital subtraction angiography (DSA) demonstrated a dural AVF involving

the isolated left T-S sinus with a retrograde leptomeningeal venous drainage (Cognard Type IIb, Boden Type III). (Fig. 1a, b). The feeding arteries were the left occipital artery, the neuromeningeal branch of the left ascending pharyngeal artery, the posterior branch of the left middle meningeal artery, and the left anterior and posterior auricular arteries.

Prior to the scheduled transvenous embolisation, marked reduction of the arteriovenous (AV) shunts was obtained by transarterial embolisation using polyvinyl alcohol particles and platinum coils. This transarterial embolisation might facilitate subsequent transvenous embolisation or percutaneous direct packing through a burr hole in case of the failure of transvenous embolisation. Six days later, transfemoral, transvenous embolisation through the right jugular vein to the isolated left T-S sinus was performed. Initially, a double coaxial catheter system (a RapidTransit infusion catheter, Cordis, Miami, FL) and a 7-F Guider Softip guiding catheter (Boston Scientific, Natick, MA) failed to navigate the microcatheter into the isolated sinus due to lack of pushability. We then used a triple coaxial catheter system, employing a RapidTransit infusion catheter, a Tracker-38 infusion catheter with a shaft length of 120 cm (Boston Scientific), and a 7-F Guider Softip guiding catheter. Placing the tips of the Tracker-38 catheter at the torcular herophili and the guiding catheter at the right jugular foramen, a RapidTransit infusion catheter was penetrated into the occluded proximal side of the left transverse sinus, and navigated into the isolated T-S sinus using a GT-guidewire (0.016-inch, Terumo, Tokyo, Japan). (Fig. 1c, d). The isolated sinus was completely packed with 205 cm of Soft Detach-18 coils (Cook, Bjæverskov, Denmark). (Fig. 1e). No AV shunt was visible on the final DSA. (Fig. 1f). The patient's neurological status remained normal. An MRI obtained 1 month later revealed no brain edema or signal void, nor any abnormalities. At the last follow-up at 1 year, the patient remained neurologically normal.

#### Case 2

A 63-year-old man developed chemosis of the right eye and tinnitus on the left side. Patient and family histories were unremarkable. At the initial admission, the patient was neurologically normal except for mild hypalgesia in the territory of the right trigeminal nerve and slight redness of the right eye. A weak bruit synchronous with the heartbeat was audible over the left retromastoid area. The patient's MRI was normal and no apparent cortical flow void was observed. DSA revealed two independent dural AVFs involving the right cavernous sinus (Barrow type D) and the left T-S sinus. The T-S sinus was occluded at its distal end, but its proximal end was open (Cognard Type IIa, Boden Type I). The dural AVF of the cavernous sinus was treated by staged transarterial and transvenous embolisation through the right inferior petrosal sinus and cured angiographically and clinically. The patient's right ocular sign rapidly disappeared. The dural AVF of the left T-S sinus was treated by transarterial embolisation using polyvinyl alcohol particles because symptoms were mild and the normal cerebral venous return from the left temporal lobe drained into the left T-S sinus.

One year later, the patient suddenly developed additional symptoms. At the second admission, the patient was alert and presented with moderate motor aphasia, but without hemiparesis. Computed tomography showed a fresh haematoma in the left posterior temporal lobe. A dural AVF at the cavernous sinus was not demonstrated on DSA but a persistent dural AVF involving the left T-S sinus was revealed. (Fig. 2a, b). This time, the left T-S sinus, now being occluded not just at its distal but also its proximal end, was an isolated sinus and all shunted flow was directed to the cortical veins (Cognard Type IIb, Boden Type III). The feeding arteries were both occipital arteries, the posterior branch of the left middle meningeal artery, the

left anterior and posterior auricular arteries, and the neuromeningeal branch of the left ascending pharyngeal artery. The patient was treated by staged transarterial and transvenous embolisation as in Case 1. A transfemoral, transvenous approach was performed under local anaesthesia 6 days following transarterial embolisation using polyvinyl alcohol particles and platinum coils. The tip of a 6-F Guider Softip guiding catheter was placed at the right jugular foramen. A 0.035-inch Radifocus guidewire (Terumo, Tokyo, Japan) was then introduced into the isolated sinus from the midline, and a RapidTransit infusion catheter was navigated into the isolated left T-S sinus using a 0.016-inch GT-guidewire. (Fig. 2c, d). The isolated sinus was completely occluded with multiple platinum coils (Interlocking detachable coils, Guglielmi detachable coils, and fibred coils, Boston Scientific). DSA at the end of the procedure failed to reveal a dural AVF at the left T-S sinus. (Fig. 2e). The patient's aphasia improved gradually, and had disappeared completely by the last follow-up at 1 year and 2 months.

## Discussion

Cognard *et al.* [4] and Boden *et al.* [3] modified the original classification of intracranial dural AVFs by Djindjian and Merland [8] according to their venous drainage patterns. Cognard *et al.* [4] classified the intracranial dural AVFs into five types as follows: type I, located in the main sinus, with antegrade flow; type II, in the main sinus, with flux into the sinus (IIa), cortical veins (IIb), or both (IIa + b); type III, with direct cortical venous drainage without venous ectasia; type IV, with direct cortical venous drainage with venous ectasia; and type V, with spinal venous drainage. Boden *et al.* [3] classified them simply into three types as follows: type I, drainage directly into dural venous sinuses or meningeal veins; type II, drainage into dural sinuses or meningeal veins as well as retrograde drainage into subarachnoid veins; and Type III, drainage solely into subarachnoid veins. Dural AVFs involving the isolated sinus are classified as being of the Cognard type IIb, though their retrograde leptomeningeal venous drainage pattern is more reminiscent of types III and IV. In the Boden classification, they are classified as type III. The Boden classification is more satisfactory than the Cognard one because of its simplicity and anatomico-clinical correlation [6].

Treatment options for dural AVFs involving the T-S sinus include intermittent occipital artery compression [14], transarterial embolisation [7, 14, 18, 20], transvenous embolisation [7, 13, 19–21, 23], percutaneous direct packing of the sinus [9, 12, 19, 23], glue injection after surgical exposure of the feeding arteries or draining veins [2], surgical interruption of the draining veins [5], removal or isolation of the T-S sinus [2, 12, 19, 20, 22], and stereotactic radiosurgery [10]. Manual

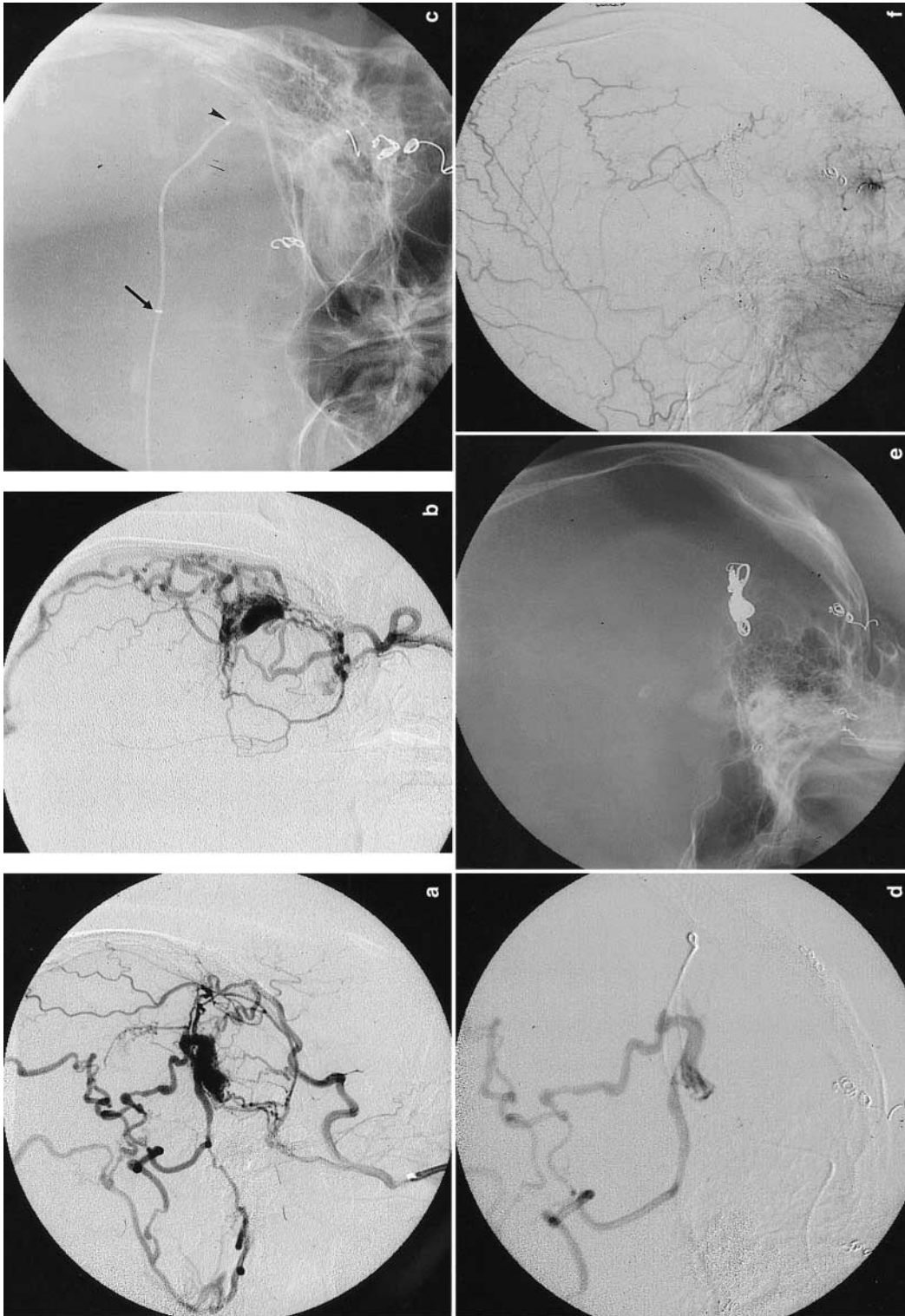


Fig. 1. Case 1: A 50-year-old man presenting with transient ischaemic attacks of motor aphasia due to brain edema in the left temporo-occipital region. Pre-embolisation left occipital artery injection (A: lateral view, B: frontal view) shows a dural AVF involving the left isolated transverse-sigmoid sinus. Venous drainage is solely retrograde and leptomeningeal. Plain x-ray film (C: frontal view) shows transfemoral, transvenous catheterisation to the isolated sinus with a microcatheter traversing through the torcular Herophili and occluded proximal transverse sinus. The arrow indicates the tip of the Tracker-38 catheter and the arrowhead indicates the tip of the microcatheter. Sinography (D: lateral view) shows a leptomeningeal venous drainage. Post-embolisation plain x-ray film (E: lateral view) shows the deposited coils. Post-embolisation left external carotid injection (F: lateral view) fails to show the dural AVF

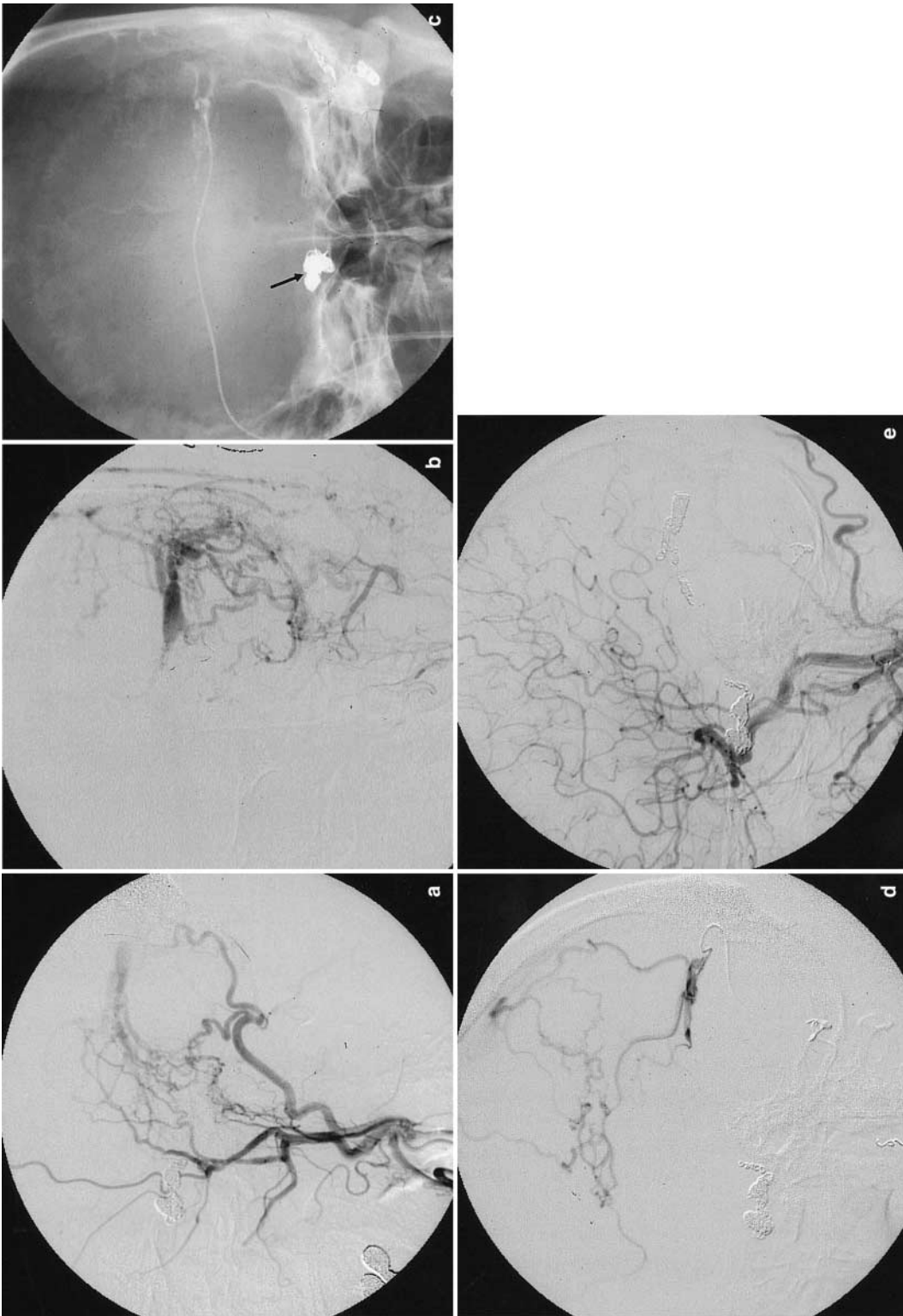


Fig. 2. *Case 2:* A 63-year-old man presenting with motor aphasia due to left temporo-occipital haemorrhage. Pre-embolisation left common carotid artery injection (a) lateral view, (b) frontal view – shows a dural AVF involving the left isolated transverse-sigmoid sinus. Venous drainage is solely retrograde and leptomeningeal. Plain x-ray film (c) frontal view – shows transvenous catheterisation to the isolated sinus with a microcatheter traversing through the torcular Herophili. The arrow indicates the coils previously deposited during the treatment of the dural carotid-cavernous sinus fistula. Sinography (d) lateral view – shows a retrograde leptomeningeal venous drainage. Post-embolisation left external carotid injection (e) lateral view – fails to show the dural AVF

compression of the occipital artery is a less reliable treatment than the others [14]. Transarterial embolisation with coils and particles is useful in reducing AV shunts but it is less likely to achieve clinical cure. Only when liquid embolic materials occlude the AV shunts properly, is clinical cure obtained. Since complete obliteration of the AV shunts with glue is not always possible, recanalisation and collateralisation may occur [14, 18, 20, 23]. Direct coil packing requires general anaesthesia with intra-operative DSA equipment [9, 12]. Surgical removal and isolation of the involved sinus are sometimes complicated by profuse intra-operative bleeding [22]. Radiosurgery requires a fairly long time to be effective during which high-risk patients are predisposed to haemorrhage and/or infarction. For this reason, radiosurgery alone is not a first-line treatment modality [3, 10]. Transarterial embolisation following radiosurgery may provide immediate symptom relief and may be effective during the latency period of radiosurgery [10].

We commonly use a local anaesthetic for transvenous coil embolisation in the treatment of dural AVFs. We did not find any differences in safety between the treatment of the dural AVFs involving the isolated and non-isolated T-S sinuses. Thus, transfemoral, transvenous coil embolisation requires neither general anaesthesia nor craniotomy. Patients with a dural AVF involving the distally occluded T-S sinus were successfully treated using contralateral transvenous approach [12, 13, 23]. Theoretically, an isolated sinus cannot be accessed transvenously unless the occluded portion of the sinus is penetrated or recanalised. To date, this procedure has not been successful [18] except for Gobin *et al.* [11] and Naito *et al.* [19] who did report successful use of the “ipsilateral” transvenous approach. In this report, we described the performance of the “contralateral” approach to the isolated sinus through the torcular Herophili in 2 patients. Gobin *et al.* [11] were initially unsuccessful in introducing a microcatheter into the isolated T-S sinus using the ipsilateral approach. However, they were able to introduce a 5-F diagnostic catheter with a 0.035-inch guidewire (Terumo) directly into the isolated sinus, aided by a 5-F vascular sheath, using the transjugular approach. Nonetheless, the transjugular approach is not without risk. In fact, Urtasun *et al.* [23] reported proximal perforation of the wall of the sigmoid sinus and extravasation of the contrast agent using this approach, though fortunately without clinical consequence. Naito *et al.* [19] were successful using

the transfemoral, transvenous “ipsilateral” approach in four of five patients, but they thought this approach was not suitable for the isolated sinus far from the jugular bulb. In this situation, the “contralateral” transvenous approach is the attractive alternative.

In Case 1, we used a triple co-axial catheter system employing a Tracker-38 catheter which allowed for stable microcatheter navigation in the intracranial dural sinus, and which facilitated the introduction of the microcatheter into the isolated sinus from the contralateral side. Embolic materials used in the transvenous approach include platinum coils and/or liquid glue, though the latter may cause venous infarction as a result of its migration into the cortical veins unless properly injected [13]. The recently developed mechanically or electrically detachable platinum coils are perhaps the most suitable coils for sinus packing at the present time.

In conclusion, we demonstrated that transfemoral, transvenous embolisation from the contralateral side can be an effective treatment for a dural AVF involving the isolated T-S sinus. The fact that the procedure requires neither general anaesthesia nor surgery further supports this approach as an alternative therapeutic option.

## References

1. Awad IA, Little JR, Akrawi WP, Ahl J (1990) Intracranial dural arteriovenous malformations: factors predisposing to an aggressive neurological course. *J Neurosurg* 72: 839–850
2. Barnwell SL, Halbach VV, Higashida RT, Hieshima G, Wilson CB (1989) Complex dural arteriovenous fistulas. Results of combined endovascular and neurosurgical treatment in 16 patients. *J Neurosurg* 71: 352–358
3. Borden JA, Wu JK, Shucart WA (1995) A proposed classification for spinal and cranial dural arteriovenous fistulous malformations and implications for treatment. *J Neurosurg* 82: 166–179
4. Cognard C, Gobin YP, Pierot L, Bailly AL, Houdart E, Casasco A, Chiras J, Merland JJ (1995) Cerebral dural arteriovenous fistulas: clinical and angiographic correlation with a revised classification of venous drainage. *Radiology* 194: 671–680
5. Collice M, D’Aliberti G, Talamonti G, Branca V, Boccardi E, Scalfa G, Versari PP (1996) Surgical interruption of leptomeningeal draining as treatment for intracranial dural arteriovenous fistulas without dural sinus drainage. *J Neurosurg* 84: 810–817
6. Davies MA, TerBrugge K, Willinsky R, Coyne T, Saleh J, Wallace MC (1996) The validity of classification for the clinical presentation of intracranial dural arteriovenous fistulas. *J Neurosurg* 85: 830–837
7. Dawsen RC, Joseph GJ, Owens DS, Barrow DL (1998) Transvenous embolization as the primary therapy for arteriovenous fistulas of the lateral and sigmoid sinuses. *AJNR* 19: 571–576
8. Djindjian R, Merland JJ (1978) Super-selective arteriography

- of the external carotid artery. Springer, Berlin Heidelberg New York Tokyo, pp 405–406
9. Endo S, Kuwayama N, Takaku A, Nishijima M (1998) Direct packing of the isolated sinus in patients with dural arteriovenous fistulas of the transverse-sigmoid sinus. *J Neurosurg* 88: 449–456
  10. Friedman JA, Pollock BE, Nichols DA, Gorman DA, Foote RL, Stafford SL (2001) Results of combined stereotactic radiosurgery and transarterial embolization for dural arteriovenous fistulas of the transverse and sigmoid sinuses. *J Neurosurg* 94: 886–891
  11. Gobin YP, Houdart E, Rogopoulos A, Casasco A, Bailly AL, Merland JJ (1993) Percutaneous transvenous embolization through the thrombosed sinus in transverse sinus dural fistula. *AJNR* 14: 1102–1105
  12. Goto K, Sidipratomo P, Ogata N, Inoue T, Matsuno H (1999) Combined endovascular and neurosurgical treatments of high-risk dural arteriovenous fistulas in the lateral and the confluence of the sinuses. *J Neurosurg* 90: 289–299
  13. Halbach VV, Higashida RT, Hieshima GB, Mehringer CM, Hardin CW (1989) Transvenous embolization of dural fistulas involving the transverse and sigmoid sinuses. *AJNR* 10: 385–392
  14. Halbach VV, Higashida RT, Hieshima GB, Goto K, Norman D, Newton TH (1987) Dural fistulas involving the transverse and sigmoid sinuses: results of treatment in 28 patients. *Radiology* 163: 443–447
  15. Houser OW, Baker HL, Rhoton AL, Okazaki H (1972) Intracranial dural arteriovenous malformations. *Radiology* 105: 55–64
  16. Ishii K, Goto K, Ihara K, Hieshima GB, Halbach VV, Bentson JR, Shirouzu T, Fukumura A (1987) High-risk dural arteriovenous fistulas of the transverse and sigmoid sinuses. *AJNR* 8: 1113–1120
  17. Lalwani AK, Dowd CF, Halbach VV (1993) Grading venous restrictive disease in patients with dural arteriovenous fistulas of the transverse/sigmoid sinus. *J Neurosurg* 79: 11–15
  18. Nakahara I, Pile-Spellman J, Hacin-Bey L, Crowell RM, Gress D (1993) Posterior fossa dural arteriovenous fistula with isolated sinus segment. *No To Shinkei* 45: 703–709 (in Japanese)
  19. Naito I, Iwai T, Shimaguchi H, Suzuki T, Tomizawa S, Negishi M, Sasaki T (2001) Percutaneous transvenous embolisation through the occluded sinus for transverse-sigmoid dural arteriovenous fistulas with sinus occlusion. *Neuroradiology* 43: 672–676
  20. Olteanu-Nerbe V, Uhl E, Steiger HJ, Yousry T, Reulen HJ (1997) Dural arteriovenous fistulas including the transverse and sigmoid sinuses: results of treatment in 30 cases. *Acta Neurochir (Wien)* 139: 307–318
  21. Roy D, Raymond J (1997) The role of transvenous embolization in the treatment of intracranial dural arteriovenous fistulas. *Neurosurgery* 40: 1133–1144
  22. Sundt TM, Piepgras DG (1983) The surgical approach to arteriovenous malformations of the lateral and sigmoid sinuses. *J Neurosurg* 59: 32–39
  23. Urtasun F, Biondi A, Casasco A, Houdart E, Caputo N, Aymard A, Merland JJ (1996) Cerebral dural arteriovenous fistulas: percutaneous transvenous embolization. *Radiology* 199: 209–217

### Comment

The authors present two interesting cases of dural arteriovenous fistulas of the transverse-sigmoid sinus with a proximal and distal sinus occlusion. In both cases it was still possible to achieve transvenous cure by using a contralateral approach, thus cannulating the isolated segment from the midline. This paper is an interesting contribution to the growing body of evidence that transvenous solutions for dural arteriovenous fistulas are the treatment of first choice. These case illustrations suggest that even in apparently very difficult conditions, transvenous cure can be achieved. None-the-less, it is certainly too early to make a conclusive statement with regard to risk and expectations of this kind of treatment. The authors point out that catheterization of an isolated segment is certainly not without risk and has the inherent risk of sinus wall perforation.

*H. J. Steiger*

Correspondence: Masaki Komiyama, M.D., Department of Neurosurgery, Osaka City General Hospital, 2-13-22, Miyakojima-Hondori, Miyakojima, Osaka 534-0021 Japan.