

Clinical study

Cranioplasty for patients with severe depressed skull bone defect after cerebrospinal fluid shunting

Chun-Chih Liao MD, Ming-Chien Kao MD DMSc

Division of Neurosurgery, Department of Surgery, National Taiwan University Hospital, Taipei, Taiwan

Summary Cranioplasty is indicated for patients with a skull bone defect. Patients may achieve subjective and objective improvements after cranioplasty. Some patients with severe brain swelling treated with decompressive craniectomy may develop hydrocephalus associated with severe brain bulging or even herniation via the skull bone defect. Consequently, these patients require a ventriculoperitoneal (V-P) shunt to relieve hydrocephalus. However, after shunting for hydrocephalus, they may develop severe sinking at the skull defect. Subsequently, when doing a cranioplasty for such a depressed defect, it may result in the dysfunction of the underlying brain, or even hematoma formation due to the large dead space. In this study, we advocate a temporary procedure to occlude the V-P shunt tube to allow the expansion of a depressed scalp flap to facilitate the subsequent cranioplasty. We report four patients with severe depression of the skull defect resulting from previous traumatic brain swelling followed by decompressive craniectomy and V-P shunting for communicating hydrocephalus. A simple subcutaneous clipping of the shunt tube was performed to allow the expansion of the depressed scalp to obliterate the dead space before the cranioplasty. All four patients obtained a satisfactory result without complications and achieved good functional recovery. A temporary occlusion of the shunt tube with an aneurysm clip before cranioplasty for patients with a severely depressed scalp flap is a simple and useful procedure. This procedure can safely and effectively eliminate the dead space between the skull plate and the dura to facilitate the cranioplasty, and thus prevent the potential complication of intracranial hematoma. © 2002 Elsevier Science Ltd. All rights reserved.

Keywords: cranioplasty, craniectomy, depressed skull bone defect, ventriculoperitoneal shunt

INTRODUCTION

Cranioplasty is indicated for patients with a skull bone defect. The patient may achieve some beneficial effects after the cranioplasty. In clinical practice, decompressive craniectomy is often needed for intractable intracranial hypertension due to severe brain swelling in patients suffering from serious head injury, stroke, or post-brain surgery complications. However, some of these patients may develop persistent bulging of the brain or even herniation through the craniectomy site, particularly when associated with the development of communicating hydrocephalus. Therefore, they require cerebrospinal fluid (CSF) shunting treatment. In most patients, the bulging craniectomy area may become extremely depressed after shunting due to the decrease in ventricular size and post-traumatic brain atrophy or parenchymal loss.

There is a potential risk of developing an intracranial hematoma as a complication in performing cranioplasty for such patients with severe depressed skull defects. In order to prevent this complication, we advocated an adjuvant procedure to expand the depressed craniectomy area via temporary occlusion of the ventriculoperitoneal (V-P) shunt tube prior to performing the cranioplasty. After the accomplishment of cranioplasty, the occluded shunt tube is released. We reported four patients with such clinical conditions, who were treated by this adjuvant procedure before cranioplasty and obtained

smooth and satisfactory results without complications of epidural or subdural hematoma. The clinical courses and the procedures of the temporary shunt occlusion and cranioplasty are presented. The usefulness of this adjuvant procedure is emphasized.

CASE REPORTS

Case 1

This 28-year-old male sustained an acute epidural hematoma after a motor vehicle accident. An emergency left fronto-temporal craniectomy for hematoma evacuation was done at a local hospital. Postoperatively, he regained consciousness but with right hemiplegia and aphasia. A V-P shunt was performed for hydrocephalus 3 months after the injury, and the bulged craniectomy site, 10 × 10 cm in size, became depressed (Fig. 1). He underwent shunt revision due to ventriculitis in the subsequent course and the craniectomy site became very depressed. A cranioplasty with bone cement and wire mesh was performed 5 months later. Unfortunately, he became disoriented soon after the cranioplasty. A computed tomographic (CT) scan revealed that there was a complication of epidural and subdural hemorrhage. An emergency operation to remove the bone cement plate and the underlying hematoma was done. He remained semicomatose in the subsequent course. One year later, the craniectomy site was severely depressed. Cranioplasty was considered again; however, due to the severe depression of the craniectomy area, the V-P shunt tube was first temporarily occluded at the subcutaneous region to allow the expansion of the depressed area. The depression site gradually expanded in 3 days. Cranioplasty was then performed, and occlusion of the shunt tube was released. He tolerated the procedure very well, and his consciousness improved gradually.

Received 21 September 2001

Accepted 3 December 2001

Correspondence to: Ming-Chien Kao, MDDMSc, Professor and Chief, Division of Neurosurgery, Department of Surgery, National Taiwan University Hospital, 7 Chung-Shan South Road, Taipei 100, Taiwan. Tel.: +886-2-23412527; Fax: +886-2-23412527; E-mail: neurokao@ha.mc.ntu.edu.tw

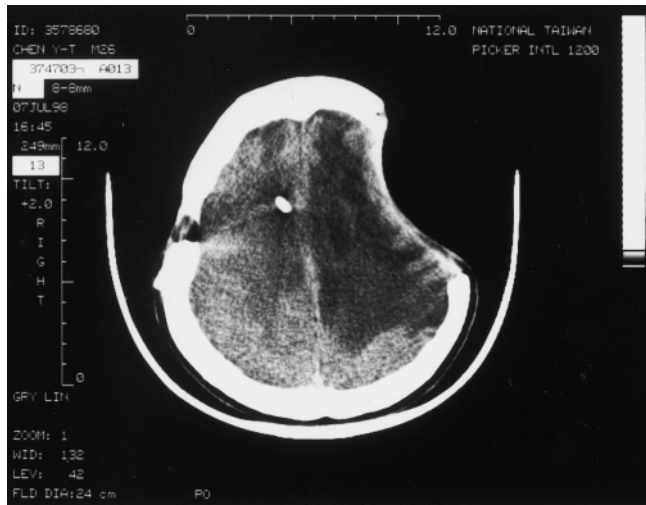

Fig. 1 Non-enhanced CT scan of a 28-year-old male (case 1) showing depression of the scalp flap with encephalomalacia of the underlying brain after a V-P shunt for post-traumatic hydrocephalus.

Case 2

This 51-year-old male suffered from a head injury due to a serious fall. He was found unconscious and was sent to a local hospital where an emergency right frontotemporoparietal craniectomy for brain contusion and diffuse brain swelling was performed. Postoperatively, he remained semicomatose and left hemiplegic. He was transferred to another hospital 1 week later, and communicating hydrocephalus was noted. He received a ventriculoperitoneal shunt but no improvement was noted. He was transferred to our hospital for rehabilitation 6 months later. At that time, he was stuporose with spastic left hemiplegia. A CT scan showed that the craniectomy site was severely sunken with contralateral shifting of the underlying brain (Fig. 2). He was scheduled for cranioplasty. At first, temporary occlusion of the peritoneal catheter at the forehead with a straight aneurysm clip was performed to allow the expansion of the depressed site. One day after the occlusion, the sunken craniectomy site became flat. Subsequently, he underwent a cranioplasty smoothly and the aneurysm clip on the shunt tube was released after finishing the cranioplasty (Fig. 3). The patient tolerated the operation well and his cognition improved postoperatively.

Case 4

This 60-year-old male was hit by a motorcycle. He suffered from a skull fracture and brain contusion. He became stuporose on the next morning. A follow-up CT scan revealed a progression of the hematoma with severe brain swelling. Therefore, he underwent an emergency bifrontal craniectomy and evacuation of the right frontal hematoma. Postoperatively, persistent elevation of intracranial pressure was noted. A follow-up CT scan 2 weeks after the initial injury revealed the development of hydrocephalus and a V-P shunt was performed. His neurological condition gradually improved. The scalp flap gradually became depressed. Two months later, the craniectomy site became very depressed. Temporary shunt occlusion with an aneurysm clip was done to allow the expansion of the depressed brain 1 day before cranioplasty. The clip was released after the cranioplasty. He tolerated the procedure well.

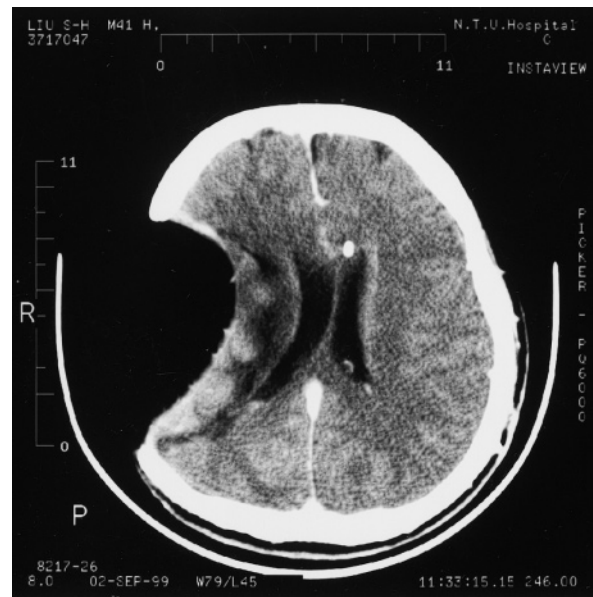

Fig. 2 CT scan of a 51-year-old male (case 2) with severe depression at the craniectomy site resulting in contralateral shifting of the midline structures after craniectomy and a V-P shunt.

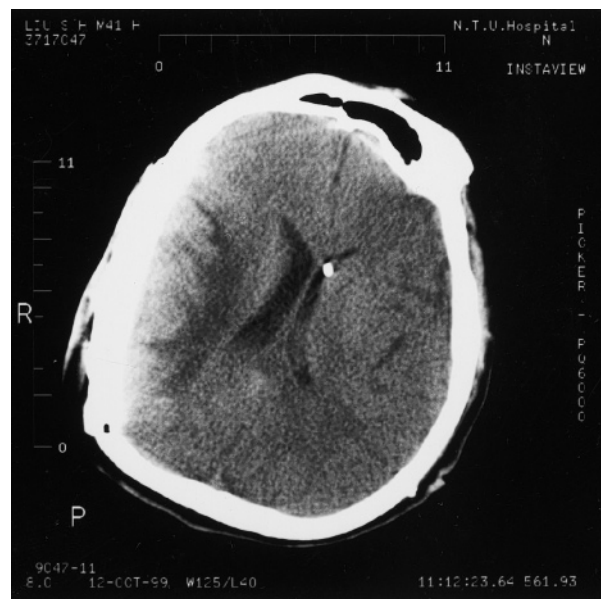


Fig. 3 Non-enhanced CT scan of the patient (case 2) showing restoration of the skull contour and ventricular size after cranioplasty followed by temporary occlusion of the shunt.

DISCUSSION

Ventricular dilatation may often develop in patients with severe head injury, and it is presumed to relate to brain atrophy and the development of hydrocephalus.¹⁻⁴ When hydrocephalus develops in a patient after a decompressive craniectomy, the brain may progressively bulge via the craniectomy site. In this situation, the necessity for shunting is in little doubt. The cause-effect relationship between decompressive craniectomy and hydrocephalus is not well elucidated. In Phuenpathom's series,⁴ seven (10.1%) out of 69 cases undergoing craniectomy for severe brain swelling due to head injury developed

Table 1 Summary of cases

No.	Age (years)	Sex	CT findings	Craniectomy	Duration of V-P shunt to cranioplasty	Duration of shunt occlusion to cranioplasty	Clinical outcome
1	28	Male	Brain swelling, EDH	Left frontotemporal	1 year 5 months	3 days	Improved
2	51	Male	Brain swelling, ICH	Right frontotemporoparietal	6 months	1 day	Improved
3	18	Male	Brain swelling, SDH	Bilateral frontotemporal	2 months	1 day	Improved
4	60	Male	ICH	Bifrontal	2 months	1 day	Improved

EDH: epidural hematoma; ICH: intracerebral hematoma; SDH: subdural hematoma.

post-traumatic hydrocephalus (PTH). In contrast, only 10 (0.99%) out of 1011 cases of head injury without craniectomy had PTH. Patients with decompressive craniectomy may develop bulging at the craniectomy site, especially when associated with hydrocephalus in the later period. The blockage of CSF flowing around the cerebral convexities is one of the possible mechanisms. Polin et al.⁵ reported that patients undergoing bifrontal craniectomy had a better outcome than those with medical treatment. However, a high incidence of shunt-dependent hydrocephalus (28.6%) was noticed in their series.

V-P shunting for hydrocephalus in patients with a skull defect may result in excessive sinking at the craniectomy site due to the atmospheric pressure gradient. This sinking is aggravated when the patient is in an upright position, especially when there is brain atrophy or parenchymal loss. Tabaddor and LaMorgese reported that a patient with severe sinking at the skull defect and contralateral hemiparesis 4 months after craniectomy recovered after cranioplasty.⁶ They believed that this benefit is due to the relief of the pressure gradient between the atmosphere and the intracranial space. The existence of a CSF outflow route posed another problem in craniectomized patients. Guido and Patterson reported two craniectomized patients with neurological deterioration in the upright position, because they had a CSF leak from lumbar spinal drainage.⁷ Their symptoms were relieved after sealing the leak with an epidural blood patch. The same condition was noted in cases 3 and 4 of Schiffer's series.⁸ In his case 3, a lumbar puncture was placed to assess the potential benefit of a V-P shunt, and in case 4, a shunt was actually placed. Subsequently, their neurological condition deteriorated and the concavity of the scalp flap aggravated. Both patients improved significantly after cranioplasty.

Although hematoma formation is an unusual complication of cranioplasty and only two cases were reported in a series of 1030,⁹ cranioplasty on the patient with a severe concave scalp flap at the craniectomy site does increase the risk of fluid accumulation or hematoma formation. Therefore, a simple procedure for expansion of the depressed concave space before performing cranioplasty is prudent and valuable.

In reviewing the literature, there are many papers reporting patients with severe skull concavity.^{6,8,10} However, they did not mention how to expand the concave space. The intracranial compartments are composed of blood, brain parenchyma and CSF. To expand the intracranial volume to "fill" the depression at the skull defect, it is necessary to increase the volume of either brain, blood or CSF. It is harmful to induce a brain edema, especially in damaged brains. The effect of

increasing intracranial blood volume by the head-down position and/or hypoventilation is relatively limited and is insufficient for patients with severe scalp depression with CSF shunting, brain atrophy and parenchymal loss. There are several methods by which to increase CSF volume in hydrocephalic patients with a shunt, such as temporary shunt occlusion, shunt removal or fluid infusion through another ventriculostomy. However, many of these patients are shunt dependent, and if the shunt is removed, another shunt is required later. As for fluid infusion through ventriculostomy, it should be done very cautiously and it poses a risk of contamination. In this paper, we propose a simple technique to occlude the shunt tube before cranioplasty and release the occlusion after cranioplasty. It has proven to be a simple, minimally invasive method to expand the scalp depression and to eliminate the dead space and thus avoid the risk of hematoma complicating a cranioplasty.

In conclusion, based on our experience, temporary shunt occlusion before cranioplasty in patients with a severely depressed scalp flap after decompressive craniectomy and V-P shunt is a simple, useful, and minimally invasive procedure. It can safely and effectively eliminate the dead space between the skull plate and the dura, and lessen the risk of hematoma complicating a cranioplasty.

REFERENCES

1. Beyerl B, Black PM. Posttraumatic hydrocephalus. *Neurosurgery* 1984; 15: 257–261.
2. Cardoso ER, Galbraith S. Posttraumatic hydrocephalus – a retrospective review. *Surg Neurol* 1985; 23: 261–264.
3. Marmarou A, Abd-elfattah Foda MA, Bandoh K et al. Posttraumatic ventriculomegaly: hydrocephalus or atrophy? A new approach for diagnosis using CSF dynamics. *J Neurosurg* 1996; 85: 1026–1035.
4. Phuenpathom N, Ratanalert S, Saeheng S et al. Post-traumatic hydrocephalus: experience in 17 consecutive cases. *J Med Assoc Thai* 1999; 82: 46–53.
5. Polin RS, Shaffrey ME, Bogaev CA et al. Decompressive bifrontal craniectomy in the treatment of severe refractory posttraumatic cerebral edema. *Neurosurgery* 1997; 41: 84–94.
6. Tabaddor K, LaMorgese J. Complications of a large cranial defect. *J Neurosurg* 1976; 44: 506–508.
7. Guido LJ, Patterson RH. Focal neurological deficits secondary to intraoperative CSF drainage: successful resolution with an epidural blood patch. Report of two cases. *J Neurosurg* 1976; 45: 348–351.
8. Schiffer J, Gur R, Nisim U et al. Symptomatic patients after craniectomy. *Surg Neurol* 1997; 47: 231–237.
9. Rish BL, Dillon D, Meironsky AM, et al. Cranioplasty: a review of 1030 cases of penetrating head injury. *Neurosurgery* 1979; 4: 381–385.
10. Walker AE, Erculei F. The late results of cranioplasty. *Arch Neurol* 1963; 9: 15–20.