

## Patient Report

# White matter lesion due to dural sinus thrombosis in an infant with subdural hematoma

KIMITAKA TAKITANI,<sup>1</sup> ATSUSHI NISHINO,<sup>1</sup> TAKUYA TANABE,<sup>1</sup> HARUKI TANAKA,<sup>1</sup>  
KOSHI HARADA,<sup>2</sup> TAKASHI MIMAKI<sup>3</sup> AND HIROSHI TAMAI<sup>1</sup>

<sup>1</sup>*Department of Pediatrics, Osaka Medical College, <sup>2</sup>Department of Radiology, Sakai Municipal Hospital, Osaka and <sup>3</sup>Faculty of Education, Gifu University, Gifu, Japan*

**Key words** dural sinus thrombosis, infant, subdural hematoma, white matter lesion.

In infants with acute subdural hematoma, computed tomography (CT) scans often reveal diffuse hemispheric low density.<sup>1</sup> The pathophysiology of this cerebral white matter lesion is probably venous congestion caused by injury to bridging veins. In the present case, a diffuse cerebral white matter lesion shown by CT due to the thrombus of dural sinus diagnosed by magnetic resonance imaging (MRI) in an infant with acute subdural hematoma is described.

## Case report

A 2-month-old girl was admitted for vomiting and decreasing level of consciousness. She had no prior history of trauma or infection. Clinical examination was remarkable for lethargy, bulging and pulsatile fontanel, prolonged light reflex in the right pupil, bilateral deviation of eyes to the right, and increased deep tendon reflexes. Laboratory findings were within normal limits except for hemoglobin of 6.4 g/dL. Prothrombin time, partial thromboplastin time, and anti-thrombin III were all within normal limits.

Cranial CT on admission revealed a right subdural hematoma (Fig. 1a). Cerebral angiography was not carried out. The patient was started on glycerol, dexamethasone, and phenobarbital. Three days after admission, she exhibited left-sided clonic convulsions for which a continuous infusion of lidocaine was initiated. On day 5 of admission, a repeat CT demonstrated some improvement in the right subdural hematoma. Diffuse low density areas were noted in the white matter of bilateral cerebral hemispheres. Increased density

was present within the straight sinus and the confluence of the sinus (Fig. 1b).

On day 6, MRI was carried out which demonstrated high signal intensity within the confluence of the sinus on T<sub>2</sub>- and proton-density weighted images (Fig. 2). The right subdural hematoma was well visualized, but the MRI did not show relevant changes in the white matter.

Seizures decreased in frequency and severity. Glycerol, dexamethasone, and lidocaine were discontinued. On day 14 of admission, she could orally take milk. She continued to improve with phenobarbital treatment and was discharged on day 30. At discharge, she had no further seizures, was alert, but had a mild left hemiplegia. Follow-up CT showed no low density areas in either frontal lobes, but they were present in the right occipital lobe (Fig. 3). At 12 months of age, her development was normal and the mild left hemiplegia had resolved.

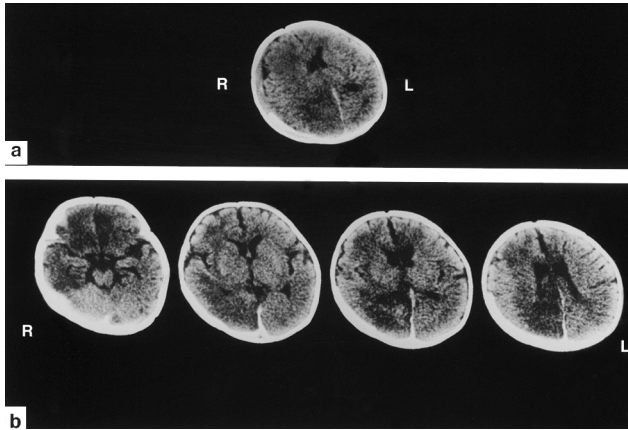
## Discussion

In neonates, venous thrombosis has been associated with acute systemic disease, including congenital heart disease, shock, metabolic acidosis, sepsis, or acute dehydration, and undetermined causes.<sup>2</sup> In older infants and children, cerebral venous thrombosis have demonstrated etiologic associations with acute dehydration and local infection such as meningitis, otitis media, or scalp cellulitis. More recently, venous thrombosis has resulted from hypercoagulable states caused by protein C deficiency or the mutation in the factor V.<sup>3</sup>

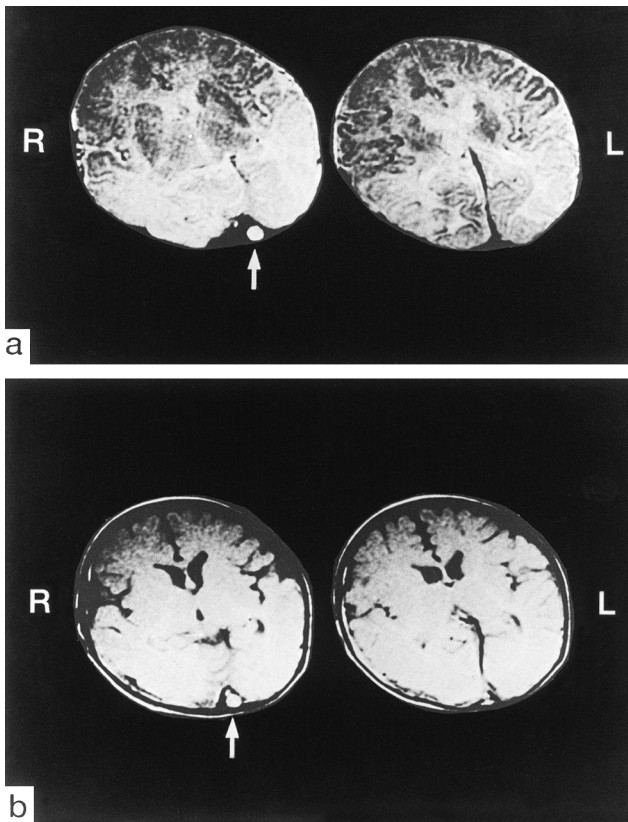
Cerebral venous thrombosis in children is a rare disorder.<sup>4</sup> The clinical diagnosis of dural sinus thrombosis is difficult due to the non-specificity of the clinical presentation. Symptoms can include headache, nausea, vomiting, disorientation, seizures, decreased level of consciousness, or speech and motor disturbances. The CT findings of dural sinus thrombosis can be divided into direct and indirect signs.

Correspondence: Kimitaka Takitani MD, Department of Pediatrics, Osaka Medical College, 2-7 Daigakumachi, Takatsuki, Osaka 569-8686, Japan. Email: ped016@poh.osaka-med.ac.jp

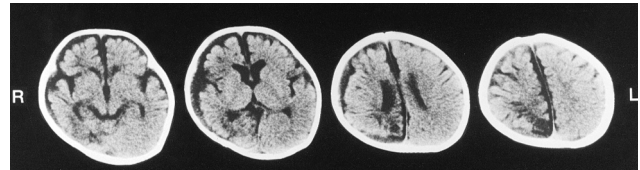
Received 25 October 2001; revised 27 February 2002; accepted 25 April 2002.



**Fig. 1** (a) Cranial computed tomography (CT) scans on admission demonstrates a right subdural hematoma. (b) Non-contrast CT scans obtained 5 days after admission shows low density areas in the white matter of bilateral cerebral hemispheres and increased density within the straight sinus and the confluence of the sinus.



**Fig. 2** (a) T2-weighted image (2000/100) (a repetition time/echo time). (b) Proton density weighted image (2000/30). Axial images reveal intense signal in the confluence of the sinus (arrow).



**Fig. 3** Follow-up non-contrast computed tomography scan obtained at discharge shows low density area in the right occipital lobe on day 35 of admission.

Direct signs include the 'cord sign' and the 'empty delta' sign are specific for this condition and consist of the actual visualization of a thrombus within a vein or sinus.<sup>5</sup> Indirect signs are less specific, but may suggest venous thrombosis. These include low density areas, hemorrhage, small ventricles, gyral enhancement, and dilated collateral veins.<sup>6</sup> Specific CT findings are not always present and can be sometimes overlooked.<sup>6,7</sup> In addition, bony structures may cause artifacts which impair the evaluation of the sinuses. Conventional or digital subtraction angiography may be considered as confirmatory tests,<sup>8</sup> but these are invasive and should not be used without a specific indication.<sup>6</sup> Magnetic resonance angiography provides excellent visualization of dural sinuses and cerebral veins non-invasively.<sup>9</sup> This is a very useful imaging technique to evaluate venous sinus thrombosis. Magnetic resonance angiography, as well as cerebral angiography, was not carried out in the present case. However, we consider the diagnosis of dural sinus thrombosis by clinical symptoms and findings of MRI at the acute phase.

Magnetic resonance imaging in this case demonstrated high signal intensity within the confluence of the sinus due to clotted blood. This was noted on T<sub>2</sub>- and proton-density weighted images. The thrombus was most likely related to the subdural hematoma. Previous reports have demonstrated non-specific low density areas on CT as findings with venous infarction,<sup>5</sup> venous congestion<sup>1</sup> or ischemic change.<sup>10</sup> In our case, the thrombus may have caused the hypoperfusion lesions in the bilateral cerebral hemispheres on CT examinations, because these are not confined to the blood supply of a single artery. Although the MRI findings were not consistent with venous infarction suggested by the low densities on unenhanced CT, it is probable that the diffuse hypoperfusion lesion of the cerebral white matter due to the thrombus of the confluence of the sinus is reversible.

The CT scan prior to discharge demonstrated a low density area only in the right occipital lobe. The lesions in the other lobes were diminished. We speculate that there is a difference of the degree of damage in each lobe. At discharge, follow-up MRI demonstrated recanalization of the sinus. Repeated CT showed no diffuse cerebral white matter lesions. We speculate that a reversible hypoperfusion lesion

of cerebral white matter following venous congestion due to thrombosis of the dural sinus may have caused the low density areas seen on the CT on day 5. The present case suggests that, in neonates and children whose CT show diffuse low densities, the presence of cerebral venous thrombosis should be considered.

## References

- 1 Fujimoto K, Shimomura T, Okumura Y, Sakaki T. CT shows ipsilateral cerebral hemispheric low density area after acute subdural hematoma in infants. *Nervous System Children* 1999; **24**: 504–8 (in Japanese).
- 2 Barron TF, Gusnard DA, Zimmerman RA, Clancy RR. Cerebral venous thrombosis in neonates and children. *Pediatr. Neurol.* 1992; **8**: 112–16.
- 3 Vielhaber H, Ehrenforth S, Koch HG, Scharrer I, van der Werf N, Nowak-Gottl U. Cerebral venous sinus thrombosis in infancy and childhood: role of genetic and acquired risk factors of thrombophilia. *Eur. J. Pediatr.* 1998; **157**: 555–60.
- 4 deVeber G, Andrew M, Adams C *et al.* Cerebral sinovenous thrombosis in children. *N. Engl. J. Med.* 2001; **345**: 417–23.
- 5 Kim KS, Walczak TS. Computed tomography of deep cerebral venous thrombosis. *J. Comput. Assist. Tomogr.* 1986; **10**: 386–90.
- 6 Hulcelle PJ, Dooms GC, Mathurin P, Cornelis G. MRI assessment of unsuspected dural sinus thrombus. *Neuroradiology* 1989; **31**: 217–22.
- 7 Synder TC, Sachdev HS. MR imaging of cerebral dural sinus thrombosis. *J. Comput. Assist. Tomogr.* 1986; **10**: 889–91.
- 8 Hanigan WC, Rossi LJ, McLean JM, Wright RM. MRI of cerebral vein thrombosis in infancy: a case report. *Neurology* 1986; **36**: 1354–6.
- 9 Wang AM. MRA of venous sinus thrombosis. *Clin. Neurosci.* 1997; **4**: 158–64.
- 10 Eick JJ, Miller KD, Bell KA, Tutton RH. Computed tomography of deep cerebral venous thrombosis in children. *Radiology* 1981; **140**: 399–402.