

Analysis of Pathways Mediating Preserved Vision after Striate Cortex Lesions

Mircea Ariel Schoenfeld, MD,¹ Toemme Noesselt, PhD,¹ Dorothe Poggel, PhD,² Claus Tempelmann, PhD,¹ Jens-Max Hopf, MD,¹ Martin G. Woldorff, PhD,³ Hans-Jochen Heinze, MD,¹ and Steven A. Hillyard, PhD⁴

This study investigated the neural substrates of preserved visual functioning in a patient with homonymous hemianopsia and Riddoch syndrome after a posterior cerebral artery stroke affecting the primary visual cortex (area V1). The limited visual abilities of this patient included above-chance verbal reports of movement and color change as well as discrimination of movement direction in the hemianopic field. Functional magnetic resonance imaging showed that motion and color-change stimuli presented to the hemianopic field produced activation in several extrastriate areas of the lesioned hemisphere that were defined using retinotopic mapping. Magnetoencephalographic recordings indicated that evoked activity occurred earlier in the higher-tier visual areas V4/V8 and V5 than in the lower-tier areas V2/V3 adjacent to the lesion. In addition, the functional magnetic resonance imaging analysis showed an increased functional connectivity between areas V4/V8 and V5 of the lesioned hemisphere in comparison with the same areas in the intact hemisphere during the presentation of color changes. These results suggest that visual perception after the V1 lesion in Riddoch syndrome is mediated by subcortical pathways that bypass V1 and project first to higher-tier visual areas V5 and V4/V8 and subsequently to lower-tier areas V2/V3.

Ann Neurol 2002;52:814–824

Patients who suffer extensive damage to the primary visual cortex (area V1) of one hemisphere exhibit a contralateral hemianopsia that usually includes the loss of conscious awareness of stimuli in the affected hemifield. Nevertheless, some of these patients are able to respond to stimuli presented in the blind hemifield in the absence of awareness, an ability that has been termed *blindsight*.¹ Other patients, however, do retain some degree of visual awareness, especially related to motion perception. This condition has been termed *Riddoch syndrome*^{2,3} and can be distinguished from blindsight in which visual awareness is absent.^{4,5}

Numerous studies have been conducted in both humans and monkeys in an attempt to reveal the neural substrates of preserved visual functions after striate cortex lesions. Fendrich and colleagues⁶ conducted high-resolution perimetry in a hemianopic patient exhibiting blindsight and found evidence that some V1 neurons may have survived the cortical injury. These “spared islands” in V1 were proposed to retain their regular projections to higher-tier extrastriate regions of the visual cortex and to mediate above-chance stimulus detection without awareness. Consistent with this spared-island hypothesis was a study in monkeys that found

after partial lesioning of V1 that the receptive fields of MT neurons were restricted to the part of the visual field represented in the spared region of V1.⁷ Although spared islands might explain blindsight in some cases,⁸ several studies of patients with V1 lesions do not support such a mechanism. One recent study used microperimetry in a blindsight subject and failed to demonstrate residual islands,⁹ whereas several neuroimaging studies in patients with V1 lesions^{3,10–12} failed to find any evidence for islands of activity within the lesioned striate cortex.

A second hypothesis to account for the visual capabilities in blindsight/Riddoch patients asserts that information from the retina reaches the extrastriate cortex via pathways that bypass V1. The existence of such extrageniculostriate pathways projecting to the midbrain and especially to the superior colliculus and pulvinar has been demonstrated in monkeys^{13–20} and in humans.^{10,21} These pathways ultimately project to extrastriate cortex, primarily to area V5/MT.¹⁵ Neurophysiological studies in anesthetized monkeys with ablated or reversibly inactivated striate cortex have found that neurons in extrastriate cortical areas of the dorsal stream retained much of their visual responsiveness,¹⁸

From the ¹Department of Neurology II, University of Magdeburg, Magdeburg; ²Generation Research Program, University of Munich, Bad Toelz, Germany; ³Center for Cognitive Neuroscience, Duke University, Durham, NC; and ⁴Department of Neurosciences, University of California at San Diego, La Jolla, CA.

Received May 6, 2002, and in revised form Aug 23. Accepted for publication Aug 23, 2002.

Address correspondence to Dr Schoenfeld, Department of Neurology II, University of Magdeburg, 39120 Magdeburg, Germany.
E-mail: ariel@neuro2.med.uni-magdeburg.de

whereas those of the ventral stream appeared to be more dependent on intact striate cortex.²²

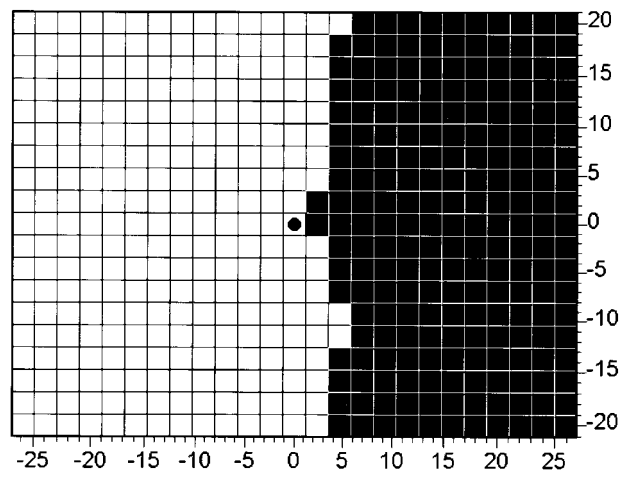
Several functional magnetic resonance imaging (fMRI) studies in blindsight patients have described visual-evoked activity in extrastriate areas ipsilateral to the lesioned V1.^{3,10–12} Important questions remain, however, concerning which extrastriate areas are involved and the order and timing of their activations. In particular, it is not clear whether the extrageniculostriate pathways project initially to lower-tier levels such as V2 or V3, to higher-tier levels (eg, entering V5 first and then projecting back to areas V2 and V3), or to even higher levels through connections with regions such as IT. We investigated these alternatives in this study by combining fMRI with magnetoencephalographic (MEG) recordings to study the spatiotemporal patterning of cortical activity associated with preserved vision in a patient having Riddoch syndrome subsequent to an extensive lesion of primary visual cortex.

Case Report

Subject

The subject was a 22-year-old man who suffered a left hemorrhagic posterior cerebral artery stroke in 1997 at the age of 19 years. Initially, he had a right hemiplegia and a complete right homonymous hemianopia (Fig 1) as confirmed by high-resolution visual field mapping. His lesion affected the entire left striate region as well as portions of the cuneus, the medial and lateral occipital gyri, and the fusiform gyrus (Fig 2A). The lateral occipitotemporal cortex that includes area V5 was spared. His hemiplegia cleared rapidly and almost completely, but the hemianopia remained unchanged. One month after the stroke, he reported that he sometimes perceived moving objects in the blind hemifield without being able to identify them. This ability has remained unchanged.

Fig 1. High-resolution perimetry in the subject. The sighted field extended 3 degrees of visual angle into the right visual field (RVF). There were also two small regions of preserved vision, 2 × 2 degrees in the upper and 4 × 2 degrees in the lower visual field that extended 6 degrees into the RVF.



Currently, he can verbally identify the direction of moving objects but not their shapes. In addition, he is capable of reporting changes between isoluminant colors presented to his blind hemifield but cannot name the color. Thus, his blind field visual abilities appear to be associated with some awareness, consistent with a diagnosis of Riddoch syndrome.

During the last 2 years, he underwent repeated (at least 16 times) high-resolution perimetry for other purposes. None of the examinations showed any “islands of vision” within the scotoma. The pupillary reflex was normal in each case, demonstrating that the retinal projections to the ipsilateral and contralateral Edinger–Westphal nuclei were intact. He gave informed consent to participate in this study, which was approved by the local ethics committee.

High-resolution Visual Field Mapping

In the high-resolution perimetry, stimuli were presented on a 17-inch computer monitor at a luminance level well above detection threshold for the intact visual field. The patient was required to fixate constantly on a central point and to press a key when any stimulus change was detected. Small white circular flashes were presented against a dark background for 150 milliseconds durations at each of 500 different positions within a 25 × 20 degree grid (stimulus size, 0.15 degrees; stimulus luminance, 95cd/m²; background luminance, <1cd/m²). This perimetry task was performed with a chin support at 30cm distance from the monitor.

Stimuli

In the fMRI, MEG, and behavioral experiments, the subject was presented with 8 × 8-degree stimulus patches using a back projection system (microcomputer-controlled video projector). The stimulus patches consisted of three vertical bars (8 degrees tall × 1.6 degrees wide with 1.6-degree spacing between bars) located at 13-degree eccentricity (inner edge of patch) and presented to either the left visual field (LVF) or right visual field (RVF) at 10 degrees below the horizontal meridian (upper edge of patch). In the fMRI experiment, the visual stimuli were back-projected onto a small translucent screen located close to the subject’s chin. The subject viewed the screen via a mirror attached to the head coil or surface coil that was adjusted so that the size and retinal position of the stimuli was the same as in the behavioral and MEG experiments.

For movement stimulation, the vertical bars were gray and were displaced laterally. For color stimulation, the bars changed either from gray to red or green (in the behavioral experiment) or alternated between red and green (in the MEG and fMRI experiments). A fixation cross was present in the middle of the screen throughout the experiment. All stimuli were isoluminant at 200cd/m². The luminance of the background was set to 45cd/m².

In the behavioral experiment, 100 moving stimuli and 100 color-changing stimuli were presented in separate blocks to the “blind” lower RVF of the subject. For movement stimulation, the bars were displaced to either the right or left by 5 degrees over a 250-millisecond period with an immediate return to the stationary position over the next 250 milliseconds. The color changes were from gray to isoluminant red or green with durations of 500 milliseconds. Stationary

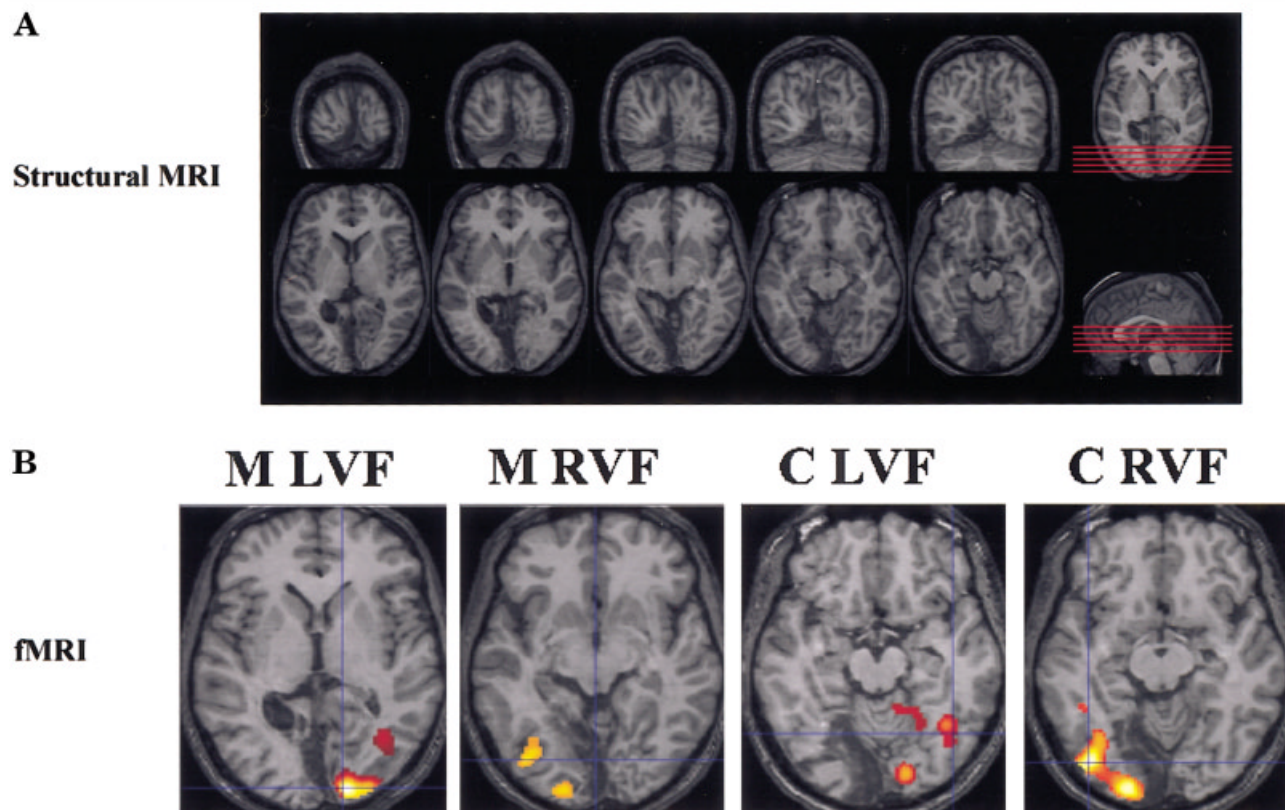


Fig 2. (A) Structural magnetic resonance images (MRIs) of the subject's brain showing the lesioned occipital cortex (dark areas) after the left posterior cerebral artery stroke. The lesion affected the entire left striate cortex. (B) Functional MRI (fMRI) activity elicited by the four types of stimuli presented to the sighted left visual field and "blind" right visual field. The four stimulus conditions were contrasted against a fixation condition. RVF = right visual field; LVF = left visual field; M = motion presented; C = color changes presented.

gray bars were presented in the interstimulus intervals, and the fixation cross was present throughout the experiment on the screen. In the block of moving stimuli, the subject was asked to press a button when he detected a movement and to verbally report the direction of the initial displacement, if possible. In the color-changing block, the subject was instructed to press a button when he detected a color change and to report the color verbally.

In the fMRI experiment, stimuli were presented in a blocked design under five different conditions (moving bars LVF, color-changing bars LVF, moving bars RVF, color-changing bars RVF, and fixation alone), lasting 30 seconds each. These five blocked conditions were repeated in random order three times each during a run. During movement blocks, the bars moved continuously, first laterally for 500 milliseconds and then in the opposite direction for 500 milliseconds at a speed of 10 degrees per second. During color-change blocks, the bars continuously changed color between isoluminant red and green at 2Hz. The experiment consisted of three runs separated by short breaks. The subject was instructed to maintain fixation, ignore the stimuli, and to press a button each time the fixation cross changed into a square, which occurred three to five times every run. This task was given to ensure fixation during stimulation.

In the MEG experiment, the stimuli also were presented

in a blocked design, but without the fixation alone block. The motion stimuli were the same as used in the behavioral experiment, presented at interstimulus intervals randomly varying between 1.0 and 1.4 seconds. In the color-changing blocks, the bars alternated between red and green at interstimulus intervals randomly varying between 1.0 and 1.4 seconds. Each block consisted of 100 stimulus presentations, and four blocks were performed with each type of stimulus. The subject received the same instructions as in the fMRI experiment.

Magnetic Resonance Imaging Data Acquisition

FUNCTIONAL MAGNETIC RESONANCE IMAGING. The subject was scanned with a 1.5T scanner (General Electric Signa Horizon LX, neurooptimized) with a standard GE head coil. The functional images were acquired using a gradient echo single-shot echo planar imaging (EPI) sequence with TE 40 milliseconds, TR 1.5 seconds, bandwidth 125kHz, and flip angle 90 degrees. Sixteen slices (7mm thickness; 1mm gap; field of view, 200mm; matrix, 64 × 64) parallel to the anterior–posterior commissure line covering the full brain were examined. In each functional run, 300 volumes were collected resulting in a scan time of 7.5 minutes per run.

RETINOTOPY. To map the retinotopically organized visual areas, we scanned the subject in a separate session with a 5-inch surface coil covering the occipital pole. The procedure was based on the method of Sereno and colleagues.^{23,24} Field sign maps were calculated using images of 16 slices (thickness, 3mm; no gap; field of view, 20cm; matrix, 64×64) perpendicular to the calcarine fissure, which were collected with scan parameters identical to the parameters of the above-described experiment. The stimuli consisted of flickering black-and-white checks in the form of a thin eccentrically expanding ring (eccentricity stimulus) and a ray-shaped configuration rotating clockwise (polar angle stimulus). In the scanner, fixation was monitored using an infrared camera.

ANATOMICAL IMAGES. A T1-weighted high-resolution data set was acquired using a three-dimensional SPGR sequence with TE 8 milliseconds, TR 2,400 milliseconds, and flip angle 30 degrees. In each functional session, a T1-weighted EPI (inversion recovery prepared EPI, TR, 1,200 milliseconds; TE, 16 milliseconds; TI, 1,050 milliseconds) image set was collected with slice parameters identical to the functional data. These images were used for registration with the fMRI and MEG data.

Magnetic Resonance Data Analysis

MOTION AND COLOR-CHANGE STIMULATION. The fMRI data were analyzed using SPM99 (Wellcome Department of Cognitive Neurology). Functional data were realigned, resliced, and motion-corrected using the preprocessing procedures of SPM. The analyses reported here were conducted on spatially normalized and smoothed (8mm full-width gaussian kernel) images.

RETINOTOPY. Mapping of the borders between the retinotopic visual areas was conducted using the Freesurfer program package (<http://surfer.nmr.mgh.harvard.edu>). The overlay of the functional SPM results on the occipital cortical surface was accomplished by manual alignment of the inversion recovery prepared EPI and T1-weighted high-resolution data, including rotation, translation, and linear scaling.

FUNCTIONAL CONNECTIVITY ANALYSIS. This analysis was performed by first defining four volumes of interest located in the V4/V8 and V5 regions of each hemisphere by using the retinotopic maps. Each volume of interest was defined by a sphere with a radius of 5mm centered on the voxel corresponding to the local maximum of activity in each region. The major focus of color activation included regions anterior and lateral to retinotopically mapped V4 as well as within area V4 itself. Because the controversy as to whether the main color-sensitive area should be termed V4²⁵ or V8²⁶ is beyond the scope of this study, we refer to this color-activated region as V4/V8. The correlation between time courses of activity in the V4/V8 and V5 volumes of interests were calculated for each hemisphere during color stimulation to the contralateral visual field.

Magnetoencephalography

DATA ACQUISITION. MEG activity was recorded using a BTI Magnes 2500 WH (Biomagnetic Technologies, San Di-

ego, CA) whole-head system with 148 magnetometers and a DC to 50Hz. bandpass. Artifact rejection was performed offline by removing epochs with peak-to-peak amplitudes exceeding a threshold of 3.0×10^{-12} T as well as epochs before, during, and after button presses. Individual head shapes were coregistered with the sensor coordinate system by digitizing (Polhemus 3Space Fastrak) skull landmarks (nasion, left, and right preauricular points) and determining their locations relative to sensor positions using signals from five distributed head coils. These landmarks, in turn, enabled coregistration of MEG activity to individual anatomical MR scans. Fixation was monitored with vertical and horizontal electrooculogram.

DATA ANALYSIS. Separate event-related field (ERF) averages were obtained in response to the four stimulus conditions: motion LVF, motion RVF, color LVF, and color RVF. MEG source analysis was performed using multimodal neuroimaging software Curry 4.0 (Neuroscan, El Paso, TX). A boundary element model was derived for the subject using his MRI scan which defined the volume conductor geometry for the source analysis. Dipole fits were computed for each condition separately. In the first (unseeded) analysis, the fields corresponding to each peak in the ERF were modeled using a single equivalent current dipole in the time window of each peak. During the iterative best-fitting estimation calculations, the dipoles were allowed to move within the volume conductor without any constraints. In the second (seeded) analysis, the equivalent current dipoles were constrained in location to the hemodynamic activity spots, and the analysis was performed over the whole time range for each of the four stimulus conditions.

Results

Behavioral Testing

Consistent with the case history, the subject was highly accurate at detecting the moving bars in the hemianopic (right) visual field. He detected 96 of 100 stimuli, and of those he reported the direction of the motion correctly for 80 stimuli. He also performed well above chance (82 of 100 stimuli) at detecting isoluminant color changes of the bars in the RVF, although he was not able to report the color.

Functional Magnetic Resonance Imaging

ACTIVITY ELICITED BY STIMULI PRESENTED TO THE SIGHTED LEFT VISUAL FIELD. The contrast between the blocks with motion presented to the left (sighted) visual field (M-LVF) versus blocks of fixation showed two significant foci of hemodynamic activity in the right hemisphere (see Fig 2B). One of these foci was located in the striate/peristriate region, and the other in lateral occipital cortex just posterior to the occipitotemporal junction. The contrast between color changes presented to the LVF (C-LVF) and fixation showed three consistent foci, one in the striate/peristriate region, a second in lateral occipitotemporal cortex, and a

third located in ventral occipital cortex within the fusiform gyrus (Table 1).

ACTIVITY ELICITED BY STIMULI PRESENTED TO THE “BLIND” RIGHT VISUAL FIELD. In the contrast between motion presented to the right visual field (M-RVF) and fixation (see Fig 2B), the subject presented two foci of activity in the left hemisphere, one located in posterior medial occipital cortex adjacent to the lesion and a second located more anteriorly, superiorly, and laterally in the vicinity of the occipitotemporal junction.

The contrast of color change presented to the right visual field (C-RVF) versus fixation showed three significant foci, one located in the posterior occipital lobe of the left hemisphere next to the lesion, a second located more anteriorly and laterally on the inferior surface of the left occipital lobe in the fusiform gyrus, and a third located superiorly to the second near the occipitotemporal junction (see Table 1).

MAPPING OF THE BORDERS BETWEEN VISUAL AREAS. The visual areas in the intact right hemisphere showed the typical retinotopic organization²⁴ 1995 (Fig 3). Motion in the sighted LVF activated areas V1, V2, a part of V3, V3a, and V5 in the right hemisphere, whereas color changes activated areas V1, V2, V4/V8, and V5.

The mapping of the lesioned left hemisphere (Fig 4) showed a residual retinotopic organization of several visual areas presumed to correspond to V2, V3, V4/V8, and V5. The coregistration with fMRI activations in response to stimuli presented to the RVF showed that putative areas V2/V3 and V5 in the left hemisphere were activated during motion presentation, whereas putative areas V2/V3, V4/V8, and V5 were activated

during the presentation of color changes. Even at low-significance levels ($p < 0.1$), there was no activity within the lesioned area.

CONNECTIVITY ANALYSIS. Areas V4/V8 and V5 were strongly activated in the right hemisphere by color-change stimuli in the intact LVF, whereas putative areas V4/V8 and V5 of the left hemisphere were activated by the same stimuli in the RVF. The functional connectivity²⁷ between V4/V8 and V5 was indexed by the correlation of the time courses of activity between these two areas during continuous color stimulation. The correlation was considerably higher between putative areas V4/V8 and V5 in the lesioned left hemisphere ($r = 0.75$) than between V4/V8 and V5 in the intact right hemisphere ($r = 0.35$; Fig 5).

Magnetoencephalography

EVENT-RELATED FIELDS ELICITED BY STIMULI PRESENTED TO THE SIGHTED LEFT VISUAL FIELD. MEG activity elicited by M-LVF began at approximately 50 milliseconds after stimulus and included an early peak at around 70 milliseconds (Fig 6A). The best-fit dipole for this initial deflection was located in the right calcarine area near the fMRI activations in areas V1/V2 and accounted for 84.4% of the variance of the ERF at 65 to 75 milliseconds. A second, larger deflection began at 80 milliseconds and reached a peak at 122 milliseconds. The activity in the time range of this peak (at 106–124 milliseconds) was modeled with a dipole located on the lateral aspect of the right occipital lobe in the region of the occipitotemporal junction that explained 94.6% of the variance of the ERF distribution. This dipole was adjacent to the fMRI activation produced in area V5 by the M-LVF stimulus. The Talairach coordinates of the best-fit dipoles are given in Table 2.

The C-LVF stimulus elicited activity starting at approximately 65 milliseconds after stimulus with an initial peak at 100 milliseconds (see Fig 6B). The beginning of this deflection (63–81 milliseconds) was modeled by a dipole located near the fMRI activation in areas V1/V2 that explained 88.2% of the variance of the ERF. From 95 to 106 milliseconds, the variance of the ERF was best accounted for (89.8%) by a modeled dipole in the posterior fusiform gyrus near the fMRI activation in area V4/V8. A second peak at 145 milliseconds was modeled in the time range 134 to 148 milliseconds by a dipole that was located on the lateral aspect of the right occipital lobe near the fMRI activation in area V5 and accounted for 93.6% of the variance of the field distribution.

A further analysis used a “seeded dipole” modeling approach in which the dipoles were constrained to the locations of the fMRI activity. Accordingly, the

Table 1. Talairach Coordinates for Hemodynamic Activity Peaks

Condition	(x/y/z)	Region
M-LVF	10/−89/4	Calc. S
	42/−70/−8	Right LOT
M-RVF	−25/−93/4	Left post med occipital
	−40/−74/−8	Left LOT
		Right LOT
C-LVF	12/−92/4	Right Calc. S
	39/−58/−12	Right Fusi. G
	38/−66/−10	Right LOT
C-RVF	−21/96/2	Left post med occipital
	−42/−74/−12	Left Fusi G
	−37/−67/−8	Left LOT

M-LVF = motion presented to the left visual field; Calc. S = calcarine sulcus; LOT = lateral occipital temporal; M-RVF = motion presented to the right visual field; C-LVF = color changes presented to the LVF; Fusi. G = fusiform gyrus; C-RVF = color changes presented to the RVF.

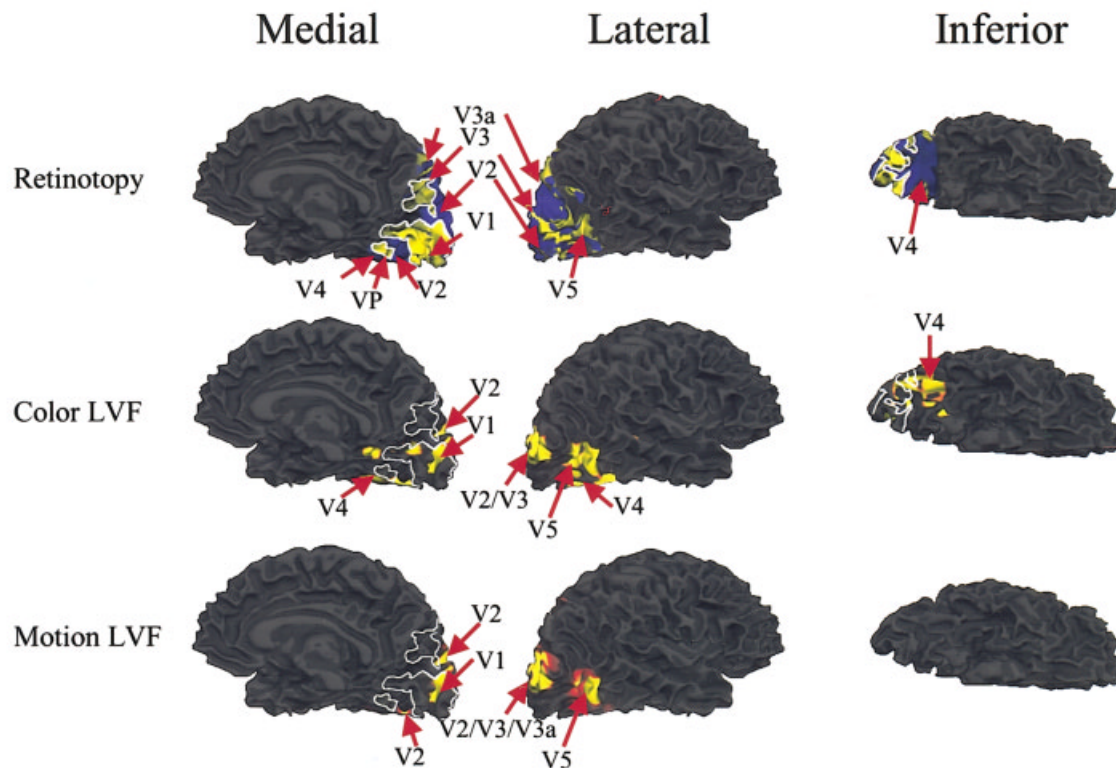


Fig 3. Right hemisphere functional magnetic resonance imaging (fMRI) activity. (top row) Retinotopic mapping of visual areas in the healthy (right) hemisphere of the patient. (middle row) fMRI activity elicited by the presentation of color-change stimuli to the left visual field (LVF) coregistered with the borders of the retinotopic areas. (bottom row) Coregistration of the retinotopic areas with the fMRI activity elicited by moving stimuli in the LVF.

M-LVF fields were modeled with two sources, one in right V1/V2 and one in right V5 region using the activation loci shown in Table 1. This solution accounted for 84.2% of the variance of the field over the time range 59 to 130 milliseconds. The V1/V2 dipole accounted for the activity in the early part (59–90 milliseconds), whereas the V5 dipole accounted for the activity in the later part of the time range (90–130 milliseconds). The C-LVF response was modeled using three sources located in the right V1/V2 region, the right V4/V8 region and the lateral occipital region. Over the time range 63 to 146, this model accounted for 90.4% of the variance of the field. In this model, the V1/V2 source accounted for the early part (63–85 milliseconds), whereas the V4/V8 and V5 dipoles accounted for the later part (90–120 and 125–146 milliseconds) of the time range.

EVENT-RELATED FIELDS ELICITED BY STIMULI PRESENTED TO THE BLIND RIGHT VISUAL FIELD. M-RVF elicited activity starting at approximately 90 milliseconds after stimulus and peaking at 160 milliseconds. As shown in Figure 6C, the ERFs during this interval could be accounted for by two dipolar sources. The first dipole was located anteriorly and laterally from the lesion,

near the occipitotemporal junction, and accounted for 84.2% of the variance of the field in the time range 106 to 118 milliseconds. This dipole was stable in location and orientation over the whole time range. The ERF in the interval 185 to 210 milliseconds was modeled with a dipole located more posteriorly and medially, close to the border of the lesion, which explained 91.4% of the variance in this time range.

C-RVF also elicited activity starting at approximately 90 milliseconds having two peaks at 125 and 175 milliseconds (see Fig 6D). The ERF in the time range 110 to 130 milliseconds was modeled with a single dipole located near the occipitotemporal junction just medial to the fMRI activations in putative areas V4/V8, which accounted for 84.3% of the field variance. Activity in the time range 169 to 193 milliseconds was modeled with a second dipole located more posteriorly and adjacent to the lesion, which accounted for 92.4% of the variance of the ERF. In general, the close correspondence between dipole locations and the unseeded fMRI activations indicated that the modeled sources closely matched the active regions found in occipital cortex hemodynamic measures (cf Tables 1 and 2).

In the seeded dipole analysis, constraining the locations of the dipoles to the foci of hemodynamic activ-

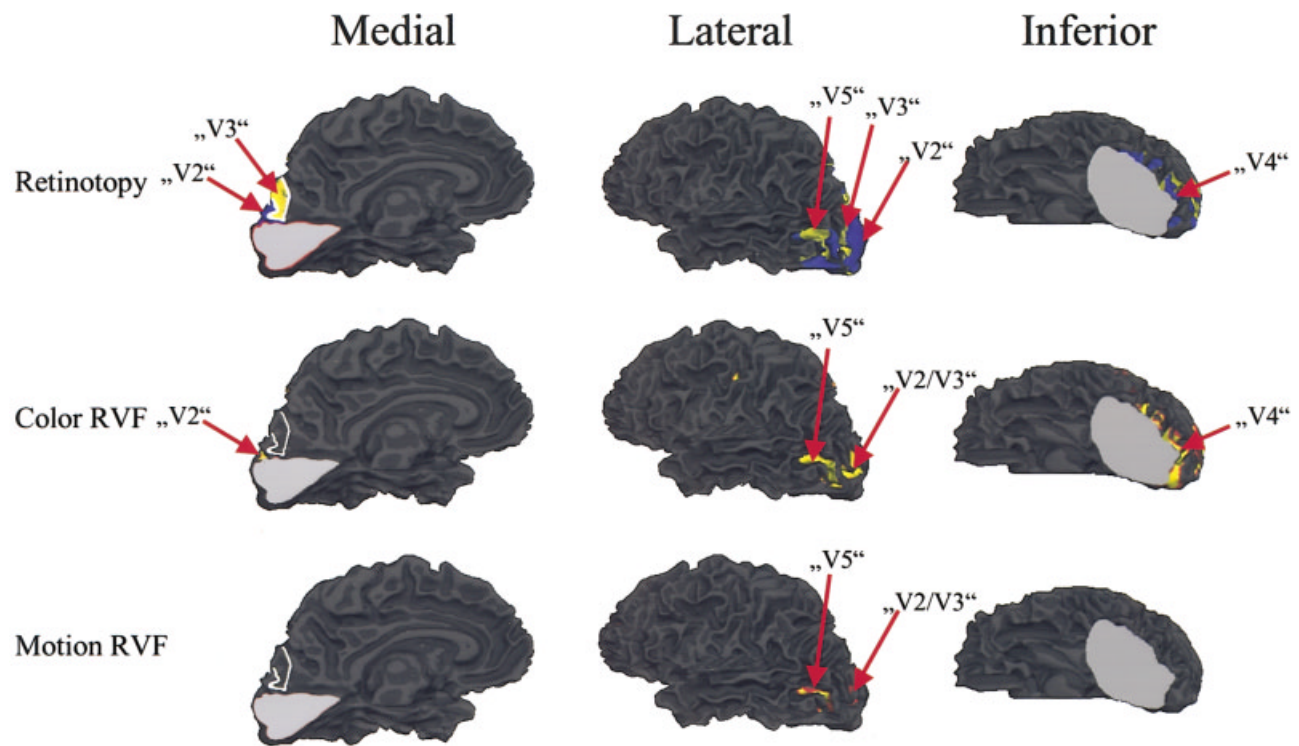


Fig 4. Left hemisphere functional magnetic resonance imaging (fMRI) activity. (top row) Retinotopic mapping of visual areas in the lesioned (left) hemisphere of the patient. The lesion is marked in gray. The arrows indicate putative visual areas. (middle row) Coregistration of the functional magnetic resonance activity elicited by color-change stimuli to the right visual field (RVF) with the borders of the retinotopic areas. (bottom row) Coregistration of the retinotopic areas with the fMRI activity elicited by moving stimuli in the RVF.

ity resulted in a two-dipole model for the M-RVF condition. One dipole was located in the left V2/V3 region and one in the left V5 region following Table 1. In the time range 100 to 210 milliseconds, this model accounted for 85.4% of the variance of the field. As in the unconstrained model, the left V5 dipole accounted for the early part (100–140 milliseconds) of the ERF, whereas the left V2/V3 dipole accounted for the later part (140–210 milliseconds) of the ERF activity. The C-RVF condition was similarly modeled with two dipoles, one located in the V2/V3 region and one in the V4/V8 region, which accounted for 86.6% of the variance of the field in the time range 100 to 200 milliseconds. The V4/V8 dipole accounted for the early part (100–145 milliseconds) and the V2/V3 dipole for the later part (145–200 milliseconds) of the ERF.

Discussion

This study investigated the neural substrates of preserved visual functioning in a subject with homonymous hemianopsia after a posterior cerebral artery stroke. The subject showed limited visual abilities in his affected visual field, which included above-chance detection of movement and color change and discrim-

ination of movement direction. Because these abilities were evident in verbal reports, it is assumed that they were associated with conscious awareness of the stimuli, which characterizes the Riddoch syndrome. By using fMRI, it was shown that motion and color-change stimuli in the hemianopic field produced activation in several extrastriate areas of the lesioned hemisphere that were defined using retinotopic mapping. MEG recordings were used to track the timing of activations in these areas. The major MEG finding using two different modeling approaches was that stimulus-evoked activity occurred earlier in higher-tier visual areas V4/V8 and V5 than in lower-tier areas V2/V3 adjacent to the lesion. In addition, an increased functional connectivity²⁷ was observed between areas V4/V8 and V5 of the lesioned hemisphere in comparison with the connectivity between these areas in the intact hemisphere during the presentation of color changes.

Our fMRI results are in accordance with previous findings of evoked hemodynamic activity in extrastriate areas V4¹² and V5^{3,10} of the hemisphere ipsilateral to the lesioned striate cortex in response to stimulation of the contralateral (blind) visual field. We failed to obtain any evidence for “islands of vision” within the sco-

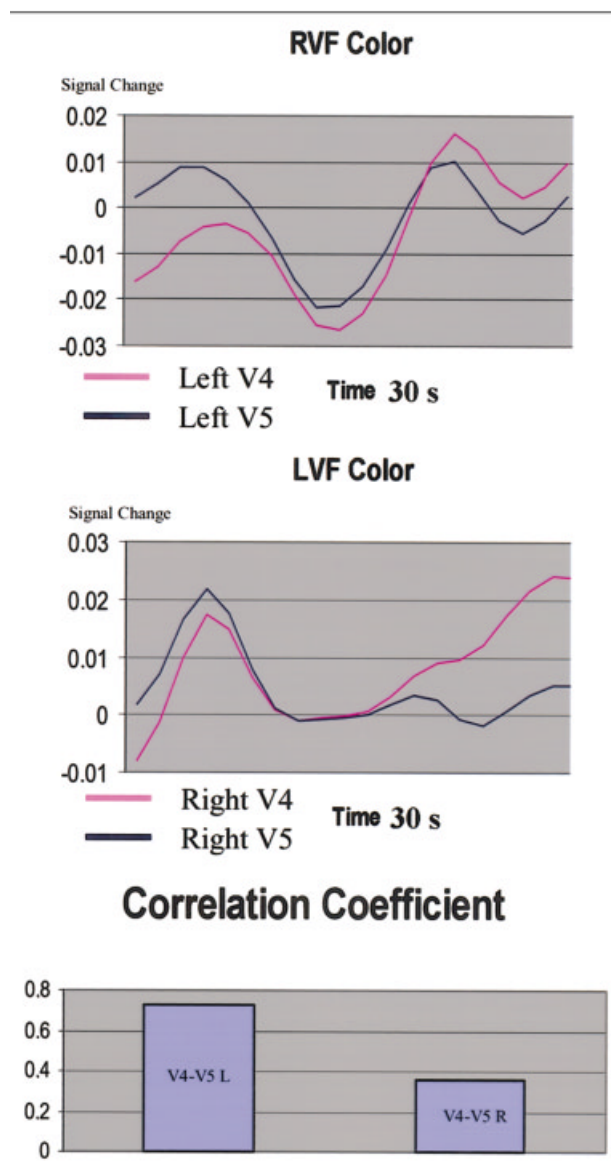


Fig 5. Functional connectivity analysis. Time courses of blood oxygen level dependent signals in V4/V8 (pink traces) and V5 (blue traces) during color stimulation of the “blind” right visual field (RVF; top panel) and to the sighted left visual field (LVF; middle panel). The correlation (bottom panel) between V5 and V4/V8 voxels was higher for the lesioned hemisphere (during color changes presented to the RVF) than for the healthy hemisphere (during color changes presented to the LVF).

toma by using high-resolution perimetry. Because we did not use an image stabilizer as did Fendrich and colleagues,⁶ we cannot completely rule out the possibility of spared islands of V1 tissue within the lesion on the basis of perimetry alone. Moreover, it has been proposed²⁸ that visual input to such “islands” may be unavailable to phenomenal awareness and hence would not be detected by our visual field mapping methods in any case. Nonetheless, our finding of no fMRI activity

in the lesioned V1 region even at low thresholds (also reported by previous studies^{12,29}), together with the MEG results showing that putative areas “V5” and “V4/V8” were activated earlier than areas “V2” and “V3,” weigh against the spared island hypothesis in our Riddoch subject. These results do not rule out the possibility, however, that spared islands might be a contributing factor in other patients exhibiting blindsight.

A second hypothesis³ holds that input to extrastriate regions of the lesioned hemisphere arrives through subcortical connections by way of the superior colliculus and pulvinar and projects mainly to area MT.^{13–15} According to this proposal, we would expect that the V5 region (the presumed human homolog of monkey area MT) would be activated first by an adequate stimulus in a patient with a V1 lesion, with other extrastriate areas being activated later. Our MEG results provide strong support for this hypothesis, in that the earliest activity evoked by the motion stimulus in the blind visual field (at 106–118 milliseconds) was localized to the region of area V5 of the lesioned hemisphere, whereas activity localized to the lower-tier areas V2/V3 began later (185–210 milliseconds). These dipole locations are similar to those recently reported by Rao and colleagues in a study of visual-evoked potentials in blindsight.³⁰ It also was found that the initial MEG activity elicited by color change in the blind field (at 110–130 milliseconds) was localized to the V4/V8/V5 region and preceded activity localized to V2/V3 (at 169–193 milliseconds). Indeed, the dipoles accounting for the early ERF components elicited by color change and by motion were in close spatial proximity to one another (see Table 2) and were similar in orientation. This suggests that motion and color initially may activate common or overlapping neural generators in the V4/V8/V5 region of the lesioned hemisphere. In contrast, with stimulation of the sighted visual field, V1/V2/V3 activity preceded V4/V8/V5 activity in the intact hemisphere.

This evidence for subcortical mediation in human blindsight and Riddoch syndrome is in line with single cell studies in monkeys in which it was shown that, after cooling of V1, MT neurons still fired when stimuli were presented within their receptive fields.¹⁷ Monkeys also may exhibit preserved vision resembling blindsight^{29,31} or Riddoch^{32,33} phenomena after V1 lesions, and a large body of evidence indicates that visual signals mediating these effects reach MT via subcortical pathways through the superior colliculus and the pulvinar.^{15,17,34}

The isoluminance of the color stimuli used in this study was necessarily established in sighted regions of the visual field, which raises the question of whether these stimuli were also isoluminant for the subcortical pathways bypassing V1 in the lesioned hemisphere. In particular, it has been shown that the spectral response

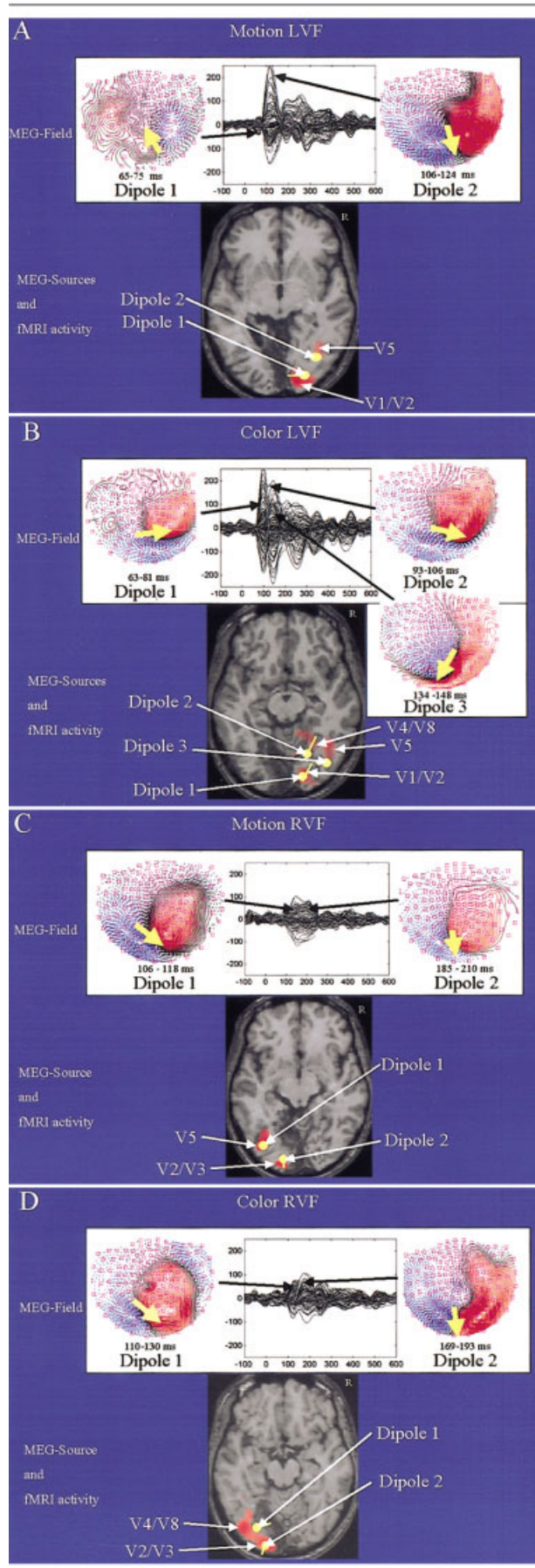


Table 2. Talairach Coordinates of Magnetoencephalographic Sources

Condition	Early (x/y/z)	Late (x/y/z)
M-LVF	17/-84/2	38/-76/-6
M-RVF	-34/-80/-6	-27/-89/2
C-LVF	14/-86/0	28/-64/-6
C-RVF	-32/-70/-6	-28/92/0

M-LVF = motion presented to the left visual field; M-RVF = motion presented to the right visual field; C-LVF = color changes presented to the LVF; C-RVF = color changes presented to the RVF.

characteristics of superior colliculus neurons differ from those in the geniculostriate pathway.³⁵ Accordingly, the detection of color changes and the associated activation of extrastriate areas in the lesioned hemisphere might to some degree have been based on luminance rather than hue information.

Our data provided no support for the proposal that signals from the retina reach the V5 region before reaching V1 via these colliculopulvinar subcortical connections with a latency of approximately 30 milliseconds after stimulus.²¹ Although it is well established that the superior colliculus projects to the inferior pulvinar nucleus and that the latter projects to area MT, it is far from clear whether there is a monosynaptic link in the inferior pulvinar that could underlie a fast route to area MT.³⁶ In the subject's intact hemisphere, the activity localized to V4/V5 occurred subse-

Fig 6. (A) Magnetoencephalographic (MEG) activity elicited by moving bars presented to the left visual field (LVF). The event-related fields (ERFs) are shown as a butterfly plot (all channels superimposed), along with the field distributions and estimated dipolar sources corresponding to the first (dipole 1) and the second (dipole 2) peak. The locations of these sources are coregistered with the functional magnetic resonance imaging (fMRI) activations below. Note that the sequence of activity is V1/V2 to V5. (B) MEG activity elicited by color-change stimuli presented to the LVF. The ERF distributions and the estimated dipolar sources are shown for the first (dipole 1), second (dipole 2), and third (dipole 3) peaks. Note that the sequence of activity is V1/V2 to V4/V8 to V5. (C) MEG activity elicited by moving bars presented to the "blind" right visual field (RVF). The ERF distributions and the estimated dipolar sources are shown for the first (dipole 1) and second (dipole 2) peaks. The locations of these sources are coregistered with the fMRI results below. Note that the peaks are reduced in amplitude in comparison with panel A and that the sequence of activity is V5 to V2/V3. (D) MEG activity elicited by color-changing bars presented to the "blind" RVF. The ERF distributions and the estimated dipolar sources are shown for the first (dipole 1) and second (dipole 2) peaks. Note that the peaks are reduced in amplitude in comparison with panel B and that the sequence of activity is V4/V8/V5 to V2/V3.

quent to the V1/V2 activity, and no significant activity was observed before 90 milliseconds in the subject's left hemisphere with lesioned striate cortex. The time course of V5 activity observed here is in line with the results of other neurophysiological studies.^{37,38}

To investigate how the visual input mediating the Riddoch phenomena was organized in the spared extrastriate cortex, we mapped the borders between the different visual areas in the subject by using fMRI phase-encoding methods. The retinotopic mapping for the intact hemisphere was similar to that obtained from normal subjects.²⁴ The mapping of the lesioned hemisphere showed some preserved retinotopic organization of the remaining visual regions in agreement with previous observations in a Riddoch patient.³⁹ These findings of retinotopic organization in the spared extrastriate cortex in patients with striate lesions imply that their preserved visual functioning does not involve a massive topographical reorganization with a complete loss of borders between the different visual areas. Similar findings recently have been reported in monkeys,³⁴ which demonstrated a retinotopic reorganization in area MT for stimuli within the scotoma caused by a striate lesion.

Another question regarding reorganized visual pathways after primary cortex lesions is whether any change occurs in the connectivity between different extrastriate cortical areas. Using the method suggested by Buchel and Friston,²⁷ we found a considerably higher correlation between the time courses of activity in areas V4/V8 and V5 within the lesioned hemisphere than in the intact hemisphere during the presentation of color changes. This suggests an increase in connectivity between area V4/V8 and V5 due to the reorganization and/or rerouting of visual inputs to the cortex after the striate lesion.

These results indicate that cortical reorganization after a V1 lesion does not involve a complete loss of retinotopic order, but rather a change of connectivity and a change in the dominant direction of flow of visual information between the visual areas spared by the lesion. Normally the visual input to extrastriate cortex is dominated by the major feedforward projections from area V1. After V1 lesions, however, the cortical area with the most robust visual input is likely to be V5, because it receives the most abundant subcortical connections from the colliculopulvinar pathway. It appears then that following V1 lesions, area V5 assumes the central role in distributing the subcortical visual signals to other extrastriate regions via feedback and feedforward connections that are largely already in place.⁴⁰ The spatiotemporal activation patterns observed in this study provide support for the central role of the V5 region in mediating the preserved visual functions seen in Riddoch syndrome after V1 lesions.

References

1. Weiskrantz L, Warrington EK, Sanders MD, Marshall J. Visual capacity in the hemianopic field following a restricted occipital ablation. *Brain* 1974;97:709–728.
2. Riddoch G. Dissociation of visual perceptions due to occipital injuries, with especial reference to appreciation of movement. *Brain* 1917;40:15–57.
3. Zeki S, Ffytche DH. The Riddoch syndrome: insights into the neurobiology of conscious vision. *Brain* 1998;121:25–45.
4. Azzopardi P, Cowey A. Why is blindsight blind? In: de Gelder B, ed. *Out of mind*. New York, Oxford University Press, 2001.
5. Barton JJ, Sharpe JA. Motion direction discrimination in blind hemifields. *Ann Neurol* 1997;41:255–264.
6. Fendrich R, Wessinger CM, Gazzaniga MS. Residual vision in a scotoma: implications for blindsight. *Science* 1992;258:1489–1491.
7. Kaas JH, Krubitzer LA. Area 17 lesions deactivate area MT in owl monkeys. *Vis Neurosci* 1992;9:399–407.
8. Scharli H, Harman AM, Hogben JH. Blindsight in subjects with homonymous visual field defects. *J Cogn Neurosci* 1999;11:52–66.
9. Kentridge RW, Heywood CA, Weiskrantz L. Residual vision in multiple retinal locations within a scotoma: implications for blindsight. *J Cogn Neurosci* 1997;9:191–202.
10. Barbur JL, Watson JD, Frackowiak RS, Zeki S. Conscious visual perception without V1. *brain* 1993;116:1293–1302.
11. Sahraie A, Weiskrantz L, Barbur JL, et al. Pattern of neuronal activity associated with conscious and unconscious processing of visual signals. *Proc Natl Acad Sci USA* 1997;94:9406–9411.
12. Goebel R, Muckli L, Zanella FE, et al. Sustained extrastriate cortical activation without visual awareness revealed by fMRI studies of hemianopic patients. *Vis Res* 2001;41:1459–1474.
13. Yukie M, Iwai E. Direct projection from the dorsal lateral geniculate nucleus to the prestriate cortex in macaque monkeys. *J Comp Neurol* 1981;201:81–97.
14. Cowey A, Stoerig P, Bannister M. Retinal ganglion cells labelled from the pulvinar nucleus in macaque monkeys. *Neuroscience* 1994;61:691–705.
15. Standage GP, Benevento LA. The organization of connections between the pulvinar and visual area MT in the macaque monkey. *Brain Res* 1983;262:288–294.
16. Girard P, Salin PA, Bullier J. Response selectivity of neurons in area MT of the macaque monkey during reversible inactivation of area V1. *J Neurophysiol* 1992;67:1437–1446.
17. Rodman HR, Gross CG, Albright TD. Afferent basis of visual response properties in area MT of the macaque. II. Effects of superior colliculus removal. *J Neurosci* 1990;10:1154–1164.
18. Rodman HR, Gross CG, Albright TD. Afferent basis of visual response properties in area MT of the macaque. I. Effects of striate cortex removal. *J Neurosci* 1989;9:2033–2050.
19. Dineen J, Hendrickson A, Keating EG. Alterations of retinal inputs following striate cortex removal in adult monkey. *Exp Brain Res* 1982;47:446–456.
20. Cowey A, Stoerig P, Williams C. Variance in transneuronal retrograde ganglion cell degeneration in monkeys after removal of striate cortex: effects of size of the cortical lesion. *Vision Res* 1999;39:3642–3652.
21. Ffytche DH, Guy CN, Zeki S. The parallel visual motion inputs into areas V1 and V5 of human cerebral cortex. *Brain* 1995;118:1375–1394.
22. Salin PA, Girard P, Bullier J. Visuotopic organization of corticocortical connections in the visual system. *Prog Brain Res* 1993;95:169–178.
23. Sereno MI, Dale AM, Reppas JB, et al. Borders of multiple visual areas in humans revealed by functional magnetic resonance imaging. *Science* 1993;268:889–893.

24. Tootell RB, Reppas JB, Dale AM, et al. Visual motion aftereffect in human cortical area MT revealed by functional magnetic resonance imaging. *Nature* 1995;375:139–141.
25. Faubert J, Diaconu V, Ptito M, Ptito A. Residual vision in the blind field of hemidecorticated humans predicted by a diffusion scatter model and selective spectral absorption of the human eye. *Vis Res* 1999;39:149–157.
26. Barton JJ. Higher cortical visual function. *Curr Opin Ophthalmol* 1998;9:40–45.
27. Buchel C, Friston KJ. Modulation of connectivity in visual pathways by attention: cortical interactions evaluated with structural equation modelling and fMRI. *Cereb Cortex* 1997;7:768–778.
28. Fendrich R, Wessinger CM, Gazzaniga MS. Speculations on the neural basis of islands of blindsight. *Prog Brain Res* 2001;134:353–366.
29. Stoerig P, Cowey A. Blindsight in man and monkey. *Brain* 1997;120:535–559.
30. Rao A, Nobre AC, Cowey A. Disruption of visual evoked potentials following a V1 lesion: implications for blindsight. In: de Gelder B, ed. *Out of mind*. New York, Oxford University Press, 2001.
31. Moore T, Rodman HR, Repp AB, Gross CG. Localization of visual stimuli after striate cortex damage in monkeys: parallels with human blindsight. *Proc Natl Acad Sci USA* 1995;92:8215–8218.
32. Moore T, Rodman HR, Gross CG. Direction of motion discrimination after early lesions of striate cortex (V1) of the macaque monkey. *Proc Natl Acad Sci USA* 2001;98:325–330.
33. Ffytche DH, Guy CN, Zeki S. Motion specific responses from a blind hemifield. *Brain* 1996;119:1971–1982.
34. Rosa MG, Tweeddale R, Elston GN. Visual responses of neurons in the middle temporal area of new world monkeys after lesions of striate cortex. *J Neurosci* 2000;20:5552–5563.
35. Schiller PH, Malpeli JG. Properties and tectal projections of monkey retinal ganglion cells. *J Neurophysiol* 1977;40:428–445.
36. Stepniewska I, Qi HX, Kaas JH. Projections of the superior colliculus to subdivisions of the inferior pulvinar in new world and old world monkeys. *Vis Neurosci* 2000;17:529–549.
37. Anderson SJ, Holliday IE, Singh KD, Harding GF. Localization and functional analysis of human cortical area V5 using magneto-encephalography. *Proc R Soc Lond B Biol Sci* 1996;263:423–431.
38. Schoenfeld MA, Heinze H-J, Woldorff MG. Unmasking motion-processing activity in human brain area V5/HMT+ mediated by pathways that bypass primary visual cortex. *Neuroimage* (in press).
39. Baseler HA, Morland AB, Wandell BA. Topographic organization of human visual areas in the absence of input from primary cortex. *J Neurosci* 1999;19:2619–2627.
40. Hupe JM, James AC, Payne BR, et al. Cortical feedback improves discrimination between figure and background by V1, V2 and V3 neurons. *Nature* 1998;394:784–787.